

The antegrade reperfusion test avoids the risk of mitral regurgitation recurrence optimizing valve repair

Amir Youssari^{1,†}, Jean-Paul Couetil^{2,†}, Mariantonietta Piscitelli², Céline Zerbib³, Ophélie Brault-Meslin³, Sanjeet Singh Avtaar Singh⁴, Francesco Nappi^{5,*}, Antonio Fiore²

¹Department of Cardiovascular Surgery, Jacques Cartier Hospital, 91300 Massy, France

²Departement of Cardiac Surgery, Henri Mondor University Hospital, University of Paris-Est Creteil, 94000 Creteil, France

³Departement of Cardiology, Henri Mondor University Hospital, University of Paris-Est Creteil, 94000 Creteil, France

⁴Department of Cardiothoracic Surgery, Golden Jubilee National Hospital, G81 4DY Clydebank, Glasgow, UK

⁵Department of Cardiac Surgery, Centre Cardiologique du Nord, Saint-Denis, 93200 Paris, France

*Correspondence: francesconappi2@gmail.com (Francesco Nappi)

† These authors contributed equally.

DOI:10.31083/j.rcm2203102

This is an open access article under the CC BY 4.0 license (<https://creativecommons.org/licenses/by/4.0/>).

Submitted: 28 May 2021 Revised: 1 July 2021 Accepted: 9 July 2021 Published: 24 September 2021

Saline injection into the left ventricle through mitral valve (saline test) is the most commonly used intraoperative assessment method in mitral valve repair. However, potential discrepancies between the saline test findings and intraoperative transesophageal echocardiography results after the weaning of cardiopulmonary by-pass, remain significant. Here, we describe a new antegrade reperfusion test, reproducing intraoperatively, the physiologic conditions of loaded and beating heart for direct transatrial evaluation of valve tightness. The proposed test is performed by perfusing warm oxygenated blood into the aortic root under cross-clamping. From February 2016 to December 2018, 91 patients (mean age: 63 ± 11 years) underwent mitral valve repair for mitral regurgitation. In all of them, the classic saline test was completed with the newly proposed antegrade test. We report our results with this combined approach. Data were obtained from the medical records and our mitral valve repair database. In 32 (35.1%) patients, evident or undetectable minor regurgitation at the saline test were respectively unconfirmed or detected by the antegrade reperfusion test leading to their complete correction. In only three patients (3.2%) major discrepancies were present between the intraoperative evaluation and the post-pump transesophageal echocardiography. Two of them (2.1%) required a second cardiopulmonary bypass run to fix the residual regurgitation. The antegrade reperfusion test is a simple dynamic intraoperative approach mimicking the physiological conditions of ventricular systole for mitral valve repair evaluation. Combined with the classic saline test, it seems to be a valuable additional intraoperative tool, enabling a more predictable repair result.

Keywords

Mitral valve repair; Saline test; Intraoperative evaluation; Beating heart test; Antegrade reperfusion

1. Introduction

Mitral valve repair (MVR) is favored to valve replacement, and today an approach to “respect” with use of neo-chordae rather than resect mitral leaflet tissue is preferred.

Optimizing mitral valve repair ensures the longevity of its results [1–7]. Perioperative transesophageal echocardiography (TEE) with use of 3D in combination with 2D is essential for successful mitral repair and postoperative monitoring. The saline test (ST) is also an important step and is the most commonly used intraoperative method of mitral valve repair evaluation [8]. However, on the arrested heart and in absence of tension of the subvalvular apparatus, an inefficient and incomplete evaluation is possible. In several studies, a rate of 6–8%, between a visually satisfactory ST and post-pump intraoperative transesophageal echocardiography (PP-TEE) result, is reported [9–12]. The aim of this study is to reduce the incidence of these discrepancies using the antegrade reperfusion (AR) test as a dynamic approach, thus providing a reliable intraoperative assessment model very close to the real ventricular systolic load conditions. This procedure has never been reported before. First, the use of AR combined with the ST test allows to detect the potential residual regurgitation that the ST test alone (Fig. 1) does not show. The result is improved vigilance and optimization of valve repair. Second, we investigated the benefits associated with the use of the AR test due to a marked reduction in the percentage of patients with a false negative conventional saline test result, requiring a new surgical procedure for unsatisfactory mitral valve repair. Third, we have reduced the potentially harmful consequences of long duration of cardiopulmonary bypass (CPB) and additional aortic cross-clamping time can be avoided [13].

We believe that the data reported herewith could provide a basis for the further assessment of this new combined procedure and could assist cardiologist-cardiac surgeon discussions about the benefits and expectations after the AR test.

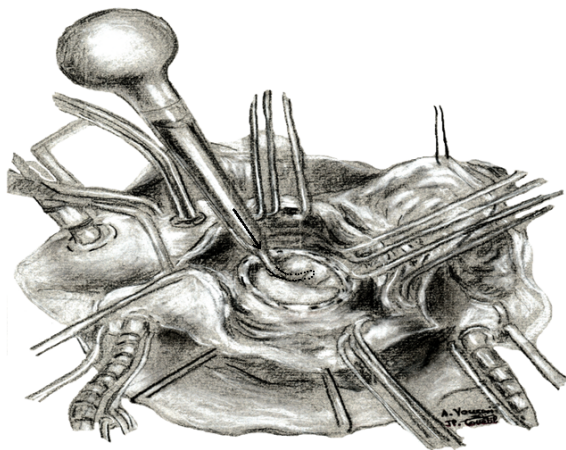


Fig. 1. Classic saline injection test using a bulb syringe (black arrows) with non-physiologic static conditions of the left ventricle on arrest, without tensioning of the mitral valve apparatus. With the immediate intraoperative test by perfusing warm and oxygenated blood into the aortic root we evaluated the response property of the mitral valve after repair. The most important evidence that emerged from the analysis of MV morphology induced by the AR test suggested that the mitral valve after repair bulged in the left atrium taking the shape of a balloon, while the anterior leaflet of the repaired valve remained in the left ventricle. In this context the mechanism of a residual leak may be detectable avoiding immediate postoperative regurgitation.

2. Patients and methods

2.1 Study population and operative data

The study database includes data on five hundred ninety-eight mitral valve repairs since February 2010 and was frozen in December 2018. For the present report, all events between February 2016 and December 31, 2018 were analyzed. Baseline and follow-up data were analyzed for 91 patients (who were included in the database) where we performed a saline test coupled with an anterograde reperfusion test. All patients had intraoperative PP-TEE and seventy-four of them recorded a severe mitral regurgitation on preoperative echocardiography. All subjects gave their informed consent for inclusion in the study and the authors had complete access and take full responsibility for the entirety of the data and the current article. The study conforms to the Declaration of Helsinki and was not supported by any external source of funding.

2.2 Operative technique

The AR test is performed by perfusing warm oxygenated blood into the aortic root under aortic cross-clamping, aims to reproduce physiological conditions close to those of ventricular systole, strengthening the intraoperative detection of possible residual leaks and allowing correction before the left atrium is closed.

All patients underwent MVR with median sternotomy and CPB established with ascending aorta and bicaval cannulation. Myocardial protection was ensured by perfusion of cold hyperkalemic CPK-MB cardioplegia or Bretschneider

histidine-tryptophan-ketoglutarate (HTK) crystalloid solution (CUSTODIOL; Koehler Chemi, AlsbachHaenlien, Germany) through the double-flow (perfusion-suction) antegrade perfusion line. The suction branch is connected to a pressure line during the antegrade reperfusion to monitor the pressure.

Once the repair is completed, warm oxygenated blood derived from the arterial line of CPB is injected under pressure into the ascending aorta through the cardioplegia double-flow needle (Fig. 2) which leads to cardiac activity resumption. The reproduced conditions are almost similar to those of the isovolumetric phase of cardiac contraction. Simultaneously the left ventricle (LV) is filled with blood collected in the pericardium using a bulb syringe after removing the atrial retractor, thus obtaining the tensioning of the entire mitral valvular apparatus elements. A shortening of the transverse annular diameter reducing the intercommissural width is observed intraoperatively. Moreover, the mitral leaflets appeared to bulge more and the coaptation area appeared wider than on an arrested and flaccid heart [8], offering a physiologically faithful intraoperative evaluation model to real conditions of ventricular load and contractility.

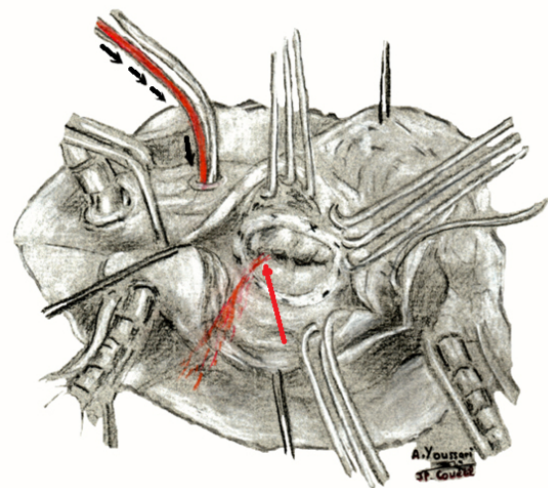


Fig. 2. Antegrade perfusion cannula is inserted into the ascending aorta (little black arrows). The beating heart is re-established spontaneously. A minor leak from the commissural side (red arrow) could be clearly detected during AR test.

2.3 Statistical analysis

Continuous variables were expressed as the mean \pm standard deviation. Categorical variables were presented as medians and interquartile ranges or as the number of patients as a percentage of the sample. The statistical analysis was performed using the SPSS 21 (SPSS, Inc, Chicago, IL, USA).

3. Results

3.1 Study population

Patients, characteristics, and operative data are listed in Table 1.

Table 1. Patient characteristics.

Demographics	
-Age mean (year, range)	63 (19–88)
-Male (n°)	39 (42%)
-Female (n°)	52 (58%)
Leaflet involvement (n°)	
-Isolated posterior	39 (42.8%)
-Isolated anterior	28 (30.7%)
-Bileaflet	24 (26.3%)
-Restriction	13 (14.2%)
Leak mechanism (n°)	
-Prolapse	54 (59.3%)
-Restriction	13 (14.2%)
-(Prolapse + restriction) and others	24 (26.3%)
Cardiac co morbidity	
-LVEF (%)	55 ± 10
-LVEF [20–50] (n°)	29 (31.8%)
-LVEF >50 (n°)	62 (68.2%)
-Myxoid degeneration (Barlow) (n°)	16 (17.5%)
-Atrioventricular canal (n°)	1 (1.0%)
-Previous sternotomy (n°)	7 (7.6%)
-Atrial fibrillation (n°)	34 (37.3%)
-Coronary artery disease (n°)	10 (10.9%)
-Endocarditis (n°)	9 (9.8%)
-Papillary muscle rupture	2 (2.1%)

LVEF, left ventricular ejection fraction.

3.2 Intraoperative course

MVR was successfully completed in all patients. Standard reconstructive techniques were performed, in most cases along using the PTFE neochords. In 7 patients (7.6%) undergoing MVR for mitral regurgitation (MR) related to infective endocarditis and according to our institutional policy of not inserting prosthetic material in an adjacent septic environment, no prosthetic ring was implanted. Thirty-six (39.5%) procedures were associated with MVR. Mean CPB time and mean aortic cross-clamping time was 101 min (61–173 min) and 82 min (47–141 min) respectively. PP-TEE revealed the absence of residual regurgitation in 82 patients (91.2%) corroborating the result of the AR test. Intraoperative data are described in Table 2.

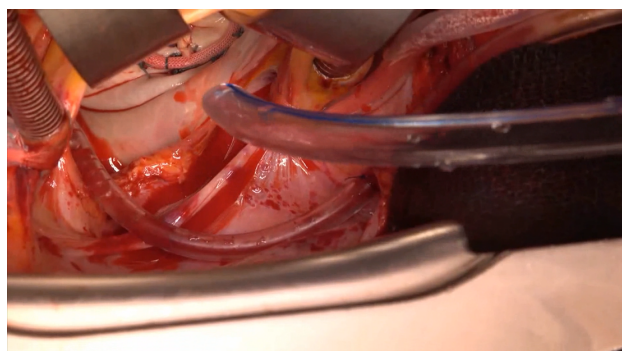
3.3 The beating heart test

AR test was contributive in 32 of 91 patients (35.1%) revealing either residual regurgitations after a satisfactory ST test, or by refuting the regurgitations appearing on the ST test. Based on these findings, the repair was optimized as needed. In twenty-seven patients (29.6%), residual regurgitation not seen at the ST test were detected by the AR test which allowed to the precise location of mitral regurgitation and their exact mechanism (Videos 1,2). In two other cases,

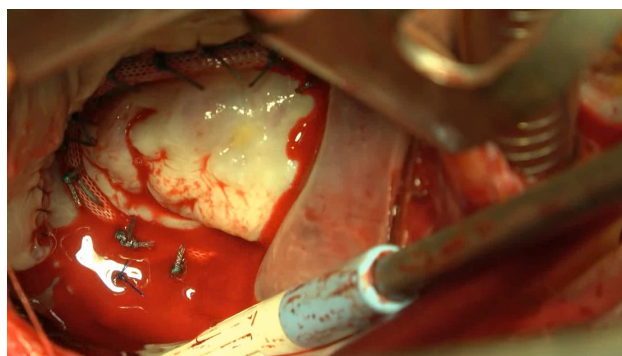
Table 2. Operative details.

Reconstructive techniques	
-PL height adjusting neochords (n°)	49 (53.8%)
-AL height adjusting neochords (n°)	23 (25.2%)
-Scallop closure (n°)	18 (19.7%)
-Cleft closure (n°)	1 (1.0%)
-PL quadrangular resection (n°)	12 (13.1%)
-Commissuroplasty (n°)	13 (14.2%)
-Annular plication (n°)	4 (4.3%)
-Prosthetic ring (n°)	84 (92.3%)
Concomitant procedures (n°)	
-AF ablation therapy	7 (7.6%)
-Tricuspid repair	13 (14.2%)
-CABG	9 (9.8%)
-Ostium primum closure (partial AVSD)	1 (1.0%)
-Associated concomitant procedures (n°)	6 (6.5%)
-CPB time (min, IQR)	101 (61–173)
-Aortic cross clamp time (min, IQR)	82 (47–141)

AL, anterior leaflet; PL, posterior leaflet; AF, atrial fibrillation; CABG, coronary artery bypasses grafting; CPB, cardiopulmonary bypass; IQR, interquartile range.



Video 1. AR test showing a posterior commissural residual MR after a satisfactory saline test (ST) test. Movie may be viewed at <https://rcm.imrpress.com/EN/10.31083/j.rcm2203102>.



Video 2. AR revealing the exact location and mechanism of a massive residual MR by A2-A3 prolapse after a satisfactory ST test. Movie may be viewed at <https://rcm.imrpress.com/EN/10.31083/j.rcm2203102>.

a residual regurgitation, was confirmed by the AR test and defined exact mechanism. In these twenty-nine patients, the additional reparative procedures included were summarized in Table 3.

Table 3. Operative details during Warm AR Test.

-Additional procedures (n°)	In 29 patients of 91 (31.8%)
-Scallop closure (n°)	7 (24.1%)
-Leaflet height adjustment (neochords) (n°)	6 (20.6%)
-Commisuroplasty (n°)	9 (31%)
-Associated additional procedures (n°)	7 (24.1%)
-Interval time (min, IQR)	4.3 (2–7)
-Beating time (min, IQR)	3.1 (1–5)
-Perfusion flow (mL/min)	268 (210–320)

In three cases, the ST test showed a regurgitation not observed at the AR test in favor of a perfectly tight valve with the change of the left ventricular loading conditions, avoiding unnecessary additional corrective procedures potentially compromising the initial repair. In these patients, the PP-TEE corroborated the AR test findings.

The results were confirmed by intraoperative transesophageal echocardiography after the weaning of cardiopulmonary by-pass.

The mean antegrade reperfusion flow was 268 ± 27 mL/min. The mean time-lapse required between the start of antegrade reperfusion and the appearance of the first contractions was 4.3 ± 1.3 min. The mean time between the first contractions and the moment when the evaluation was achieved was 3.1 ± 1.0 min. No discrepancies between the AR test and the PP-TEE were found in the 32 patients. PP-TEE failed to reveal any mitral stenosis in all the patients requiring a repair revision.

The details of the AR test are shown in Table 4. In four patients the PP-TEE revealed a residual MR that wasn't noticed at the AR test but was suspected during ST. In one case the residual regurgitation was trivial and was respected. In one case a grade II residual regurgitation was left because of age of patient and unfavorable anatomy (calcifications of the native valvular annulus). In the two other patient a second run of CPB was necessary, and the residual prolapse was fixed using a neochord with a perfect result at the second AR test and the PP-TEE.

3.4 Postoperative patient outcome

The 30-day survival rate was 100%. No air embolism was experienced. Almost all patients ($n = 86$; 94.5%) were free from major complications. Two right ventricular (RV) failures occurred in our series, requiring both a venoarterial extracorporeal membrane oxygenation (VA-ECMO), successfully weaned after total ventricular function recovery on day 2 (D2) and day 3 (D3) respectively. Two patients were re-explored for bleeding, none of them had myocardial reperussions.

In two cases the repair resulted in a systolic anterior motion (SAM). In one, it was concerning an undersized complete prosthetic ring and was solved by its replacement with a larger open ring. In the second case, the SAM appeared on the 2nd postoperative D2 concomitantly with a high-rate arrhythmia and was solved after adequate medical treatment of the arrhythmia. At predischARGE transthoracic echocardiography, 83 (91.2%) patients had no regurgitation, seven (7.6%) patients had trivial regurgitation and only one (1%) patient, had a grade 2 regurgitation. The detailed surgical outcomes are reported in Table 5.

4. Discussion

The major finding of this study was to replicate the biomechanical adaptation of the mitral apparatus after repair through the AR test. The results reported here assist to better our understanding of the features of the mitral valve before and immediately after the repair. With the AR test the mitral valve leaflets, the chordae tendinae, and the papillary muscles were tested mechanically by uniaxial cyclic extension test under quasi-static conditions. The AR test reproduces the feature of the mitral valve that is closed with maximum pressure inside the ventricle that reaches 120 mmHg during the isovolumetric LV systolic phase. At this value of compression, the ventricular ejection systole is effective.

It should be noted that the trans-mitral pressure gradient is higher than the transaortic gradient for the low-pressure arises in the left atrium. During ventricular isovolumetric systole when, according to Frank-Starling's law, the ventricular myocardial fibers must stretch to ensure adequate LVEDD, a certain degree of stress is already exerted on the leaflets and papillary muscles that are embedded in the ventricles. However, the AR test did not reproduce the entire systolic ventricular cycle. The left ventricle is geometrically comparable to a cylinder. During the end of the isovolumetric systole and the immediate ventricular ejection to guarantee the thrust of the blood out of the ventricle, the upper base of the LV chamber moves towards the lower base rotating around the interventricular septum. At this stage, the left fibrous trigone of the heart is subjected to high mechanical stress. The aortic valve and the mitral valve are in close contact at the level of the left trigone so that the anterior commissure of the mitral valve is affected by mechanical modifications in a significant way leading to a wrinkle-induced tear in the mitral valve leaflet tissue [14].

In detail, the data obtained in the immediate intraoperative test and the related parameters recorded by perfusing warm and oxygenated blood into the aortic root were used to evaluate the response property of the mitral valve after repair during isovolumetric systole. However, the most important data that emerges from the analysis of the isovolumetric systole induced by the AR test suggests that the mitral valve after repair bulged in the left atrium taking the shape of a balloon, while the anterior leaflet of the repaired valve remained in the left ventricle. In this context the mechanism of a resid-

Table 4. Comparative results between intraoperative (ST/AR test) and PP-TEE findings.

	ST	AR-beat-test	PP-TEE	N°/91
Concordance/discordance (AR test/ST)				
	(-)	(+) add-P	(-)	27 (29.6%)
	(+)	(+) add-P	(-)	2 (2.2%)
	(+)	(-)	(-)	3 (3.2%)
Discordance (AR test/PP-TEE)				
	(±)	(-)	(+)	4 (4.3%)
Concordance (AR test/PP-TEE)				
	(+)	(+) add-P	(+) trivial	5 (5.4%)
	(-)	(-)	(-)	50 (54.9%)

ST, saline test; AR test, antegrade reperfusion test; PP-TEE, post-pump transesophageal echocardiography; (-), no residual regurgitation; (+), Residual regurgitation; (±), suspected residual regurgitation; Add-P, additional procedures.

Table 5. Operative outcome.

In-hospital Deaths (n°)	0 (0%)
Morbidity	
-Stroke (n°)	0 (0%)
-Perioperative myocardial infarction	0 (0%)
-L.V. Failure (n°)	0 (0%)
-RV. Failure (n°)	2 (2.1%)
-Systolic anterior motion (n°)	2 (2.1%)
-Re-exploration for bleeding (n°)	2 (2.1%)
-Renal failure (n°)	0 (0%)
-Sternal wound infection (n°)	1 (1%)
Pre-discharge TTEE	
-Any regurgitation (n°)	83 (91.2%)
-Trivial regurgitation (n°)	7 (7.7%)
-Grade II regurgitation (n°)	1 (1.1%)

ual leak may be detectable avoiding immediate postoperative regurgitation [15].

In the AR test, the recorded intraventricular pressure, measured through the aspiration branch of the cardioplegic line, was between 60 and 80 mmHg in line with the values of 70 and 90 mmHg reported by Tachibana *et al.* [11, 12]. These pressure values are estimated to be effective enough to determine a proper tension of the mitral valve structures and thus can give a reliable result of the repair [14]. In addition, an antegrade reperfusion flow of 300–350 mL/minute is used in our practice. Such flow could generate an intracoronary pressure of 60–65 mm Hg [16]. Our interval time was shorter than that of our colleagues Tachibana *et al.* [12] 3.1 min versus 8.1 min respectively [1–5, 12, 16]. This result could be explained by the higher intra-coronary flow and the more physiological diffusibility of the antegrade reperfusion pathway

However, our shorter mean beating time (3.1 min) than that reported in the Tachibana's study (4.6 min), may be related to the fact that we were performing the evaluation without waiting for complete ventricular defibrillation. The first isovolumetric contractions are enough in our point of view, with a filled ventricle to put the entire valvular apparatus under tension and thus allow a precise evaluation of possi-

ble residual regurgitations. Moreover, based on our shorter test duration, it seems quite reasonable to assume that there would be no more myocardial damage due to poor myocardial protection than what has been reported by Tashibana *et al.* with a longer beating time and a retrograde reperfusion approach [12].

Besides, in the experimental study of Nonaka *et al.* [8], the distance between the papillary tips and the mitral annular plane remained constant in both SI test and the beating heart respectively. There were, therefore, no significant differences in chords length between the two tests.

In our practice, the AR test was a determinant of the precise adjustment of the artificial chord length when required. By tensioning the subvalvular apparatus, it allowed correcting either hyper restriction by excessive neochords traction on the free valvular edge or inversely, a residual prolapse by insufficient traction. Furthermore, P2 bulging, observed during the test in all patients once ventricle loaded and contracting [8] induced in our practice meant we trended towards a slight hyper restrictive approach on the neochords for all P2 prolapses to obtain an optimal height at the time we perform the test. This difference in findings may be due to the fact that the experimental model of Nonaka *et al.* [8] was canine and that the hearts studied were non-pathological.

Moreover, in 28 (87.5%) of the 32 cases where the AR test was decisive, the leak was due to bi-leaflet lesions in six cases (21.4%), to commissural lesions in thirteen (46.4%), and both the two lesions, in nine (32.2%) cases. These results highlight the precious contribution of the test for complex valve lesions.

We also raised the problem of over or under-estimation of residual leaks by the AR test. Conducting a study consisting of not repairing residual regurgitation revealed by the test and settling for a simple PP-TEE check to verify their possible exaggeration by the latter, would pose a real ethical dilemma. Otherwise, there were 88 patients with no residual MR or with trivial leaks for which no discrepancy between the AR test and the PP-TEE resulted necessitating a second pump was noted. We, therefore, do not believe that our approach leads to underestimation. Two patients had a residual grade

II MR at PP-TEE despite a satisfactory antegrade test. This could be related to the fact that the reproduced conditions correspond more to an isovolumetric contractions phase and could, therefore, be different from that of real ventricular systole. A dynamic residual regurgitation may still be transiently present by SAM, obstructing the LV outflow tract.

Another point to ponder is the ventricular filling. The concept of creating an iatrogenic aortic regurgitation by keeping the atrial retractor in place during the test to keep the aortic valve open allowing a quick left ventricular filling has been discussed but never used because of the risk of acute ventricular dilatation. For this reason, we choose the soft filling approach by the progressive injection of (60 to 120 mL) of blood collected in the pericardium through the mitral orifice using a bulb syringe.

A check using both, ST test and AR test is carried out, before the implantation of the prosthetic ring facilitating the correction of potential commissural and sub-valvular lesions. A second check is preferable once the latter is in place which is also recommended by our colleagues Tachibana *et al.* [12] with the retrograde approach.

In case of satisfactory repair, the warm antegrade reperfusion will have allowed free radicals elimination as well as reconstruction of adenosine triphosphate by myocytes before the aortic de-clamping, which seems to improve the post-CPB LV systolic function [17–23]. A cardioplegic reinjection is necessary when a complementary repair or valve replacement is needed.

Evidence suggests the AR test is easy to manage and reproducible, leading to the detection of residual regurgitations that may be not highlighted with static ST. The exact location and mechanism of MR recurrence permit optimization of the valve repair.

Another point in favor of using the AR test is its simple and safe additional intraoperative assessment method in countries where valve repair surgery is preferable to replacement, with regards to the younger patient population and those with limited access to PP-TEE.

Although the retrograde heart test is another viable option [11, 12], the AR test is easier to implement and safer. In fact, the concerns related to the potential risk of iatrogenic damage of the coronary sinus for the retrograde approach are not negligible in dystrophic tissues. Since the AR test uses the common platform of cardiac surgery, no additional equipment is required, thus combining a fast maneuver with the use of a physiological reperfusion approach.

The AR test is performed in a condition of isovolumetric contraction and with cross clamped aorta to avoid any intraoperative embolic incidents.

5. Limitations and future direction

Some likely limitations may burden the study. The accentuated geometric distortion of the left ventricle in patients who received a restrictive mitral annuloplasty can render the AR test ineffective. In severe deformation of left ventricu-

lar chambers recorded with measures of LVESD >50 mm, LVEDD >60 mm, and tenting eight >8 mm, the persistent tethering of P3 scallop and P2/P3 scallop junction without recovery of interpapillary muscle distance, may drastically limit the results of AR maneuver [25–30].

The concern related to the ineffectiveness of AR test is extended to the presence of SAM that is not detected during the maneuver as well as patients with aortic regurgitation who should not be considered for testing [31]. Although we did not highlight myocardial damage issue related to coronary reperfusion in beating heart condition with the use of AR test; however, this concern must be considered as a pitfall.

Finally, we believe that a more complete investigation is advised with a study enrolment that includes two compared patients population. The precise evaluation of intraventricular pressure and biomechanical modeling simulation using the finite element analysis study may be useful for the evaluation of AR test during the systolic phase of ventricular ejection [25–30].

6. Conclusions

Mitral valve repair is the preferred treatment of mitral regurgitation in modern cardiac surgery with better results when compared to valve replacement; hence, intraoperative evaluation of the repair under the most physiological conditions possible before closing the left atrium and weaning the CPB is essential. The results of using the AR test in the intraoperative MVR assessment appear to be satisfactory, with a high degree of concordance between its findings and those of the PP-TEE was found. Its usage for assessing repair integrity after the saline injection test significantly reduces the rate of existing discrepancies between the intraoperative naked eye assessment results and those of the PP-TEE, leading to a safe and more optimized valve repair. Nevertheless, further studies on larger patient samples with this new approach are needed to consolidate our results.

Author contributions

AY, JPC and AF designed the research study; AY, JPC and AF performed the research; AY, MP, CZ, and OM collected the data; FN, AF and MP provided help and advice on the methodology; AY, JPC, AF and FN analyzed the data; CZ and OM ensured the cardiological evaluation and follow-up of patients; AY, JPC, AF and FN wrote the paper; SSAS contributed to improving the English level of the manuscript; AY, FN, AF, JPC and SSAS contributed to editorial changes in the manuscript; All authors read and approved the final manuscript.

Ethics approval and consent to participate

All subjects gave their informed consent for inclusion before they participated in the study. The study was conducted in accordance with the Declaration of Helsinki, and the pro-

tocol was approved by the Ethics Committee. This study is a retrospective cohort study. It did not require the number of Ethics Committee (category 3 of the loi Jardé) It is subjected to CNIL authorization for data processing since January 19, 2017 (Autorisation n°: 1980120) (IRB: 00011591)

Acknowledgment

We gratefully acknowledge Dr. Arnaud Farge, Dr. Mauro Romano, Dr. Mohammad Oroudji, Dr. Taibi Soumia and Zoe Robinson for their precious assistance in the preparation of this manuscript. We particularly thank DR Francesco Nappi for his valuable contribution in the preparation and writing of this manuscript. We also wish to thank Eric Escande for the video illustrations.

Funding

This research received no external funding.

Conflict of interest

The authors declare no conflict of interest.

References

- [1] Carpentier A. Cardiac valve surgery—the “French correction”. *Journal of Thoracic and Cardiovascular Surgery*. 1983; 86: 323–337.
- [2] Antunes MJ. Mitral valve repair into the 1990s. *European Journal of Cardio-Thoracic Surgery*. 1992; 6: S13–S16.
- [3] Suri RM, Schaff HV, Dearani JA, Sundt TM, Daly RC, Mullany CJ, *et al.* Survival Advantage and Improved Durability of Mitral Repair for Leaflet Prolapse Subsets in the Current Era. *Annals of Thoracic Surgery*. 2006; 82: 819–826.
- [4] David TE, Ivanov J, Armstrong S, Rakowski H. Late outcomes of mitral valve repair for floppy valves: Implications for asymptomatic patients. *Journal of Thoracic and Cardiovascular Surgery*. 2003; 125: 1143–1152.
- [5] Enriquez-Sarano M, Avierinos J, Messika-Zeitoun D, Detaint D, Capps M, Nkomo V, *et al.* Quantitative determinants of the outcome of asymptomatic mitral regurgitation. *New England Journal of Medicine*. 2005; 352: 875–883.
- [6] Mohty D, Orszulak TA, Schaff HV, Avierinos JF, Tajik JA, Enriquez-Sarano M. Very long-term survival and durability of mitral valve repair for mitral valve prolapse. *Circulation*. 2001; 104: I1–I7.
- [7] Gogbashian A, Sepic J, Soltesz EG, Nascimben L, Cohn LH. Operative and long-term survival of elderly is significant improved by mitral valve repair. *American Heart Journal*. 2006; 151: 1325–1333.
- [8] Nonaka M, Marui A, Fukuoka M, Shimamoto T, Masuyama S, Ikeda T, *et al.* Differences in mitral valve-left ventricle dimensions between a beating heart and during saline injection test. *European Journal of Cardio-Thoracic Surgery*. 2009; 34: 755–759.
- [9] Fix J, Isada L, Cosgrove D, Miller DP, Savage R, Blum J, *et al.* Do patients with less than ‘echo-perfect’ results from mitral valve repair by intraoperative echocardiography have a different outcome? *Circulation*. 1993; 88: II39–II48.
- [10] Kasegawa H, Shimokawa T, Shibazaki I, Hayashi H, Koyanagi T, Ida T. Mitral valve repair for anterior leaflet prolapse with expanded polytetrafluoroethylene sutures. *Annals of Thoracic Surgery*. 2006; 81: 1625–1631.
- [11] Tachibana K, Higami T, Miyaki Y, Takagi N. Novel intraoperative evaluation for mitral valve regurgitation: retrograde cardioprotective beating test. *European Journal of Cardio-Thoracic Surgery*. 2013; 44: 375–376.
- [12] Tachibana K, Higami T, Miyaki Y, Nakagima T, Ito T, Takagi N. Impact of novel intraoperative evaluation for mitral valve regurgitation: the retrograde cardio-protective beating test. *Surgery Today*. 2015; 45: 1153–1159.
- [13] Jennings RB, Ganote CE. Structural changes in myocardium during acute ischemia. *Circulation Research*. 1974; 35: 156–172.
- [14] Goode D, Kermen E, Mohammadi H. Wrinkle-induced tear in the mitral valve leaflet tissue: a computational model. *Journal of Medical Engineering & Technology*. 2020; 44: 346–353.
- [15] Nappi F, Attias D, Avtaar Singh SS, Prot V. Finite element analysis applied to the transcatheter mitral valve therapy: Studying the present, imagining the future. *Journal of Thoracic and Cardiovascular Surgery*. 2019; 157: e149–e151.
- [16] Lopes JB, Santos CCMD. Coronary Perfusion Pressure during Antegrade Cardioplegia in on-Pump CABG Patients. *Brazilian Journal of Cardiovascular Surgery*. 2017; 32: 171–176.
- [17] Allen BS, Rosenkranz E, Buckberg GD, Davtyan H, Laks H, Tillisch J, *et al.* Studies on prolonged acute regional ischemia. VI. Myocardial infarction with left ventricular power failure: a medical/surgical emergency requiring urgent revascularization with maximal protection of remote muscle. *The Journal of Thoracic and Cardiovascular Surgery*. 1989; 98: 691–693.
- [18] Teoh KH, Christakis GT, Weisel RD, Fremes SE, Mickle DA, Romaschin AD, *et al.* Accelerated myocardial metabolic recovery with terminal warm blood cardioplegia. *Journal of Thoracic and Cardiovascular Surgery*. 1986; 91: 888–895.
- [19] Buckberg GD, Beyersdorf F, Allen BS, Robertson JM. Integrated myocardial management: background and initial application. *Journal of Cardiac Surgery*. 1995; 10: 68–89.
- [20] Rosenkranz ER, Vinten-Johansen J, Buckberg GD, Okamoto F, Edwards H, Bugyi H. Benefits of normothermic induction of blood cardioplegia in energy-depleted hearts, with maintenance of arrest by multidose cold blood cardioplegic infusions. *Journal of Thoracic and Cardiovascular Surgery*. 1982; 84: 667–677.
- [21] Roberts AJ, Woodhall DD, Knauf DG, Alexander JA. Coronary artery bypass graft surgery: clinical comparison of cold blood potassium cardioplegia, warm cardioplegic induction, and secondary cardioplegia. *Annals of Thoracic Surgery*. 1985; 40: 483–487.
- [22] Wallace AW, Ratcliffe MB, Nosé PS, Bellows W, Moores W, McEnany MT, *et al.* Effect of induction and reperfusion with warm substrate-enriched cardioplegia on ventricular function. *Annals of Thoracic Surgery*. 2000; 70: 1301–1307.
- [23] Buckberg GD. Substrate enriched warm blood cardioplegia reperfusion: an alternate view. *Annals of Thoracic Surgery*. 2000; 69: 334–335.
- [24] Rama A, Nappi F, Praschker BGL, Gandjbakhch I. Papillary muscle approximation for ischemic mitral valve regurgitation. *Journal of Cardiac Surgery*. 2008; 23: 733–735.
- [25] Nappi F, Antoniou GA, Nenna A, Michler R, Benedetto U, Avtaar Singh SS, *et al.* Treatment options for ischemic mitral regurgitation: A meta-analysis. *The Journal of Thoracic and Cardiovascular Surgery*. 2020. (in press)
- [26] Nappi F, Spadaccio C, Chello M, Lusini M, Acar C. Double row of overlapping sutures for downsizing annuloplasty decreases the risk of residual regurgitation in ischaemic mitral valve repair. *European Journal of Cardio-Thoracic Surgery*. 2016; 49: 1182–1187.
- [27] Nappi F, Lusini M, Avtaar Singh SS, Santana O, Chello M, Mihos CG. Risk of Ischemic Mitral Regurgitation Recurrence after Combined Valvular and Subvalvular Repair. *Annals of Thoracic Surgery*. 2019; 108: 536–543.
- [28] Nappi F, Avtaar Singh SS, Padala M, Attias D, Nejari M, Mihos CG, *et al.* The Choice of Treatment in Ischemic Mitral Regurgitation with Reduced Left Ventricular Function. *Annals of Thoracic Surgery*. 2019; 108: 1901–1912.
- [29] Nappi F, Nenna A, Mihos C, Spadaccio C, Gentile F, Chello M, *et al.* Ischemic functional mitral regurgitation: from pathophysiological concepts to current treatment options. A systemic review for optimal strategy. *General Thoracic and Cardiovascular Surgery*. 2021; 69: 213–229.

- [30] Nappi F, Nenna A, Spadaccio C, Lusini M, Chello M, Fraldi M, *et al.* Predictive factors of long-term results following valve repair in ischemic mitral valve prolapse. *International Journal of Cardiology*. 2016; 204: 218–228.
- [31] Nenna A, Nappi F, Spadaccio C, Barberi F, Greco SM, Lusini M, *et al.* Systolic Anterior Motion (SAM) Complicating Mitral Valve Repair: Current Concepts of Intraoperative and Postoperative Management. *Surgical Technology International*. 2020; 37: 225–232