

Repeat Cardiac Transplant Indicated by Severe Cardiac Allograft Vasculopathy in a Patient With Danon Disease

Richa Thakur^{1,2}, Aasim Afzal^{1,*}, Sandra A. Carey^{3,4}, Kyle Bass⁵, Joost Felijs⁴, William C. Roberts¹ and Shelley A. Hall^{1,3,4}

¹Division of Cardiology, Baylor University Medical Center, Dallas, TX, 75246

²Texas A&M University College of Medicine, Dallas, TX, 75246

³Center for Advanced Heart and Lung Disease, Baylor University Medical Center, Dallas, TX, 75246

⁴Annette C. and Harold C. Simmons Transplant Institute, Baylor Scott and White Research Institute, Dallas, TX, 75246

⁵Soltero Cardiovascular Research Center, Baylor Scott and White Research Institute, Dallas, TX, 75246

*Correspondence to Aasim Afzal: Aasim.Afzal@BSWHealth.org

DOI: 10.31083/j.rcm.2018.02.903

This is an open access article under the CC BY-NC 4.0 license (<https://creativecommons.org/licenses/by-nc/4.0/>)

Danon disease is a rare, X-linked dominant, lysosomal storage disorder, presenting with cardiomyopathy mostly in adolescent men. Male patients face a high mortality rate and rarely live to the age of 25 years unless they receive a heart transplant. Because they generally undergo heart transplantation at a young age, many patients ultimately face both short- and long-term complications. We present a 32-year-old man diagnosed with Danon disease; a nonsense mutation in the LAMP-2 gene. Progressive heart failure symptoms resulted in initial heart transplant at age 27 years. He subsequently developed severe cardiac allograft vasculopathy that led to graft failure requiring a redo orthotopic heart transplant. This is one of only two reported Danon disease cases described to date surviving repeat orthotopic heart transplants. We present this case to highlight the importance of heart transplantation in the management of Danon disease, to emphasize the risk of cardiac allograft vasculopathy post-transplant, and to discuss management strategies.

Keywords

Danon disease; Cardiac allograft vasculopathy; Cardiac transplantation

1. Introduction

Danon disease is a rare, X-linked dominant, lysosomal storage disorder caused by deficiencies in the lysosomal associated membrane protein 2 (LAMP2) gene (Nishino et al., 2000). It classically presents with a triad of cardiomyopathy, skeletal myopathy, and intellectual disabilities, mostly in adolescent males (D'Souza et al., 2017). Other common features of Danon disease include cardiac conduction abnormalities (of which Wolff-Parkinson-White syndrome (WPWS), associated with mutations on the protein kinase AMP-activated non-catalytic subunit gamma 2 (PRKAG2) gene, is the most common), retinal changes, hepatic disease, and pulmonary disease (D'Souza et al., 2014). Due to the inheritance pattern, men present earlier than women. Male patients face a

high mortality rate, and rarely live to the age of 25 years unless they receive a heart transplant. Women present up to 15 years later than men and have higher incidences of intellectual disability and skeletal muscle abnormalities. Although males typically present as progressive hypertrophic cardiomyopathy, females affected with Danon disease have equal rates of dilated cardiomyopathy and hypertrophic cardiomyopathy (Boucek et al., 2011).

As far as we know, only one other case of a patient with Danon disease surviving two orthotopic heart transplants (OHTs) has been reported, with the second transplant indicated in both cases by acute cellular rejection (ACR) (Bui et al., 2008). The case we present here is to our knowledge the first of a patient requiring a second OHT for cardiac allograft vasculopathy (CAV) instead of ACR. Neuropsychological and cognitive functioning in this patient were recently published (Salisbury and Meredith, 2017).

2. Case Report

A 32-year-old white man was diagnosed with Danon disease in his early 20s after his brother's diagnosis triggered a genetic screen. He tested positive for a nonsense mutation in the LAMP2 gene at amino acid position 83. This mutation is known to prevent the fusion of the autophagosome with the lysosome, obstructing the normal breakdown of waste products in the myocardium (Eskelinen et al., 2002; Malicdan et al., 2008). The family history revealed both his mother and maternal grandmother died in their mid- to late 30s due to unspecified cardiovascular disease.

He initially presented to his physician after a syncopal episode due to arrhythmias and was diagnosed with WPWS, for which he received a pacemaker at the age of 17. Soon after that, he was diagnosed with cardiomyopathy, which worsened through his 20s with progressive heart failure symptoms (fatigue and shortness of breath; left ventricular ejection fraction < 0.2), requiring his first OHT at the age of 27 years. Soon after the transplant, he developed an episode of stage-3A rejection, treated successfully with steroids. After remaining asymptomatic for two years post-transplant, his heart failure symptoms recurred. Angiogra-

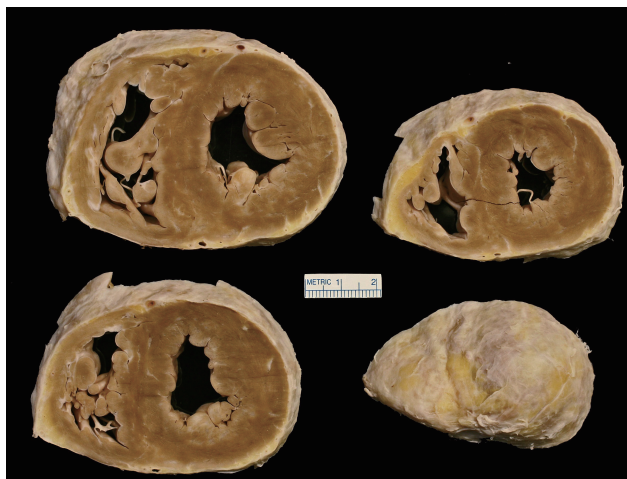


Figure 1. Post-transplant autopsy showing vasculopathy.

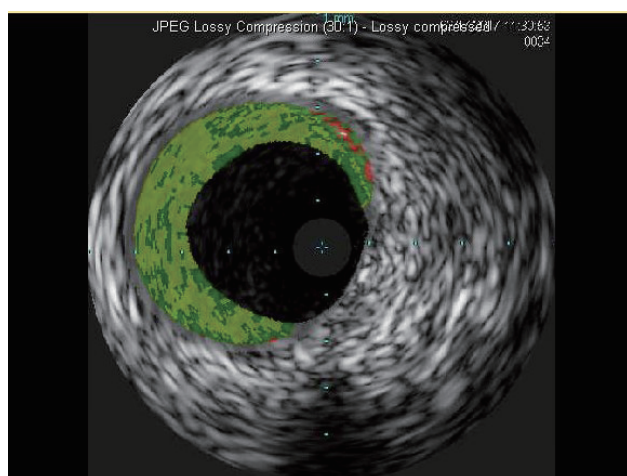


Figure 2. Intravenous ultrasound 12 months following the second transplant, showing CAV grade 0 and ISHLT grade 0.

phy revealed moderate CAV in all 3 cardiac vessels. One year later, he underwent catheterization for non-ST-elevation myocardial infarction, which revealed aggressive CAV3 vasculopathy. He failed a trial for sirolimus and was switched back to mycophenolate for immunosuppression. At age 31 years, he was referred to our high-volume transplant center for a redo OHT. Surgery and hospital course were uncomplicated. Post-transplant autopsy findings were consistent with severe vasculopathy (Fig. 1). In light of the severe CAV and graft failure following his first OHT, he was managed with aggressive immunosuppression, including sirolimus, mycophenolate mofetil, tacrolimus, and prednisone. Cardiac catheterization with intravascular ultrasound (IVUS) at 18-month follow-up showed minimal CAV (Fig. 2). He is currently clinically stable 24 months after the second transplant.

3. Discussion

Deficiencies in the LAMP2 protein in patients with Danon disease result in an accumulation of intracellular vacuoles, which contain granular debris and glycogen. This eventually leads to my-

ocyte enlargement and cellular death, as well as myocardial scarring (Kim et al., 2014). In a large series of 82 cases, the average reported age of first symptoms, cardiac transplantation, and death were 12, 17, and 19 years in men and 27, 33, and 34 years in women, respectively (Boucek et al., 2011). Symptoms can vary from being asymptomatic for several years to sudden cardiac death. Extracardiac symptoms can vary from muscle aches to profound skeletal myopathy and mental retardation. Arrhythmias are common and often the initial presentation. Maron and colleagues reported 5 out of 6 male patients having WPWS (Maron et al., 2009). An implantable cardioverter-defibrillator (ICD) is frequently used as a preventive measure, with Boucek and colleagues reporting ICD placement in 41% of men and 31% of women (Boucek et al., 2011).

Echocardiography is commonly used in diagnosing patients with Danon disease along with genetic testing. Male patients typically have echocardiograms consistent with typical hypertrophic cardiomyopathy with maximal left ventricular (LV) thickening in the range of 29-65 mm. Female patients have equal prevalence of hypertrophic and dilated cardiomyopathy (Maron et al., 2009). There are a few reports of Danon disease presenting with dilated cardiomyopathy with non-compaction (Stöllberger and Finsterer, 2013). Electrocardiogram can have patterns consistent with LV hypertrophy with high QRS voltages and can have a WPWS pattern. Laboratory values may show elevated levels of aldolase, creatine kinase, and transaminases. Ultimately, genetic testing plays an important role in the final diagnosis of Danon disease. Once diagnosis is confirmed, it is recommended to have family members tested as well (Poignant et al., 2018).

Due to the limited knowledge about Danon disease, no treatment protocols have been published. Clinicians frequently treat heart failure secondary to Danon disease similarly to other heart failure with hypertrophic cardiomyopathy, with the caveat that patients with Danon disease progress more rapidly (D'Souza et al., 2014). Management of tachyarrhythmias with catheter-based ablations is frequently performed in addition to ICD placements in patients at increased risk of sudden cardiac death. OHT is often pursued after medical management fails. Survival after transplant is similar in patients with Danon disease compared with patients undergoing OHT for other causes (Poignant et al., 2018).

The short-term morbidities that contribute to death within 1 year following OHT include ACR, infection, and non-specific graft rejection. CAV affects approximately 26% of patients surviving the first year, 52% surviving the first 5 years, and 68% surviving 10 years (Lund et al., 2014). Patients suffering from CAV present more often with progressive heart failure symptoms instead of angina due to denervation of the coronary arteries (Sko-ric et al., 2014). Although cardiac catheterization is considered the gold standard for measuring coronary artery disease, it is not sensitive enough to screen for CAV, and thus, IVUS is typically needed to assess the degree of CAV. Proximal disease is more often associated with coronary artery disease, with a pathogenesis of atherosclerotic lesions and is donor-inherited. Distal disease, on the other hand, occurs more often with CAV, and is autoimmune in nature.

Efforts to prevent CAV include early detection and aggressive prevention. IVUS can detect intimal thickening, a marker for CAV,

in > 80% of patients as early as 1-year post-OHT. Because the most rapid rate of thickening occurs within the first year after transplant, annual IVUS screenings are generally recommended to monitor the development of CAV. Due to the development of aggressive CAV after our patient's first OHT, more rigorous protocols for surveillance of CAV were deemed necessary, along with a more stringent immunosuppression protocol as outlined above. Thus, IVUS was performed as early as 2 months post-operatively to screen for any premature complications, particularly CAV. To date, this is the only case in the literature of a patient with Danon disease undergoing cardiac transplantation due to advanced CAV.

4. Summary

Treatment and management of CAV remains a major limitation of the long-term success of OHT, particularly in Danon disease. CAV develops in approximately 32% of patients before 5 years after their transplant. Because patients with Danon disease require OHT at such an early age, this places them at a very high lifetime risk of developing CAV and needing a second OHT. As illustrated in the patient reviewed here, thorough, early monitoring of cardiovascular symptoms as well as aggressive treatment with immunosuppressive agents may be the best option for improving length and quality of life.

Acknowledgments

Thanks to all the peer reviewers and editors for their opinions and suggestions.

Conflict of Interest

The authors declare no competing interests.

References

- Boucek D, Jirikowic J, Taylor M. Natural history of Danon disease. *Genet Med*. 2011;13:563-568.
- Bui YK, Renella P, Martinez-Agosto JA, et al. Danon disease with typical early-onset cardiomyopathy in a male: focus on a novel LAMP-2 mutation. *Pediatr Transplant*. 2008;12:246-250.
- D'Souza RS, Levandowski C, Slavov D, et al. Danon Disease: clinical features, evaluation, and management. *Circ Heart Fail*. 2014;7:843-849.
- D'Souza RS, Mestroni L, Taylor MRG. Danon disease for the cardiologist: case report and review of the literature. *J Community Hosp Intern Med Perspect*. 2017;7:107-114.
- Eskelinen EL, Illert AL, Tanaka Y, et al. Role of LAMP-2 in lysosome biogenesis and autophagy. *Mol Biol Cell*. 2002;13:3355-3368.
- Kim J, Parikh P, Mahboob M, Arrighi JA, et al. Asymptomatic young man with Danon disease. *Tex Heart Inst J*. 2014;41:332-334.
- Lund LH, Edwards LB, Kucheryavaya AY, et al. The registry of the International Society for Heart and Lung Transplantation: thirty-first official adult heart transplant report—2014; focus theme: retransplantation. *J Heart Lung Transplant*. 2014;33:996-1008.
- Malicdan MC, Noguchi S, Nonaka I, et al. Lysosomal myopathies: an excessive build-up in autophagosomes is too much to handle. *Neuromuscul Disord*. 2008;18:521-529.
- Maron BJ, Roberts WC, Arad M, et al. Clinical outcome and phenotypic expression in LAMP2 cardiomyopathy. *JAMA*. 2009;301:1253-1259.
- Nishino I, Fu J, Tanji K, et al. Primary LAMP-2 deficiency causes X-linked vacuolar cardiomyopathy and myopathy (Danon disease). *Nature*. 2000;406:906-910.
- Poignant S, Bourguignon T, Espitalier F. Heart transplantation in Danon disease: a single family displaying diverse phenotypes. *J Heart Lung Transplant*. 2018;37:312-313.
- Salisbury D, Meredith K. Neuropsychological functioning following cardiac transplant in Danon disease. *Dev Neurorehabil*. 2017;8:1-4.
- Skoric B, Cikes M, Ljubas Macek J, et al. Cardiac allograft vasculopathy: diagnosis, therapy, and prognosis. *Croat Med J*. 2014;55:562-576.
- Stöllberger C, Finsterer J. Consider Danon disease in dilated cardiomyopathy with noncompaction. *Muscle Nerve*. 2013;48:152-153.