

# Recurrent Asymptomatic Right Atrial Myxoma

Michael Funk, MD,<sup>1</sup> Orlando Santana, MD,<sup>1</sup> Joseph Lamelas, MD<sup>2</sup>

<sup>1</sup>Columbia University Division of Cardiology and <sup>2</sup>Columbia University Division of Cardiac Surgery, Mount Sinai Heart Institute, Miami Beach, FL

*Cardiac myxoma is the most common primary tumor of the heart. The clinical presentation ranges from asymptomatic to symptomatic with constitutional symptoms, obstructive symptoms, or evidence of embolism. Most cases are sporadic; recurrence rates are low after surgical excision for these cases. We present a case of an asymptomatic right atrial myxoma which recurred 1 year after its resection.*

[Rev Cardiovasc Med. 2010;11(3):e176-e180 doi: 10.3909/ricm0542]

© 2010 MedReviews®, LLC

---

**Key words:** Cardiac myxoma • Embolization • Transthoracic echocardiogram • Recurrent atrial myxoma

Cardiac myxoma is the most common primary tumor of the heart. Approximately 75% originate in the left atrium, 18% in the right atrium, and the remainder in the ventricles.<sup>1</sup> The clinical presentation ranges from asymptomatic to symptomatic with constitutional symptoms, obstructive symptoms, or evidence of embolism.<sup>2</sup> Most cardiac myxomas are benign and can be removed surgically. After removal, they may recur. Recurrence rates are low for sporadic forms and higher for the familial forms.<sup>3,4</sup> We present a case of an asymptomatic right atrial myxoma that recurred 1 year after its resection.

### Case Report

A 60-year-old asymptomatic black woman with a history of hypertension, diabetes, and dyslipidemia was noted to have a new murmur on physical examination. She denied any family history of cardiac masses. She denied shortness of breath, dizziness, syncope, chest pain, palpitations, weight loss, fever, cough, edema, history of embolism, or history of malignancy. Her electrocardiogram showed normal sinus rhythm. On transthoracic echocardiogram (TTE), a large right atrial mass was noted. She was referred to our institution for transesophageal echocardiography (TEE).

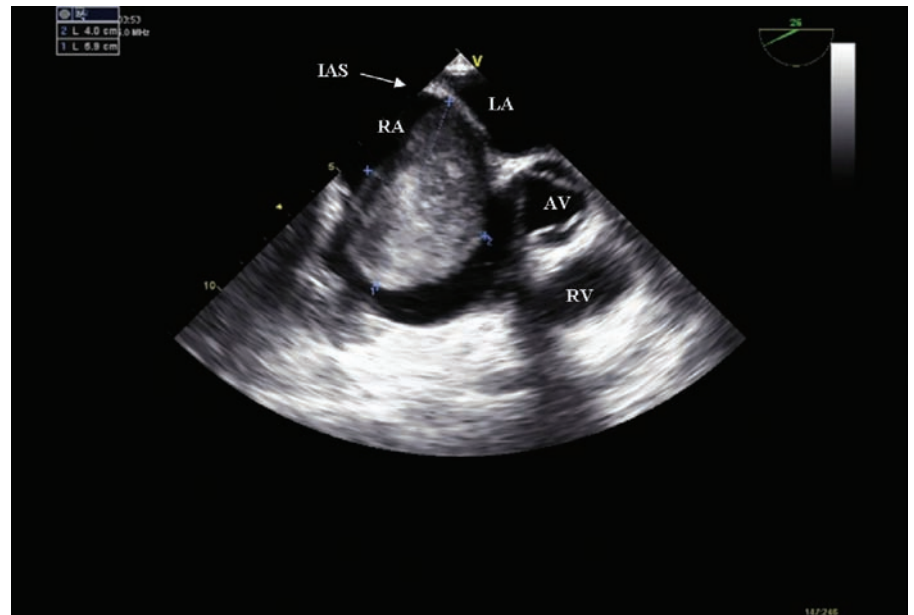
On physical examination her pulse was 80 beats/min and her blood pressure was 110/60 mm Hg; her lungs were clear to auscultation and there was a normal S1 and S2 with a 1/6 systolic ejection murmur heard at the left sternal border. Her neck was supple with no jugular venous distention. There was no clubbing, cyanosis, or edema of the extremities. TEE demonstrated a solid mass in the right atrium, measuring 5.9 cm  $\times$  4.0 cm, attached to the interatrial septum (Figure 1). The mass extended into the right ventricle; however, it did not cause functional tricuspid stenosis.

A cardiac catheterization showed nonobstructive disease of the coronary arteries. An elective minimally invasive resection of the right atrial mass was performed via a right minithoracotomy. Her postoperative course was uneventful, and she was discharged 4 days later. The pathologic evaluation demonstrated the mass to be an atrial myxoma (Figure 2).

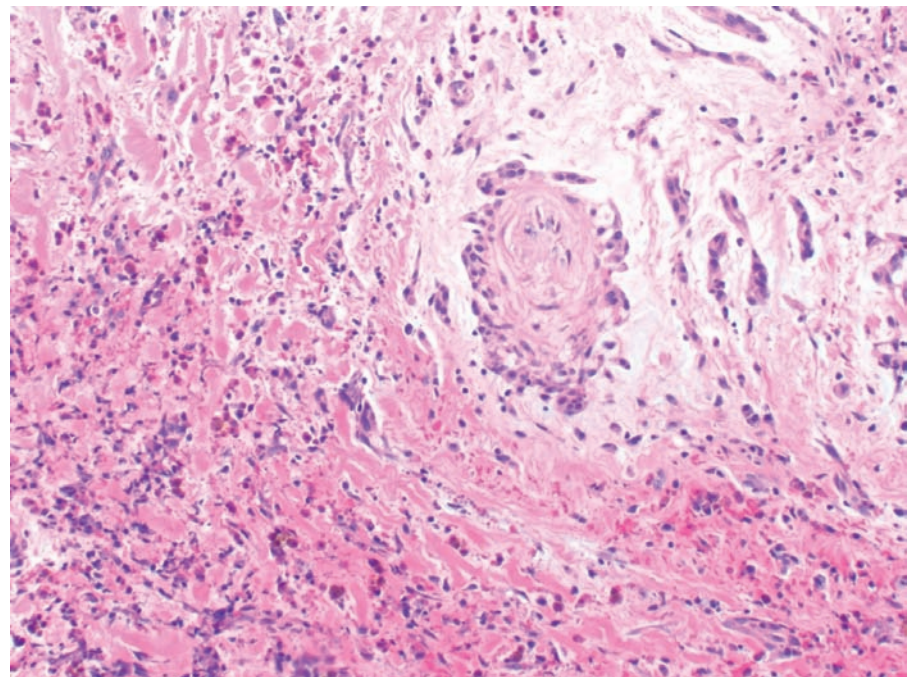
One year later she was asymptomatic; however, a repeat TTE demonstrated the recurrence of the right atrial mass, and a subsequent TEE confirmed the presence of this mass

(Figure 3). There were no other abnormalities found. She underwent repeat minimally invasive surgery

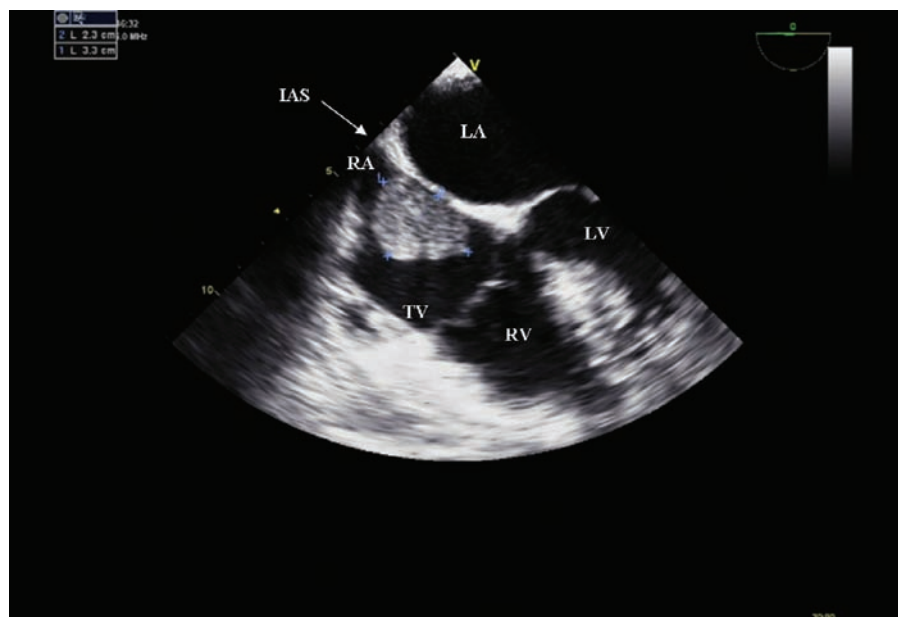
for removal of the mass (Figure 4). Pathologic evaluation again demonstrated it to be a myxoma.



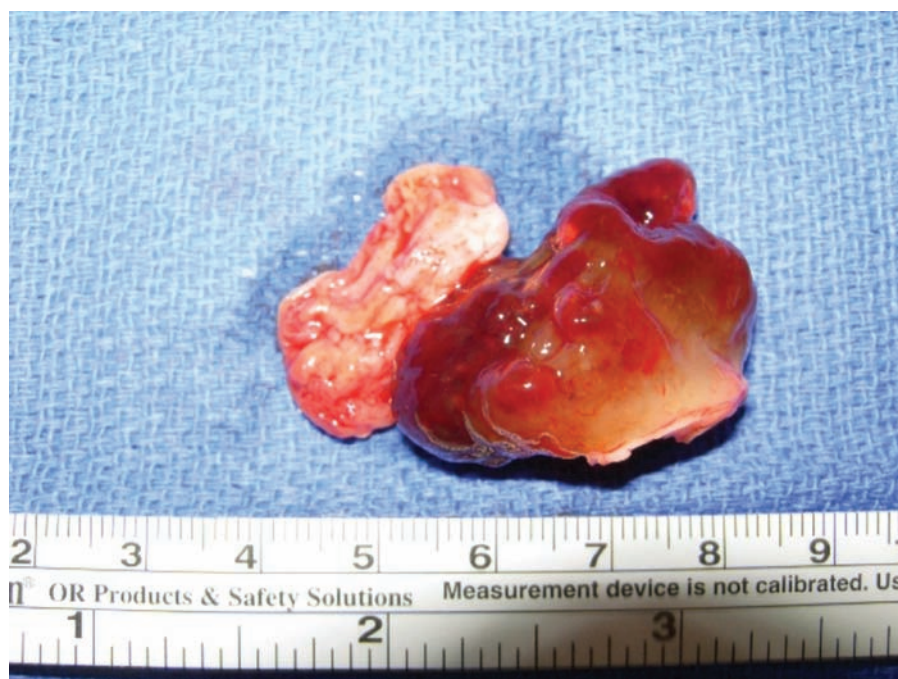**Figure 1.** Transesophageal echocardiogram (mid-esophageal view) showing a 5.9 cm  $\times$  4.0 cm right atrial mass attached to the interatrial septum. AV, aortic valve; IAS, interatrial septum; LA, left atrium; RA, right atrium; RV, right ventricle.



**Figure 2.** Myxoma with myxoid stroma and tumor cells forming linear aggregates and vascular rings. Hemorrhage, hemosiderin deposition, and chronic inflammation are also present (original magnification,  $\times 100$ ).



**Figure 3.** Transesophageal echocardiogram (mid-esophageal 4-chamber view) demonstrating recurrence of the right atrial myxoma attached to the interatrial septum. IAS, interatrial septum; LA, left atrium; LV, left ventricle; RA, right atrium; RV, right ventricle; TV, tricuspid valve.



**Figure 4.** Mass removed during the second surgery.

## Discussion

Myxomas account for 40% to 50% of primary cardiac tumors. Most cases are sporadic, and approximately 10%

are familial with autosomal dominant transmission. There are also rare complex myxomas that present as part of the Carney complex (a

dominantly inherited syndrome characterized by spotty skin pigmentation, endocrine overactivity, and myxomas).<sup>5</sup> These complex myxomas can develop in any chamber of the heart, and can be numerous. Myxomas can occur in all age groups, but are most frequent between the third and sixth decades of life, and occur predominantly in women.<sup>6</sup>

Asymptomatic right atrial myxomas are rare.<sup>7</sup> When symptomatic, patients may present with right-sided heart failure from functional obstruction of the tricuspid valve.<sup>3,8</sup> Other symptoms, due to the release of interleukin-6, are constitutional and include fatigue, weight loss, fever, and arthralgia.<sup>8</sup> Diagnosis is important, as symptoms may develop into coronary or systemic embolization and become lethal.<sup>9,10</sup> Histopathologic examination confirms the diagnosis.

Embolization to the spleen, kidneys, abdominal aorta, coronary arteries, adrenals, intestine, and mesentery and limb arteries has been reported in 10% to 45% of cases. Neurologic manifestations have been reported in 25% to 45% of cases and are usually the result of embolization.<sup>11</sup> Strokes are often recurrent and can be hemorrhagic or embolic.<sup>12</sup> Emboli can be myxomatous or arise from thrombus that is connected to the tumor. Cerebral infarction from left atrial myxoma has been reported in 27% of cases.<sup>11</sup> Anticoagulation and antiplatelet therapy show little benefit in preventing embolization.<sup>12</sup>

Echocardiography is the imaging modality of choice for diagnosis. Myxomas vary in location, size, density, and number. Their echocardiographic description, as reported by Grebenc and colleagues,<sup>13</sup> includes lobular shape in 51% of cases, smooth shape in 33% of cases, and frond-like



or irregular shape in 16% of cases. The texture of the myxomas is soft gelatinous or friable in 70% of cases, firm in 18% of cases, and mixed soft and firm in 11% of cases. It is important to note that large vegetations, thrombi, or even mitral valve prolapse can be difficult to distinguish from myxomas.<sup>14</sup> Additional information may be gained by using electron beam computed tomography (CT) and/or magnetic resonance imaging (MRI).<sup>15</sup> Intracavitary heterogeneous and hypoattenuated lobular masses may be seen by CT, whereas MRI may show heterogeneous lobular lesions. A myxoma is hypointense relative to myocardium on T<sub>1</sub>-weighted MRI, and hyperintense on T<sub>2</sub>-weighted images.<sup>16</sup>

Surgical removal of the myxoma is the recommended therapy, and is usually curative. They are most commonly attached to the fossa ovalis, and should be excised with a large cutoff of the atrial septum.<sup>15</sup> The intraoperative mortality rate is low, and the prognosis is excellent.<sup>6</sup> In a series of 112 patients, there were no deaths intraoperatively, and only 4 deaths occurred over a median follow-up of 3 years.<sup>6</sup> Endoscopic cardiac tumor removal using a port access approach has been described in a series of 27 patients with favorable outcomes, as compared with a standard median sternotomy

approach.<sup>17</sup> Minimally invasive surgical removal of cardiac tumors has become the standard approach (as was demonstrated in our case) to help prevent complications of median sternotomy. Percutaneous removal of atrial myxoma has not been described.

Once removed, the incidence of recurrence ranges from 1% to 3% for

of the 23 patients.<sup>18</sup> Cases involving second recurrences of the myxoma are exceedingly rare.<sup>8,19,20</sup>

The symptoms of recurrent myxomas are usually the same as those of nonrecurrent myxomas.<sup>8</sup> Repeat surgical resection is the standard therapy for recurrence. In most cases surgical resection leads to a cure; however, extensive excisional ther-

---

*Repeat surgical resection is the standard therapy for recurrence. In most cases surgical resection leads to a cure; however, extensive excisional therapy and cardiac transplantation have been reported in cases in which resection of the tumor is impossible.*

---

the sporadic forms, 12% for the familial forms, and 22% for the complex forms.<sup>3,4</sup> The recurrence can be explained by several mechanisms that include incomplete resection of the original tumor, familial predisposition, intracardiac implantation of embolic fragments from the first tumor, or malignant change.<sup>8,11,18</sup> Gray and Williams<sup>18</sup> reviewed reported cases of recurrent myxomas in 23 patients, and found that the original myxoma was in the left atrium in all cases, and the right atrium was the site for recurrence in only 2 cases.<sup>18</sup> They also noted that the recurrence of these tumors happened fairly soon after the operation, occurring within 2 years in 6 of the 23 patients, and within 4 years in 19

apies and cardiac transplantation have been reported in cases in which resection of the tumor is impossible.<sup>21</sup> One case reported by Goldstein and associates<sup>21</sup> was that of a recurrent myxoma in which re-excision was impossible because of involvement of the pulmonary veins and superior vena cava.

## Conclusions

Recurrence rates are low for cardiac myxoma after surgical excision for sporadic cases. Once the diagnosis of recurrence is confirmed, a repeat attempt at resection should be performed. It is important that emphasis is placed on follow-up after resection with serial echocardiography, as patients may be asymptomatic. If

## Main Points

- Cardiac myxoma is the most common primary tumor of the heart; myxomas account for 40% to 50% of primary cardiac tumors.
- Patients may present with right-sided heart failure from functional obstruction of the tricuspid valve. Other symptoms include fatigue, weight loss, fever, and arthralgia.
- Echocardiography is the imaging modality of choice for diagnosis, and diagnosis is confirmed by histopathologic examination.
- Surgical removal of the myxoma is the recommended therapy, and is usually curative. Once removed, the incidence of recurrence ranges from 1% to 3% for the sporadic forms, 12% for the familial forms, and 22% for the complex forms.

familial cardiac myxomas are present, first-degree relatives should be screened and followed carefully. Our case illustrates the importance of echocardiography for early detection of recurrence, especially in asymptomatic patients. ■

*Special thanks to Andrew Schubeck, MD, Arkadi Rywlin Department of Pathology, Mount Sinai Medical Center, Miami Beach, FL.*

## References

- Charokopos NA, Rouska E, Pliakos C, et al. Atypical atrial myxomas in two asymptomatic patients: a case report. *Cardiovasc Ultrasound*. 2009;7:45.
- Pliakos C, Alexiadou E, Metallidis S, et al. Right atrium myxoma coexisting with antiphospholipid syndrome: a case report. *Cardiovasc Ultrasound*. 2009;7:47.
- Mittle S, Makaryus AN, Boutis L, et al. Right-sided myxomas. *J Am Soc Echocardiogr*. 2005;18:695.
- Etxebeste J, Arrillaga M, Basurto J, et al. Multiple recurrent local myxoma. *Echocardiography*. 1998;15:257-258.
- Bertherat J. Carney complex (CNC). *Orphanet J Rare Dis*. 2006;1:21.
- Pinede L, Duhaut P, Loire R. Clinical presentation of left atrial cardiac myxoma. A series of 112 consecutive cases. *Medicine*. 2001;80:159-172.
- Lamparter S, Moosdorf R, Maisch B. Giant left atrial mass in an asymptomatic patient. *Heart*. 2004;90:e24.
- Hermans K, Jaarsma W, Plokker HW, et al. Four cardiac myxomas diagnosed three times in one patient. *Eur J Echocardiogr*. 2003;4:336-338.
- González A, Altieri PJ, Márquez EU, et al. Massive pulmonary embolism associated with a right ventricular myxoma. *Am J Med*. 1980;69:795-798.
- Canale LS, Colafranceschi AS, Leal Botelho ES, de Oliveira Monteiro AJ. Surgical treatment of right atrial myxoma complicated with pulmonary embolism. *Interact Cardiovasc Thorac Surg*. 2009;9:535-536.
- Knepper LE, Biller J, Adams HP Jr, Bruno A. Neurologic manifestations of atrial myxoma. A 12-year experience and review. *Stroke*. 1988;19:1435-1440.
- O'Rourke F, Dean N, Mouradian MS, et al. Atrial myxoma as a cause of stroke: case report and discussion. *CMAJ*. 2003;169:1049-1051.
- Grebenc ML, Rosado-de-Christenson ML, Green CE, et al. Cardiac myxoma: imaging features in 83 patients. *Radiographics*. 2002;22:673-689.
- Vohra HA, Vohra H, Patel RL. Cardiac myxoma with three recurrences. *J R Soc Med*. 2002;95:252-253.
- Wintersperger BJ, Becker CR, Gulbins H, et al. Tumors of the cardiac valves: imaging findings in magnetic resonance imaging, electron beam computed tomography, and echocardiography. *Eur Radiol*. 2000;10:443-449.
- Yuan SM, Shinfeld A, Lavee J, et al. Imaging morphology of cardiac tumours. *Cardiol J*. 2009;16:26-35.
- Deshpande RP, Casselman F, Bakir I, et al. Endoscopic cardiac tumor resection. *Ann Thorac Surg*. 2007;83:2142-2146.
- Gray IR, Williams WG. Recurring cardiac myxoma. *Br Heart J*. 1985;53:645-649.
- Turhan S, Tulunay C, Altin T, Dincer I. Second recurrence of familial cardiac myxomas in atypical locations. *Can J Cardiol*. 2008;24:715-716.
- Moyssakis I, Anastasiadis G, Papadopoulos D, et al. Second recurrence of cardiac myxoma in a young patient. A case report. *Int J Cardiol*. 2005;101:501-502.
- Goldstein DJ, Oz MC, Michler RE. Radical excisional therapy and total cardiac transplantation for recurrent atrial myxoma. *Ann Thorac Surg*. 1995;60:1105-1107.