

Evolving treatments of virus-associated HCC: new targets and drugs

Hans Christian Spangenberg, Robert Thimme, Hubert E. Blum

Department of Medicine II, University of Freiburg, D-79106 Freiburg, Germany

TABLE OF CONTENTS

1. Abstract
2. Introduction
3. HCC screening, staging and natural course
4. Established Therapies
 - 4.1. Resection
 - 4.2. Liver transplantation
 - 4.3. Percutaneous Interventions
 - 4.4. Transarterial Interventions
 - 4.5. Drugs
5. Evolving Therapies
 - 5.1. Optimization of established therapies
 - 5.2. Radiation therapy
 - 5.3. Drugs
 - 5.4. Experimental strategies
6. HCC Prevention
7. Summary and perspectives
8. References

1. ABSTRACT

Hepatocellular carcinoma (HCC) is one of the most common malignant tumors worldwide. The major etiologies and risk factors for HCC development are well defined and some of the multiple steps involved in hepatocarcinogenesis have been elucidated in recent years. The therapeutic options fall into five main categories: (1) surgical interventions, incl. liver transplantation, (2) percutaneous interventions, incl. ethanol injection and radiofrequency thermal ablation, (3) transarterial interventions, (4) radiation therapy and (5) drugs as well as gene and immune therapies. Because of the poor survival of the majority of patients, HCC prevention as well as early diagnosis and the development of novel systemic therapies for advanced disease are of paramount importance. In this context, recent data indicate that the 'targeted therapy' with monoclonal antibodies (mabs) or small molecule tyrosine kinase inhibitors (nibs) and other drugs seem to be effective to some degree. New technologies, including gene expression profiling and proteomic analyses, should allow to further elucidate the molecular events underlying HCC development and to identify novel diagnostic markers as well as therapeutic and preventive targets.

2. INTRODUCTION

Hepatocellular carcinoma (HCC) is one of the most common malignant tumors worldwide and has been recently reviewed (1, 2). The incidence ranges from <10 cases per 100,000 population and year in North America and Western Europe to 50-150 cases in parts of Africa and Asia where HCC is responsible for a large proportion of cancer deaths (3). However, a rise in the incidence of and mortality from HCC, most likely reflecting the prevalence of hepatitis C virus (HCV) infection, has recently been observed also in most industrialized countries (4).

The major etiologies of HCC are well defined (Table 1) and include in addition to the well known factors an elevated body mass index in men (5) as well as diabetes mellitus (6). Some of the steps involved in the molecular pathogenesis of HCC have been elucidated in recent years. As for most types of cancer, hepatocarcinogenesis is a multistep process involving different genetic alterations that ultimately lead to malignant transformation of the hepatocyte. While significant progress has been made in recognizing the sequence of events in other forms of cancer, most notably in colorectal cancer and certain

Table 1. Major HCC etiologies

Chronic Hepatitis B or D, and C
Toxins (e.g., alcohol, tobacco, aflatoxins)
Hereditary metabolic liver diseases (e.g., hereditary hemochromatosis, α -1-antitrypsin deficiency)
Autoimmune hepatitis
States of insulin resistance
• Overweight in males
• Diabetes mellitus
• Non-alcoholic steatohepatitis (NASH) or non-alcoholic fatty liver disease (NAFLD)

hematopoietic malignancies, the molecular events and their interactions in hepatocarcinogenesis are still poorly understood. HCCs are phenotypically (morphology, microscopy) and genetically very heterogeneous tumors, possibly reflecting in part the heterogeneity of etiologic factors implicated in HCC development, the complexity of hepatocyte functions and the late stage at which HCCs usually become clinically symptomatic and detectable. Malignant transformation of hepatocytes may occur regardless of the etiology through a pathway of increased liver cell turnover, induced by chronic liver injury and regeneration in a context of inflammation, immune response and oxidative DNA damage. This may result in genetic alterations, such as the activation of cellular oncogenes, the inactivation of tumor suppressor genes, possibly in cooperation with genomic instability, including DNA mismatch repair defects and impaired chromosomal segregation, overexpression of growth and angiogenic factors, and telomerase activation (7-11). Further, there is evidence for the existence of liver stem cells that may be progenitors of HCC cells (12). Chronic viral hepatitis B or D, C, alcohol, metabolic liver diseases such as hemochromatosis and α -1-antitrypsin deficiency as well as non-alcoholic fatty liver disease may act predominantly through this pathway of chronic liver injury, regeneration, and cirrhosis. The major clinical risk factor for HCC development is liver cirrhosis since 70-90% of HCCs develop in a cirrhotic liver. Most HCCs occur after many years or decades of chronic hepatitis that provides the mitogenic and mutagenic environment to precipitate random genetic alterations resulting in the malignant transformation of hepatocytes and HCC development.

The HCC risk in patients with liver cirrhosis depends on the activity, duration and the etiology of the underlying liver disease. Clinical and biological variables (age, anti-HCV positivity, PTT and platelet count) allow to further identify a subset of cirrhotic patients with a very high risk for HCC development (13). Coexistence of etiologies, e. g., hepatitis B virus (HBV) and HCV infection, HBV infection and aflatoxin B1 (11, 14), HBV/HCV infection and alcohol or diabetes mellitus (15), HCV infection and liver steatosis (16) or environmental factors, e.g., alcohol (11, 17, 18) as well as diabetes mellitus, obesity and tobacco (5, 18-20) increase the relative risk of HCC development of a single etiology. Also, occult HBV infection (anti-HBc positive only) carries a significant HCC risk (21, 22). Interestingly, coffee consumption appears to reduce the HCC incidence (23-25).

In general, HCCs are more frequent in males than in females and the incidence increases with age. On the other hand, there is evidence that HBV -and possibly also

HCV- may under certain circumstances play an additional direct role in the molecular pathogenesis of HCC. Finally, aflatoxins have been shown to induce mutations of the p53 tumor suppressor gene, thus pointing to the contribution of an environmental factor to tumor development at the molecular level. Further, in a transgenic mouse model it has been shown that chronic immune-mediated liver cell injury without environmental or infectious agents is sufficient to cause HCC (26) and that inhibition of cytotoxic T lymphocyte-induced apoptosis and chronic inflammation by neutralization of the Fas ligand prevents HCC development in this model (27). In addition, also in a transgenic mouse model it has been demonstrated that NF-kappaB may be the link between inflammation and HCC development (28, 29). Finally, individual polymorphisms of drug metabolizing enzymes, e.g., various cytochrome P450 oxidases, N-acetyltransferases and glutathione-S-transferase, may contribute to the genetic susceptibility to HCC development(30).

3. HCC SCREENING, STAGING AND NATURAL COURSE

HCC screening is routinely done in all individuals at risk for HCC development at 6 months intervals and includes laboratory tests, such as liver function tests and alpha fetoprotein (AFP), imaging analyses, e. g., abdominal ultrasound, contrast enhanced CT or MRI and histopathology (31). Apart from AFP two additional tumor markers are now commercially available (32): des-gamma-carboxy-prothrombin (DCP) and lens culinaris agglutinin reactive fraction of AFP (AFP-L3).

For HCC staging seven systems have been proposed that assess the extent and the prognosis of the disease (31, 33): the Okuda staging system (34), the TNM classification and its modification by the 'Union International Contre Cancer (UICC)'(35), the 'Barcelona Clinic Liver Cancer (BCLC)' classification (36), the 'Cancer of the Liver Italian Program (CLIP)' score (37), the 'Japan Integrated Staging (JIS)' score (38), the Groupe d'Etude de Traitement du Carcinoma Hepatocellulaire (GRETCH) score (39) and the Chinese University Prognostic Index (CUPI). The Okuda staging system is very effective for the identification of a subgroup of patients (Okuda III) with a very poor prognosis who should be treated with best supportive care (BSC) only. The BCLC classification appears especially useful for the selection of treatment options but has not been independently validated. The CLIP score was shown to be superior to the Okuda staging system but has not been systematically assessed in patients undergoing resection or liver transplantation (LTx). While a recent study indicates that the new prognostic JIS score is superior to the CLIP score(38), a comparison of the staging systems in an American cohort revealed that the BCLC had the best independent predictive power (40).

The natural course of the disease and the median survival of patients with HCC depend on the stage of the disease at the time of diagnosis. In patients with CLIP score O or Okuda stage I the median survival is in the range of 23-69 months, while in patients with CLIP score 3-5 or

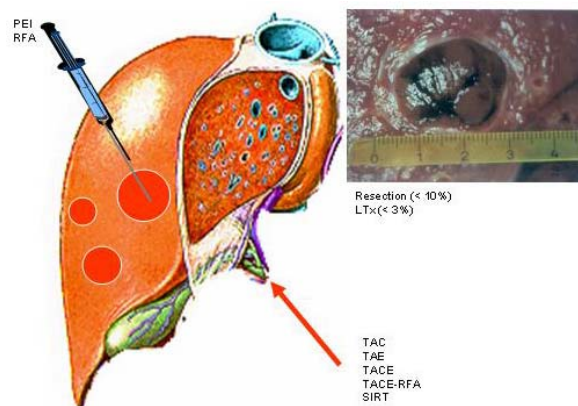


Figure 1. HCC: Current therapeutic options

Okuda stage III median survival is only 1-14 months (41). The staging system is clinically most important for the choice of the appropriate therapeutic strategy for individual patients. Cirrhotic patients developing a HCC during the last 5 years of surveillance survived longer than previously, due to improved management of the tumor and of the complications of cirrhosis (42). Importantly, however, in a population-based study in the US underutilization of potentially curative therapies even among patients with favourable HCC features is a problem that needs to be addressed (43).

4. ESTABLISHED THERAPIES

Therapies for HCC can be divided into several categories: surgical interventions (tumor resection and LTx), percutaneous interventions (ethanol injection, radiofrequency thermal ablation), transarterial interventions (embolization, chemoperfusion, chemoembolization or selective internal radiation [SIRT]), radiation therapy and drugs, including gene and immune therapy (Figure 1). Potentially curative therapies are tumor resection, LTx, and percutaneous interventions that can result in a complete response and improved survival in a high proportion of patients. In selected cases transarterial interventions results in palliation with in some cases good response rates and improved survival. Except for sorafenib, drugs as well as conventional radiotherapy have no proven efficacy.

To date, surgical, percutaneous and transarterial interventions have not been compared in randomized controlled trials. Tumor resection and LTx result in selected patient populations in 5-year survival rates of 60-70%, with LTx being the best treatment for patients with single lesions and advanced liver disease, e.g., decompensated cirrhosis, or multicentric small tumours. Percutaneous interventions, again in selected patient populations, result in 5-year survival rates of 40-50%. In the following the different therapeutic options as well as primary and secondary HCC prevention will be discussed in some detail.

4.1. Resection

In patients without concomitant liver cirrhosis (5% in Western countries, 40% in Sub-Saharan Africa and

Asia) HCC resection is the treatment of choice with low rates of life-threatening complications. By comparison, in the majority of patients with cirrhosis, strict selection is required to avoid resection-related complications, especially postoperative liver failure (44). Apart from bilirubin and albumin concentration as well as platelet count and indocyanine green clearance (45, 46), a recent study identified an elevated serum concentration of 7s-collagen as an independent risk factor of postoperative liver failure (47).

Resection-related mortality should be <1-3%, and the 5-year survival rates should be >50%. In patients with normal liver function (normal indocyanine green retention rate and bilirubin level), absence of clinically relevant portal hypertension (hepatic venous pressure gradient <10 mm Hg, no esophageal varices, no splenomegaly, platelet counts >100 x 10⁹/L) and one asymptomatic HCC lesion only, 5-year survival rates of 70% can be achieved. By comparison in patients with clinically relevant portal hypertension, 5-year survival rates are about 50% only and in patients with portal hypertension and evidence of impaired liver function, 5-year-survival rates are even lower.

After successful HCC resection tumor recurrence in the cirrhotic liver (local recurrence as well as *de novo* tumors) in about 70% of patients at 5 years is a major clinical problem. The risk of recurrence is especially high in patients with microvascular invasion and/or additional tumor nodules (45, 48). Therefore, strategies aimed at secondary HCC prevention are of paramount importance (see below).

4.2. Liver transplantation

LTx is in principle the optimal therapeutic option for HCCs because it simultaneously removes the tumour and the underlying cirrhosis, including the risk of HCC recurrence (44, 49-53). While broad selection criteria applied previously led to poor results with recurrence rates of about 50% and 5-year survival rates <40%, the current criteria for LTx in patients with HCC (1 lesion <5 cm in diameter or maximum 3 lesions <3 cm in diameter) result in 5-year survival rates of 70% and more and recurrence rates <15% (54-56). Possibly these criteria can be extended in the future, depending on more experience based on the stage of the disease, macrovascular invasion, histopathological characteristics (histopathology, aneuploidy, microvascular invasion) as well as DNA and RNA chip data (molecular signature, proteomic signature and others) (57, 58).

Clinically, it is most important to shorten the waiting time for LTx to <6 months. This is difficult to achieve with cadaveric LTx given the shortage of donors. With a waiting time >12 months in some Western countries, the drop-out rate of patients is 20-50%. To bridge the time to LTx and to prevent tumor progression, neoadjuvant treatment, e.g., percutaneous and transarterial interventions may lead to an improved outcome (59) (see below). While marginal livers, domino donors, and split LTx had no major impact, living donor LTx has been

shown to be an alternative to cadaveric LTx. Around 3,000 interventions have been done worldwide. However, living donor LTx is a complex procedure that is associated with a morbidity of 20-40% and a donor mortality of 0.3-0.5% (56, 60, 61). Therefore, a very careful selection of patients and donors, including the consideration of ethical, societal and legal issues are central to the successful implementation of living donor LTx for the treatment of patients with HCCs (62).

4.3. Percutaneous interventions

Percutaneous interventions are the best options for small unresectable HCCs (63-65). Tumor ablations can be achieved chemically by percutaneous ethanol injection (PEI) or acetic acid injection (PAI) or thermally by radiofrequency thermal ablation (RFA), microwave-heat induced thermotherapy (HiTT), laser induced thermotherapy (LiTT), or cryoablation. Apart from percutaneous interventions, these techniques can be applied also laparoscopically or after laparotomy.

Initially, PEI was the most widely used percutaneous intervention (66, 67). It is safe, easy to perform, inexpensive and achieves complete tumor response rates of 90-100% in HCCs smaller than 2 cm in diameter, 70% in HCCs of 3 cm diameter and 50% in HCCs of 5 cm in diameter. Patients with liver cirrhosis Child A with complete responses can achieve 5-year survival rates of 50% and more (68). Therefore, PEI is procedure of choice for patients with a single HCC lesion smaller than 5 cm in diameter or with up to 3 lesions smaller than 3 cm in diameter. Survival is predicted by the initial response to PEI (69). However, a recent comparative study demonstrated that LTx is superior to PEI (53).

RFA is an alternative to PEI and is now the most widely used percutaneous therapy (64, 65, 70, 71). Several devices are available that can be applied percutaneously, laparoscopically, or during laparotomy. The efficacy of RFA is similar to PEI but requires generally only a single session (72). While more expensive than PEI, RFA offers a better local tumor control and the potential advantage of allowing the ablation of tumors larger than 5 cm, especially with newer generation devices. However, 5-year survival rates after complete response to RFA are currently, similar to PEI, around 30-40%, depending among others on the Child stage of the underlying liver cirrhosis. In a review of 3670 patients treated by RFA, mortality was 0-5% and the complication rate 8-9% (73). A systemic review of randomised controlled trials for HCC treated with percutaneous ablation therapies, RFA demonstrated a significant improved 3-year survival as compared to patients treated with PEI (74). Predictors of treatment response are tumour size and morphology (well encapsulated versus invasive). While safe and in case of a complete response highly effective with a prolonged survival (75), RFA is associated with a high risk of tumor persistence in the targeted nodule (76). Therefore, except for very small HCCs (< 2cm) (77) in a curative setting RFA should not be considered as an independent HCC therapy but rather as a bridging strategy for LTx, for example.

Another non-invasive thermal HCC ablation is based on MRI-guided high intensity focused ultrasound (HIFU) (78). While there is relatively little experience with this technique to date, this method may eventually prove clinically useful, possibly in combination with a transarterial intervention (see below).

Interestingly, comparing percutaneous ablation and surgery, recent evidence suggests that RFA is as effective as resection for the treatment of small HCCs (77, 79). The combination of RFA with transarterial interventions is discussed below.

Taken together, percutaneous HCC ablation by PEI and/ or RFA is an effective treatment for patients with HCCs that prolongs tumor-free and overall survival, especially if surgery is not feasible. This strategy is now being evaluated also for the treatment of liver metastases (80).

4.4. Transarterial interventions

Transarterial embolization (TAE), chemoperfusion (TAC) and chemoembolization (TACE) are the most widely used treatments for HCCs that are unresectable or cannot be effectively treated by percutaneous interventions (81-84). Embolization agents may be administered alone (embolization) or after selective intra-arterial chemotherapy (generally doxorubicin, mitomycin or cisplatin) mixed with lipiodol (chemoembolization). Recent evidence further suggests that transarterial injection of drug eluting beads is also highly effective.

TAE or TACE results in partial responses in 15-55% of patients, delays tumour progression and vascular invasion and results in a survival benefit compared with conservative management. The most important aspect is the selection of patients, i.e., patients should have preserved liver function (Child A) and asymptomatic multinodular tumours without vascular invasion or extrahepatic spread (82, 85). In a prospective study in 8,510 patients the 5- and 7-year survival was 26% and 16%, respectively, the severity of the underlying liver disease, tumor stage, and AFP level being independent prognostic factors (86). In patients with advanced liver disease (Child B or C), however, treatment-induced liver failure may offset the anti-tumor effect or survival benefit of the intervention.

In a randomized controlled clinical study the combination of TACE and PEI/ RFA improved the survival of patients with HCC Okuda stage I, as compared to TACE alone (87-89). Further in a pilot study, intraarterial doxorubicin drug-eluting beads seem to enhance the effect of RFA (90).

In an adjuvant setting, postoperative TACE may improve survival in patients with risk factors for residual tumor (91).

A novel treatment concept is transarterial ethanol ablation (TEA) based on a lipiodol-ethanol mixture that contains 33% ethanol by volume and causes endothelial

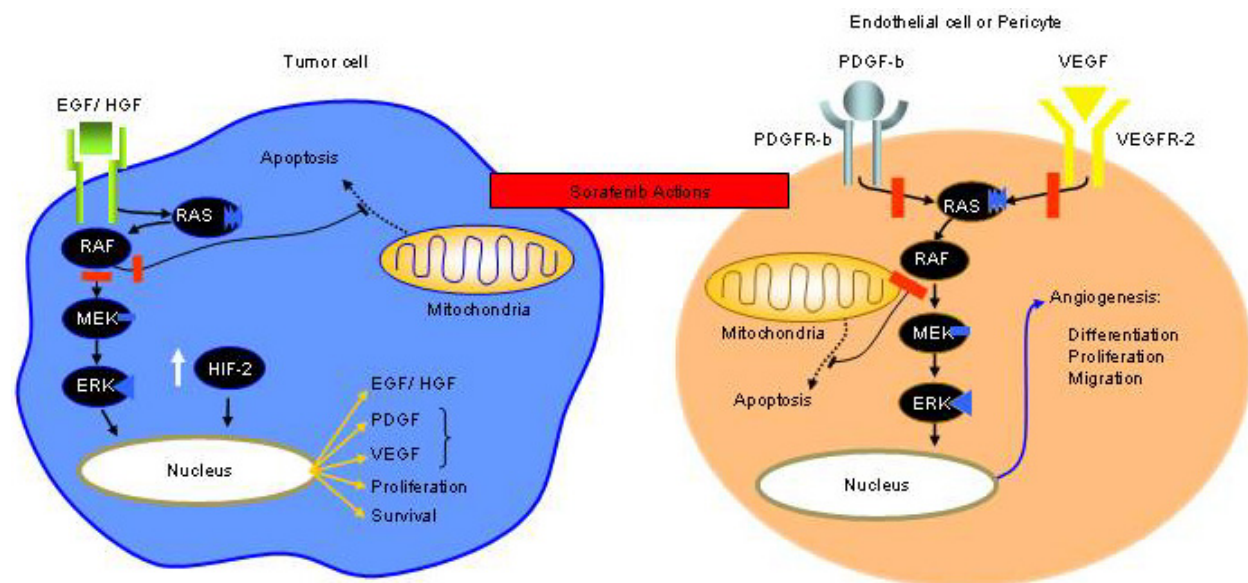


Figure 2. Action of tyrosine kinase inhibitors (according to (160))

damage and thrombosis of the arteriolar lumen of the tumor feeding vessels, resulting in tumor infarction. In a case-controlled study including 60 patients TEA was superior to TACE (92).

4.5. Drugs

To date sorafenib is the only drug that has been approved for the treatment of HCC. It is a multikinase inhibitor which effectively blocks the *raf* pathway, resulting in a block of apoptosis resistance, angiogenesis, proliferation and invasion/ metastasis (Figure 2). In a double-blind, randomized, placebo-controlled trial 800 mg sorafenib/ d or placebo was given to a total of 602 patients with liver cirrhosis Child A and advanced HCC. Sorafenib significantly prolonged overall survival (10.7 vs. 7.9 months) with acceptable toxicity (mainly diarrhea and hand-foot-syndrome) (93). While effective to some degree, it certainly can and should not be considered a routine therapy for advanced HCC, given the limited efficacy, severe side effects and high costs (94). Nevertheless, sorafenib is a benchmark drug with the perspective for further improvement of HCC treatment.

5. EVOLVING THERAPIES

5.1. Optimization of established therapies

Recently, in a pilot study a novel drug formulation based on drug eluting beads has been used for TACE and resulted in lower systemic drug levels and reduced toxicity (95).

5.2. Radiation therapy

While radiation therapy has played a minor role in the primary treatment of HCC to date, selective intra-arterial injection of ¹³¹I-iodine-labeled lipiodol has been performed in some patients (96) but needs further clinical

evaluation before a recommendation can be made. Further, high dose proton beam radiotherapy and external beam radiation as well as Yttrium-90 microsphere treatment, selective internal radiation therapy (SIRT), have been recently explored in clinical trials in patients with unresectable HCC (97-100), also with the intention to downstage the disease or bridge to transplantation (101). These strategies will certainly be further evaluated in clinical studies and may become a treatment option in the future.

5.3. Drugs

A number of systemic chemotherapies, hormones and other drugs (Table 2) have been evaluated in clinical trials (102-104). While most chemotherapeutic agents, tamoxifen (105), octreotide (106, 107) and interferon (81) have not been shown to be effective in randomized controlled clinical trials, there are a number of substances that may deserve further clinical evaluation, e.g., gemcitabine (108, 109), thymostimulin (110), α -1-thymosin (111), pravastatin (112), thalidomide (113), megestrol acetate (114), Cox-2 inhibitors (115) in combination with capecitabine, pamidronate (116) and others. Further, in an animal model, troglitazone resulted in an impressive reduction of HCC growth (117).

At present the most promising drugs are several small molecule tyrosine kinase inhibitors (nibs), e.g., sorafenib (see above), erlotinib, gefitinib (118) as well as monoclonal antibodies (mabs), e.g., bevacizumab or cetuximab and other drug classes, incl. the proteasome inhibitor bortezomib (Table 3) (119-122). While sorafenib has been approved for the treatment of HCC, given the limited efficacy, severe side effects and high costs, further agents alone or in combination with other novel or established strategies, e.g., RFA and/ or TACE are needed to offer a therapeutic option to the majority of patients with

Table 2. Drugs evaluated in patients with HCC

Chemotherapeutic Agents	
•	5-Fluorouracil
•	Capecitabine
•	Gemcitabine
•	Doxorubicin
•	Epirubicin
•	Etoposide
•	Cisplatin
•	Mitoxantrone
Hormones or Anti-Hormones	
•	Megestrol acetate
•	Tamoxifen
•	Octreotide
Tyrosine Kinase Inhibitors	
•	Bevacizumab
•	Cediranib
•	Cetuximab
•	Erlotinib
•	Gefitinib
•	Lapatinib
•	Sorafenib
•	Sunitinib
•	Vatalanib
Immune Modulators	
•	Interferon Alpha
•	Thymophysin
•	Alpha-1-Thymosin
Others	
•	Bortezomib
•	Cox-2-inhibitors
•	Everolimus
•	Pravastatin
•	Rapamycin
•	Troglitazone

Table 3. Targeted therapies and others in clinical HCC trials

Name	Target	Study	References
Gefitinib	EGF-R	phase II	(147)
Erlotinib	EGF-R	phase II	(148, 149)
Lapatinib	EGF-R	phase II	(150)
Cetuximab	EGF-R	phase II	(151, 152)
Bevacizumab	VEGF	phase I/II	(153, 154)
Sorafenib	c-Raf1, B-Raf,	phase III	(93)
	PDGF-R, VEGF-R		
Sunitinib	PDGF-R, VEGF-R,	phase II	(155, 156)
	c-KIT, FLT-3		
Vatalanib	PDGF-R, VEGF-R,	phase I	(157)
	c-KIT		
Cediranib	VEGF-R	phase II	(158)
Bortezomib	Proteasome	Phase I/II	(152, 159)

advanced HCC at the time of diagnosis. In this context several nibs and mabs are being evaluated in clinical trials (Table 3). In addition, in experimental preclinical models the mammalian target of rapamycin (mTOR) inhibitors, rapamycin and sirolimus, in combination with bevacizumab and doxorubicin, respectively, were shown to suppress HCC growth (123, 124). Interestingly, everolimus, another mTOR inhibitor, was shown to be effective in patients with metastatic renal cell carcinoma that had progressed on sunitinib/ sorafenib (125).

Apart from exploring novel therapeutic targets, individualization of therapy is of high clinical priority. Tumor-specific mutations/ gene signatures increasingly allow to predict the prognosis and response to therapy in the individual patient. For example, in patients with

colorectal cancer it has been recently been shown that cetuximab, is effective only if the tumor carries the ras wild-type gene (126). Thus, it should become possible also in patients with HCC to identify genetic markers that allow to predict whether a given drug will be effective. Genetic marker-based patient selection would improve the drug's overall efficacy and at the same time reduce side effects and costs.

5.4. Experimental strategies

In view of the limited therapeutic options for advanced HCCs a number of experimental strategies are being evaluated, incl. gene and immune therapies (Figure 3) based on suicide, cytokine and antiangiogenic genes or DNA vaccination with tumor-specific genes (127-131), oncolytic viruses (132, 133) as well as novel drugs, e. g., 3-

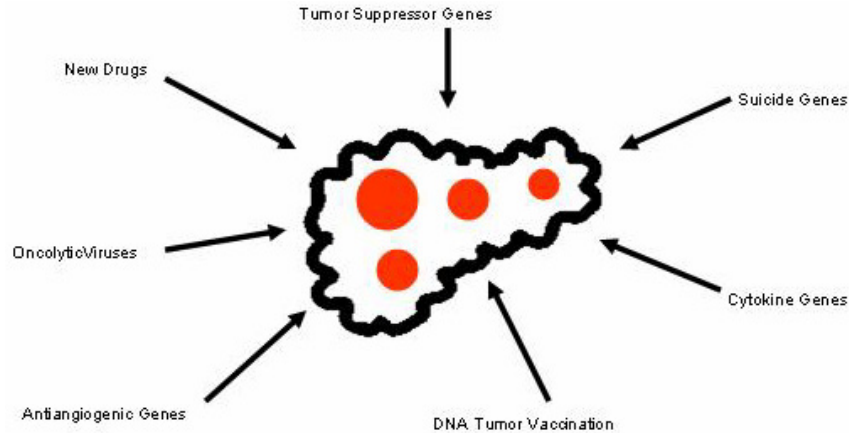


Figure 3. HCC: Experimental strategies.

bromopyruvate (134, 135).

6. HCC PREVENTION

HCC prevention falls into two categories. Primary prevention is aimed at the interference with HCC development at four stages (Figure 4). Stage 1: Interventions at this step are aimed at the prevention of acquired liver diseases. Apart from avoiding liver toxins, including alcohol and certain drugs, or infections with HBV or HCV by hygienic measures, avoiding parenteral exposure to blood, blood products or contaminated needles etc. a prime example is vaccination against HBV infection using the commercially available active and passive vaccines. Several HBV vaccines using natural or recombinant hepatitis B surface antigen (HBsAg) from different sources are well introduced in clinical practice and universal vaccination in Taiwan has indeed already resulted in a decline of the HCC incidence (136). For the prevention of HCV infection, however, there is no effective vaccine available to date. Stage 2: Interventions at this step are aimed at the early treatment of acute hepatitis, thereby blocking their transition into a chronic liver disease. Stage 3: Interventions at this step are aimed at the prevention of the progression of chronic hepatitis to liver cirrhosis that carries a high risk for HCC development. This includes the treatment of inherited, cholestatic or autoimmune liver diseases as well as the treatment of chronic viral hepatitis B or C. Reduction of iron overload by phlebotomy, for example, has been shown to stop the progression of hemochromatosis to liver cirrhosis and HCC. Stage 4: Interventions at this step are aimed at interfering with the molecular events leading to HCC development, usually in a cirrhotic liver. These strategies include all treatment modalities detailed above (stage 3) as far as they can be implemented in patients with compensated or decompensated liver cirrhosis. Finally, LTx in patients with liver cirrhosis before HCC development is a highly effective preventive measure.

After successful HCC resection or non-surgical ablation, HCC recurrence in the remaining, in most cases

cirrhotic liver is the major limitation of the life expectancy of these patients. The probability of recurrence is about 50% within 3 years after successful treatment (36, 137). Strategies to prevent HCC recurrence are therefore central to the improvement of survival of HCC patients after initial cure. Apart from LTx after successful resection (48), the strategies explored to date include the administration of polyprenic acid, an acyclic retinoid (138), of interferon alpha (139) and of interferon beta (140). Further, adoptive immunotherapy (141) and intraarterial injection of ¹³¹I-iodine-labeled lipiodol (142, 143) has been evaluated in clinical studies. Further, postoperative adjuvant TACE may also improve survival in patients with risk factors for residual tumor (91). All these interventions have resulted in lower HCC recurrence rates. These findings have to be confirmed, however, in larger randomized controlled studies demonstrating a clear clinical benefit before secondary prevention with one the strategies mentioned above should enter clinical practice.

In an animal model of chemical hepatocarcinogenesis using dimethylnitrosamine in which only males developed HCCs it has recently been shown that tumor development in males can be prevented by estrogens (144). The mechanism of action was mediated through inhibition of interleukin-6 synthesis in macrophages that was induced by hepatocellular necrosis. While these findings may in part explain the predominance of male patients with HCC, the data need to be reproduced and extended in order to demonstrate their clinical relevance with respect to a preventive strategy in patients with chronic liver diseases. Further, recent experimental data suggest that c-kit inhibition by imatinib mesylate attenuates progenitor cell expansion and prevents HCC formation in mice while it is not effective as a therapeutic agent (145, 146).

7. SUMMARY AND PERSPECTIVES

HCC is one of the most common malignant tumors in some areas of the world with an extremely poor prognosis. HCC treatment is based on randomized

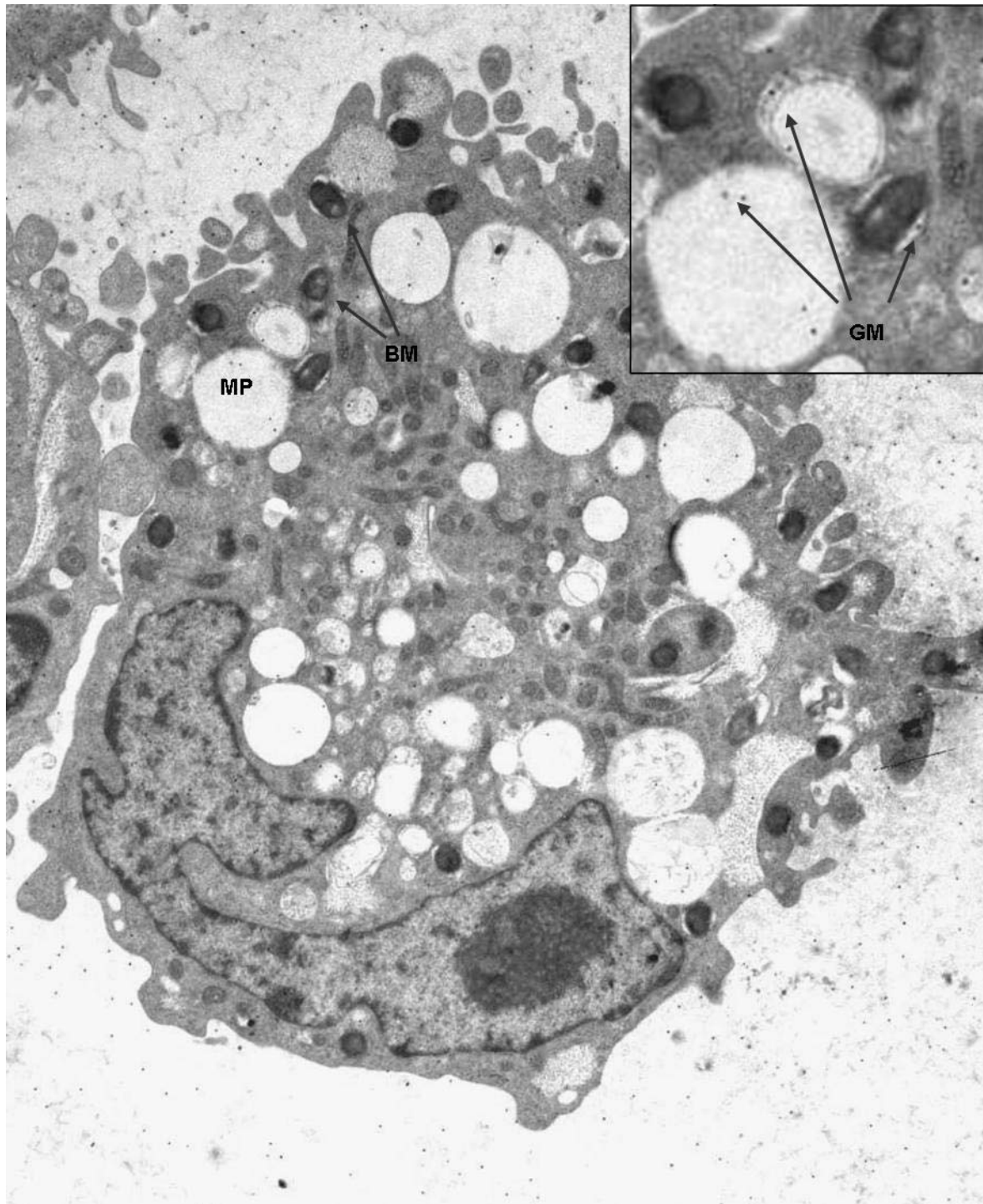


Figure 4. Primary HCC prevention. 1: prevention of liver disease, e.g., by hygienic measures, prevention of exposure or vaccination against HBV infection, abstinence from alcohol etc. 2: prevention of chronic hepatitis; e.g., by treatment of acute hepatitis C, abstinence from alcohol, treatment of hereditary liver diseases etc. 3: prevention of liver cirrhosis, e.g., by antiviral treatment of chronic hepatitis B or C, treatment of other chronic liver diseases. 4: prevention of HCC development in liver cirrhosis, e.g., by antiviral treatment, inhibition of fibrosis, liver transplantation, etc.

controlled trials and many observational studies. Treatment options fall into five main categories: (1) surgical interventions, incl. tumor resection and LTx, (2)

percutaneous interventions, incl. PEI and RFA, (3) transarterial interventions, incl. TAC, TAE and TACE as well as the combination of TACE and RFA and (4)

radiotherapy, incl. external radiation and SIRT and (5) drugs as well as gene and immune therapies. While surgery and percutaneous as well as transarterial interventions are effective in patients with limited disease (up to 3 lesions <3 cm in diameter or 1 lesion <5 cm in diameter) and compensated underlying liver disease (cirrhosis Child A), at the time of diagnosis more than 80% of the patients present with multicentric HCC and advanced liver disease or comorbidities that restrict the therapeutic measures to sorafenib or best supportive care.

In order to reduce morbidity and mortality from HCC, therefore, early diagnosis and the development of novel systemic therapies for advanced disease, incl. drugs, gene and immune therapies as well as primary HCC prevention are of paramount importance. Further, secondary HCC prevention after successful therapeutic interventions needs to be improved in order to make an impact on the survival of patients with HCC. New technologies, including gene expression profiling and proteomic analyses, should allow to further elucidate the molecular events underlying HCC development and to identify novel diagnostic markers as well as therapeutic and preventive targets.

8. REFERENCES

- Sherman M, A Klein, AASLD single-topic research conference on hepatocellular carcinoma: Conference proceedings. *Hepatology* 40, 1465-1473 (2004)
- Bruix J, M Sherman, Management of hepatocellular carcinoma. *Hepatology* 42, 1208-1236 (2005)
- Bosch FX, J Ribes, M Diaz, R Cleries, Primary liver cancer: worldwide incidence and trends. *Gastroenterology* 127, S5-S16 (2004)
- El-Serag HB, JA Davila, NJ Petersen, KA McGlynn, The continuing increase in the incidence of hepatocellular carcinoma in the United States: an update. *Ann Intern Med* 139, 817-823 (2003)
- Calle EE, C Rodriguez, K Walker-Thurmond, MJ Thun, Overweight, obesity, and mortality from cancer in a prospectively studied cohort of U.S. adults. *N Engl J Med* 348, 1625-1638 (2003)
- El-Serag HB, Hepatocellular carcinoma: recent trends in the United States. *Gastroenterology* 127, S27-34 (2004)
- Ozturk M, Genetic aspects of hepatocellular carcinogenesis. *Semin Liver Dis* 19, 235-242 (1999)
- Suriawinata A, R Xu, An update on the molecular genetics of hepatocellular carcinoma. *Semin Liver Dis* 24, 77-88 (2004)
- Satyanarayana A, MP Manns, KL Rudolph, Telomeres and telomerase: a dual role in hepatocarcinogenesis. *Hepatology* 40, 276-283 (2004)
- Brechot C, Pathogenesis of hepatitis B virus-related hepatocellular carcinoma: old and new paradigms. *Gastroenterology* 127, S56-61 (2004)
- Yu MC, JM Yuan, Environmental factors and risk for hepatocellular carcinoma. *Gastroenterology* 127, S72-78 (2004)
- Mishra L, T Banker, J Murray, S Byers, A Thenappan, AR He, K Shetty, L Johnson, EP Reddy, Liver stem cells and hepatocellular carcinoma. *Hepatology* 49, 318-329 (2009)
- Velazquez RF, M Rodriguez, CA Navascues, A Linares, R Perez, NG Sotorrios, I Martinez, L Rodrigo, Prospective analysis of risk factors for hepatocellular carcinoma in patients with liver cirrhosis. *Hepatology* 37, 520-527. (2003)
- Ming L, SS Thorgeirsson, MH Gail, P Lu, CC Harris, N Wang, Y Shao, Z Wu, G Liu, X Wang, Z Sun, Dominant role of hepatitis B virus and cofactor role of aflatoxin in hepatocarcinogenesis in Qidong, China. *Hepatology* 36, 1214-1220. (2002)
- Hassan MM, LY Hwang, CJ Hatten, M Swaim, D Li, JL Abbruzzese, P Beasley, YZ Patt, AS Zaghloul, HB El-Serag, O Soliman, CL Chappell, RP Beasley, Risk factors for hepatocellular carcinoma: synergism of alcohol with viral hepatitis and diabetes mellitus. *Hepatology* 36, 1206-1213. (2002)
- Ohata K, K Hamasaki, K Toriyama, K Matsumoto, A Saeki, K Yanagi, S Abiru, Y Nakagawa, M Shigeno, S Miyazoe, T Ichikawa, H Ishikawa, K Nakao, K Eguchi, Hepatic steatosis is a risk factor for hepatocellular carcinoma in patients with chronic hepatitis C virus infection. *Cancer* 97, 3036-3043 (2003)
- Morgan TR, S Mandayam, MM Jamal, Alcohol and hepatocellular carcinoma. *Gastroenterology* 127, S87-96 (2004)
- Marrero JA, RJ Fontana, S Fu, HS Conjeevaram, GL Su, AS Lok, Alcohol, tobacco and obesity are synergistic risk factors for hepatocellular carcinoma. *J Hepatol* 42, 218-224 (2005)
- El-Serag HB, T Tran, JE Everhart, Diabetes increases the risk of chronic liver disease and hepatocellular carcinoma. *Gastroenterology* 126, 460-468 (2004)
- Caldwell SH, DM Crespo, HS Kang, AM Al-Osaimi, Obesity and hepatocellular carcinoma. *Gastroenterology* 127, S97-103 (2004)
- Yano Y, F Yamashita, S Sumie, E Ando, K Fukumori, M Kiyama, T Oyama, S Kuroki, O Kato, H Yamamoto, M Tanaka, M Sata, Clinical features of hepatocellular carcinoma seronegative for both HBsAg and anti-HCV antibody but positive for anti-HBc antibody in Japan. *Am J Gastroenterol* 97, 156-161 (2002)

22. Pollicino T, G Squadrito, G Cerenzia, I Cacciola, G Raffa, A Crax, F Farinati, G Missale, A Smedile, C Tiribelli, E Villa, G Raimondo, Hepatitis B virus maintains its pro-oncogenic properties in the case of occult HBV infection. *Gastroenterology* 126, 102-110 (2004)
23. Bravi F, C Bosetti, A Tavani, V Bagnardi, S Gallus, E Negri, S Franceschi, C La Vecchia, Coffee drinking and hepatocellular carcinoma risk: a meta-analysis. *Hepatology* 46, 430-435 (2007)
24. Larsson SC, A Wolk, Coffee consumption and risk of liver cancer: a meta-analysis. *Gastroenterology* 132, 1740-1745 (2007)
25. Hu G, J Tuomilehto, E Pukkala, T Hakulinen, R Antikainen, E Vartiainen, P Jousilahti, Joint effects of coffee consumption and serum gamma-glutamyltransferase on the risk of liver cancer. *Hepatology* 48, 129-136 (2008)
26. Nakamoto Y, L Guidotti, C Kuhlen, P Fowler, F Chisari, Immune pathogenesis of hepatocellular carcinoma. *J Exp Med* 188, 341-350 (1998)
27. Nakamoto Y, S Kaneko, H Fan, T Momoi, H Tsutsui, K Nakanishi, K Kobayashi, T Suda, Prevention of hepatocellular carcinoma development associated with chronic hepatitis by anti-fas ligand antibody therapy. *J Exp Med* 196, 1105-1111. (2002)
28. Pikarsky E, RM Porat, I Stein, R Abramovitch, S Amit, S Kasem, E Gutkovich-Pyest, S Urieli-Shoval, E Galun, Y Ben-Neriah, NF-kappaB functions as a tumour promoter in inflammation-associated cancer. *Nature* 431, 461-466 (2004)
29. Balkwill F, LM Coussens, Cancer: an inflammatory link. *Nature* 431, 405-406 (2004)
30. Chen CJ, DS Chen, Interaction of hepatitis B virus, chemical carcinogen, and genetic susceptibility: multistage hepatocarcinogenesis with multifactorial etiology. *Hepatology* 36, 1046-1049. (2002)
31. Talwalkar JA, GJ Gores, Diagnosis and staging of hepatocellular carcinoma. *Gastroenterology* 127, S126-132 (2004)
32. Tateishi R, S Shiina, H Yoshida, T Teratani, S Obi, N Yamashiki, H Yoshida, M Akamatsu, T Kawabe, M Omata, Prediction of recurrence of hepatocellular carcinoma after curative ablation using three tumor markers. *Hepatology* 44, 1518-1527 (2006)
33. Di Bisceglie AM, Screening for hepatocellular carcinoma: being old is not all bad. *Am J Gastroenterol* 99, 1477-1478 (2004)
34. Okuda K, T Ohtsuki, H Obata, M Tomimatsu, N Okazaki, H Hasegawa, Y Nakajima, K Ohnishi, Natural history of hepatocellular carcinoma and prognosis in relation to treatment. Study of 850 patients. *Cancer* 56, 918-928 (1985)
35. Leung TW, AM Tang, B Zee, WY Lau, PB Lai, KL Leung, JT Lau, SC Yu, PJ Johnson, Construction of the Chinese University Prognostic Index for hepatocellular carcinoma and comparison with the TNM staging system, the Okuda staging system, and the Cancer of the Liver Italian Program staging system: a study based on 926 patients. *Cancer* 94, 1760-1769 (2002)
36. Llovet JM, C Bru, J Bruix, Prognosis of hepatocellular carcinoma: the BCLC staging classification. *Semin Liver Dis* 19, 329-338 (1999)
37. Farinati F, M Rinaldi, S Gianni, R Naccarato, How should patients with hepatocellular carcinoma be staged? Validation of a new prognostic system. *Cancer* 89, 2266-2273 (2000)
38. Kudo M, H Chung, S Haji, Y Osaki, H Oka, T Seki, H Kasugai, Y Sasaki, T Matsunaga, Validation of a new prognostic staging system for hepatocellular carcinoma: the JIS score compared with the CLIP score. *Hepatology* 40, 1396-1405 (2004)
39. Chevret S, JC Trinchet, D Mathieu, AA Rached, M Beaugrand, C Chastang, A new prognostic classification for predicting survival in patients with hepatocellular carcinoma. Groupe d'Etude et de Traitement du Carcinome Hepatocellulaire. *J Hepatol* 31, 133-141 (1999)
40. Marrero JA, RJ Fontana, A Barrat, F Askari, HS Conjeevaram, GL Su, AS Lok, Prognosis of hepatocellular carcinoma: comparison of 7 staging systems in an American cohort. *Hepatology* 41, 707-716 (2005)
41. Befeler AS, AM Di Bisceglie, Hepatocellular carcinoma: diagnosis and treatment. *Gastroenterology* 122, 1609-1619. (2002)
42. Sangiovanni A, E Del Ninno, P Fasani, C De Fazio, G Ronchi, R Romeo, A Morabito, R De Franchis, M Colombo, Increased survival of cirrhotic patients with a hepatocellular carcinoma detected during surveillance. *Gastroenterology* 126, 1005-1014 (2004)
43. El-Serag HB, AB Siegel, JA Davila, YH Shaib, M Cayton-Woody, R McBride, KA McGlynn, Treatment and outcomes of treating of hepatocellular carcinoma among Medicare recipients in the United States: A population-based study. *J Hepatol* 44, 158-166 (2006)
44. Song TJ, EW Ip, Y Fong, Hepatocellular carcinoma: current surgical management. *Gastroenterology* 127, S248-260 (2004)
45. Llovet JM, J Fuster, J Bruix, Intention-to-treat analysis of surgical treatment for early hepatocellular carcinoma: resection versus transplantation. *Hepatology* 30, 1434-1440 (1999)

46. Aii S, Y Yamaoka, S Futagawa, K Inoue, K Kobayashi, M Kojiro, M Makuuchi, Y Nakamura, K Okita, R Yamada, Results of surgical and nonsurgical treatment for small-sized hepatocellular carcinomas: a retrospective and nationwide survey in Japan. The Liver Cancer Study Group of Japan. *Hepatology* 32, 1224-1229 (2000)
47. Kubo S, Neuer Marker für Leberversagen nach Resektion. *Ann Surg* 239, 186-193 (2004)
48. Sala M, J Fuster, JM Llovet, M Navasa, M Sole, M Varela, F Pons, A Rimola, JC Garcia-Valdecasas, C Bru, J Bruix, High pathological risk of recurrence after surgical resection for hepatocellular carcinoma: an indication for salvage liver transplantation. *Liver Transpl* 10, 1294-1300 (2004)
49. Wiesner RH, RB Freeman, DC Mulligan, Liver transplantation for hepatocellular cancer: the impact of the MELD allocation policy. *Gastroenterology* 127, S261-267 (2004)
50. Schwartz M, Liver transplantation for hepatocellular carcinoma. *Gastroenterology* 127, S268-276 (2004)
51. Kulik L, M Abecassis, Living donor liver transplantation for hepatocellular carcinoma. *Gastroenterology* 127, S277-282 (2004)
52. Leung JY, AX Zhu, FD Gordon, DS Pratt, A Mithoefer, K Garrigan, A Terella, M Hertl, AB Cosimi, RT Chung, Liver transplantation outcomes for early-stage hepatocellular carcinoma: results of a multicenter study. *Liver Transpl* 10, 1343-1354 (2004)
53. Andriulli A, I de Sio, L Solmi, L De Carlis, R Troisi, A Grasso, V Festa, E Caturelli, A Giacomoni, C Del Vecchio Blanco, B De Hemptinne, A Burroughs, F Perri, Survival of cirrhotic patients with early hepatocellular carcinoma treated by percutaneous ethanol injection or liver transplantation. *Liver Transpl* 10, 1355-1363 (2004)
54. Mazzaferro V, E Regalia, R Doci, S Andreola, A Pulvirenti, F Bozzetti, F Montalto, M Ammatuna, A Morabito, L Gennari, Liver transplantation for the treatment of small hepatocellular carcinomas in patients with cirrhosis. *N Engl J Med* 334, 693-699. (1996)
55. Shetty K, K Timmins, C Brensinger, EE Furth, S Rattan, W Sun, M Rosen, M Soulen, A Shaked, KR Reddy, KM Olthoff, Liver transplantation for hepatocellular carcinoma validation of present selection criteria in predicting outcome. *Liver Transpl* 10, 911-918 (2004)
56. Sala M, M Varela, J Bruix, Selection of candidates with HCC for transplantation in the MELD era. *Liver Transpl* 10, S4-9 (2004)
57. Lee JS, IS Chu, J Heo, DF Calvisi, Z Sun, T Roskams, A Durnez, AJ Demetris, SS Thorgeirsson, Classification and prediction of survival in hepatocellular carcinoma by gene expression profiling. *Hepatology* 40, 667-676 (2004)
58. Locker J, A new way to look at liver cancer. *Hepatology* 40, 521-523 (2004)
59. Graziadei IW, H Sandmueller, P Waldenberger, A Koenigsrainer, K Nachbaur, W Jaschke, R Margreiter, W Vogel, Chemoembolization followed by liver transplantation for hepatocellular carcinoma impedes tumor progression while on the waiting list and leads to excellent outcome. *Liver Transpl* 9, 557-563 (2003)
60. Cronin DC, 2nd, JM Millis, M Siegler, Transplantation of liver grafts from living donors into adults--too much, too soon. *N Engl J Med* 344, 1633-1637 (2001)
61. Trotter JF, M Wachs, GT Everson, I Kam, Adult-to-adult transplantation of the right hepatic lobe from a living donor. *N Engl J Med* 346, 1074-1082 (2002)
62. Lo CM, ST Fan, CL Liu, SC Chan, J Wong, The role and limitation of living donor liver transplantation for hepatocellular carcinoma. *Liver Transpl* 10, 440-447 (2004)
63. Livraghi T, F Meloni, A Morabito, C Vettori, Multimodal image-guided tailored therapy of early and intermediate hepatocellular carcinoma: long-term survival in the experience of a single radiologic referral center. *Liver Transpl* 10, S98-106 (2004)
64. Omata M, R Tateishi, H Yoshida, S Shiina, Treatment of hepatocellular carcinoma by percutaneous tumor ablation methods: Ethanol injection therapy and radiofrequency ablation. *Gastroenterology* 127, S159-166 (2004)
65. Head HW, GD Dodd, 3rd, Thermal ablation for hepatocellular carcinoma. *Gastroenterology* 127, S167-178 (2004)
66. Livraghi T, A Giorgio, G Marin, A Salmi, I de Sio, L Bolondi, M Pompili, F Brunello, S Lazzaroni, G Torzilli, Hepatocellular carcinoma and cirrhosis in 746 patients: long-term results of percutaneous ethanol injection. *Radiology* 197, 101-108 (1995)
67. Lencioni R, F Pinto, N Armillotta, AM Bassi, M Moretti, M Di Giulio, S Marchi, M Uliana, S Della Capanna, M Lencioni, C Bartolozzi, Long-term results of percutaneous ethanol injection therapy for hepatocellular carcinoma in cirrhosis: a European experience. *Eur Radiol* 7, 514-519 (1997)
68. Ebara M, S Okabe, K Kita, N Sugiura, H Fukuda, M Yoshikawa, F Kondo, H Saisho, Percutaneous ethanol injection for small hepatocellular carcinoma: therapeutic efficacy based on 20-year observation. *J Hepatol* 43, 458-464 (2005)
69. Sala M, JM Llovet, R Vilana, L Bianchi, M Sole, C Ayuso, C Bru, J Bruix, Initial response to percutaneous ablation predicts survival in patients with hepatocellular carcinoma. *Hepatology* 40, 1352-1360 (2004)

70. Buscarini L, E Buscarini, M Di Stasi, D Vallisa, P Quaretti, A Rocca, Percutaneous radiofrequency ablation of small hepatocellular carcinoma: long-term results. *Eur Radiol* 11, 914-921 (2001)
71. Lencioni RA, HP Allgaier, D Cioni, M Olschewski, P Deibert, L Crocetti, H Frings, J Laubenberger, I Zuber, HE Blum, C Bartolozzi, Small hepatocellular carcinoma in cirrhosis: randomized comparison of radio-frequency thermal ablation versus percutaneous ethanol injection. *Radiology* 228, 235-240 (2003)
72. Teratani T, H Yoshida, S Shiina, S Obi, S Sato, R Tateishi, N Mine, Y Kondo, T Kawabe, M Omata, Radiofrequency ablation for hepatocellular carcinoma in so-called high-risk locations. *Hepatology* 43, 1101-1108 (2006)
73. Mulier S, P Mulier, Y Ni, Y Miao, B Dupas, G Marchal, I De Wever, L Michel, Complications of radiofrequency coagulation of liver tumours. *Br J Surg* 89, 1206-1222 (2002)
74. Cho YK, JK Kim, MY Kim, H Rhim, JK Han, Systematic review of randomized trials for hepatocellular carcinoma treated with percutaneous ablation therapies. *Hepatology* 49, 453-459 (2009)
75. Camma C, V Di Marco, A Orlando, L Sandonato, A Casaril, P Parisi, S Alizzi, E Sciarrino, R Virdone, S Pardo, D Di Bona, A Licata, F Latteri, G Cabibbo, G Montalto, MA Latteri, N Nicoli, A Craxi, Treatment of hepatocellular carcinoma in compensated cirrhosis with radio-frequency thermal ablation (RFTA): a prospective study. *J Hepatol* 42, 535-540 (2005)
76. Mazzaferro V, C Battiston, S Perrone, A Pulvirenti, E Regalia, R Romito, D Sarli, M Schiavo, F Garbagnati, A Marchiano, C Spreafico, T Camerini, L Mariani, R Miceli, S Andreola, Radiofrequency ablation of small hepatocellular carcinoma in cirrhotic patients awaiting liver transplantation: a prospective study. *Ann Surg* 240, 900-909 (2004)
77. Livraghi T, F Meloni, M Di Stasi, E Rolle, L Solbiati, C Tinelli, S Rossi, Sustained complete response and complications rates after radiofrequency ablation of very early hepatocellular carcinoma in cirrhosis: Is resection still the treatment of choice? *Hepatology* 47, 82-89 (2008)
78. Jolesz FA, K Hynynen, N McDannold, D Freundlich, D Kopelman, Noninvasive thermal ablation of hepatocellular carcinoma by using magnetic resonance imaging-guided focused ultrasound. *Gastroenterology* 127, S242-247 (2004)
79. Liang HH, MS Chen, ZW Peng, YJ Zhang, YQ Zhang, JQ Li, WY Lau, Percutaneous radiofrequency ablation versus repeat hepatectomy for recurrent hepatocellular carcinoma: a retrospective study. *Ann Surg Oncol* 15, 3484-3493 (2008)
80. Livraghi T, L Solbiati, F Meloni, T Ierace, SN Goldberg, GS Gazelle, Percutaneous radiofrequency ablation of liver metastases in potential candidates for resection: the "test-of-time approach". *Cancer* 97, 3027-3035 (2003)
81. Lo CM, H Ngan, WK Tso, CL Liu, CM Lam, RT Poon, ST Fan, J Wong, Randomized controlled trial of transarterial lipiodol chemoembolization for unresectable hepatocellular carcinoma. *Hepatology* 35, 1164-1171. (2002)
82. Llovet JM, MI Real, X Montana, R Planas, S Coll, J Aponte, C Ayuso, M Sala, J Muchart, R Sola, J Rodes, J Bruix, Arterial embolisation or chemoembolisation versus symptomatic treatment in patients with unresectable hepatocellular carcinoma: a randomised controlled trial. *Lancet* 359, 1734-1739 (2002)
83. Llovet JM, J Bruix, Systematic review of randomized trials for unresectable hepatocellular carcinoma: Chemoembolization improves survival. *Hepatology* 37, 429-442. (2003)
84. Bruix J, M Sala, JM Llovet, Chemoembolization for hepatocellular carcinoma. *Gastroenterology* 127, S179-188 (2004)
85. Llovet JM, J Bruix, Unresectable hepatocellular carcinoma: meta-analysis of arterial embolization. *Radiology* 230, 300-301; author reply 301-302 (2004)
86. Takayasu K, S Arii, I Ikai, M Omata, K Okita, T Ichida, Y Matsuyama, Y Nakanuma, M Kojiro, M Makuuchi, Y Yamaoka, Prospective cohort study of transarterial chemoembolization for unresectable hepatocellular carcinoma in 8510 patients. *Gastroenterology* 131, 461-469 (2006)
87. Becker G, T Soezgen, M Olschewski, J Laubenberger, HE Blum, HP Allgaier, Combined TACE and PEI for palliative treatment of unresectable hepatocellular carcinoma. *World J Gastroenterol* 11, 6104-6109 (2005)
88. Cheng BQ, CQ Jia, CT Liu, W Fan, QL Wang, ZL Zhang, CH Yi, Chemoembolization combined with radiofrequency ablation for patients with hepatocellular carcinoma larger than 3 cm: a randomized controlled trial. *Jama* 299, 1669-1677 (2008)
89. Takaki H, K Yamakado, J Uraki, A Nakatsuka, H Fuke, N Yamamoto, K Shiraki, T Yamada, K Takeda, Radiofrequency ablation combined with chemoembolization for the treatment of hepatocellular carcinomas larger than 5 cm. *J Vasc Interv Radiol* 20, 217-224 (2009)
90. Lencioni R, L Crocetti, P Petruzzi, C Vignali, E Bozzi, C Della Pina, I Bargellini, D Cioni, F Oliveri, P De Simone, C Bartolozzi, M Brunetto, F Filipponi, Doxorubicin-eluting bead-enhanced radiofrequency

ablation of hepatocellular carcinoma: A pilot clinical study. *J Hepatol* 49, 217-222 (2008)

91. Ren ZG, ZY Lin, JL Xia, SL Ye, ZC Ma, QH Ye, LX Qin, ZQ Wu, J Fan, ZY Tang. Postoperative adjuvant arterial chemoembolization improves survival of hepatocellular carcinoma patients with risk factors for residual tumor: a retrospective control study. *World J Gastroenterol* 10, 2791-2794 (2004)

92. Yu SC, JW Hui, EP Hui, F Mo, PS Lee, J Wong, KF Lee, PB Lai, W Yeo. Embolization efficacy and treatment effectiveness of transarterial therapy for unresectable hepatocellular carcinoma: a case-controlled comparison of transarterial ethanol ablation with lipiodol-ethanol mixture versus transcatheter arterial chemoembolization. *J Vasc Interv Radiol* 20, 352-359 (2009)

93. Llovet JM, S Ricci, V Mazzaferro, P Hilgard, E Gane, JF Blanc, AC de Oliveira, A Santoro, JL Raoul, A Forner, M Schwartz, C Porta, S Zeuzem, L Bolondi, TF Greten, PR Galle, JF Seitz, I Borbath, D Haussinger, T Giannaris, M Shan, M Moscovici, D Voliotis, J Bruix, Sorafenib in advanced hepatocellular carcinoma. *N Engl J Med* 359, 378-390 (2008)

94. Roberts LR, Sorafenib in liver cancer--just the beginning. *N Engl J Med* 359, 420-422 (2008)

95. Varela M, MI Real, M Burrel, A Forner, M Sala, M Brunet, C Ayuso, L Castells, X Montana, JM Llovet, J Bruix, Chemoembolization of hepatocellular carcinoma with drug eluting beads: efficacy and doxorubicin pharmacokinetics. *J Hepatol* 46, 474-481 (2007)

96. Risse JH, F Grunwald, W Kersjes, H Strunk, WH Caselmann, H Palmedo, H Bender, HJ Biersack, Intraarterial HCC therapy with I-131-Lipiodol. *Cancer Biother Radiopharm* 15, 65-70 (2000)

97. Bush DA, DJ Hillebrand, JM Slater, JD Slater, High-dose proton beam radiotherapy of hepatocellular carcinoma: preliminary results of a phase II trial. *Gastroenterology* 127, S189-193 (2004)

98. Fuss M, BJ Salter, TS Herman, CR Thomas, Jr., External beam radiation therapy for hepatocellular carcinoma: potential of intensity-modulated and image-guided radiation therapy. *Gastroenterology* 127, S206-217 (2004)

99. Geschwind JF, R Salem, BI Carr, MC Soulen, KG Thurston, KA Goin, M Van Buskirk, CA Roberts, JE Goin, Yttrium-90 microspheres for the treatment of hepatocellular carcinoma. *Gastroenterology* 127, S194-205 (2004)

100. Kulik LM, BI Carr, MF Mulcahy, RJ Lewandowski, B Atassi, RK Ryu, KT Sato, A Benson, 3rd, AA Nemcek, Jr., VL Gates, M Abecassis, RA Omary, R Salem, Safety and efficacy of 90Y radiotherapy for hepatocellular carcinoma with and without portal vein thrombosis. *Hepatology* 47, 71-81 (2008)

101. Kulik LM, B Atassi, L van Holsbeeck, T Souman, RJ Lewandowski, MF Mulcahy, RD Hunter, AA Nemcek, Jr., MM Abecassis, KG Haines, 3rd, R Salem, Yttrium-90 microspheres (TheraSphere) treatment of unresectable hepatocellular carcinoma: downstaging to resection, RFA and bridge to transplantation. *J Surg Oncol* 94, 572-586 (2006)

102. Simonetti RG, A Liberati, C Angiolini, L Pagliaro, Treatment of hepatocellular carcinoma: a systematic review of randomized controlled trials. *Ann Oncol* 8, 117-136 (1997)

103. Mathurin P, O Rixe, N Carbonell, B Bernard, P Cluzel, MF Bellin, D Khayat, P Opolon, T Poynard, Review article: Overview of medical treatments in unresectable hepatocellular carcinoma--an impossible meta-analysis? *Aliment Pharmacol Ther* 12, 111-126 (1998)

104. Schwartz JD, M Schwartz, J Mandeli, M Sung, Neoadjuvant and adjuvant therapy for resectable hepatocellular carcinoma: review of the randomised clinical trials. *Lancet Oncol* 3, 593-603 (2002)

105. Chow PK, BC Tai, CK Tan, D Machin, KM Win, PJ Johnson, KC Soo, High-dose tamoxifen in the treatment of inoperable hepatocellular carcinoma: A multicenter randomized controlled trial. *Hepatology* 36, 1221-1226. (2002)

106. Yuen MF, RT Poon, CL Lai, ST Fan, CM Lo, KW Wong, WM Wong, BC Wong, A randomized placebo-controlled study of long-acting octreotide for the treatment of advanced hepatocellular carcinoma. *Hepatology* 36, 687-691. (2002)

107. Becker G, HP Allgaier, M Olschewski, A Zahringer, HE Blum, Long-acting octreotide versus placebo for treatment of advanced HCC: a randomized controlled double-blind study. *Hepatology* 45, 9-15 (2007)

108. Yang TS, YC Lin, JS Chen, HM Wang, CH Wang, Phase II study of gemcitabine in patients with advanced hepatocellular carcinoma. *Cancer* 89, 750-756. (2000)

109. Kubicka S, KL Rudolph, MK Tietze, M Lorenz, M Manns, Phase II study of systemic gemcitabine chemotherapy for advanced unresectable hepatobiliary carcinomas. *Hepatogastroenterology* 48, 783-789. (2001)

110. Palmieri G, E Biondi, A Morabito, A Rea, A Gravina, BA R., Thymostimulin treatment of hepatocellular carcinoma on liver cirrhosis. *Int. J. Oncol.* 8, 827-832 (1996)

111. Stefanini GF, FG Foschi, E Castelli, L Marsigli, M Biselli, F Mucci, M Bernardi, DH Van Thiel, G Gasbarrini, Alpha-1-thymosin and transcatheter arterial chemoembolization in hepatocellular carcinoma patients: a preliminary experience. *Hepatogastroenterology* 45, 209-215 (1998)

112. Kawata S, E Yamasaki, T Nagase, Y Inui, N Ito, Y Matsuda, M Inada, S Tamura, S Noda, Y Imai, Y Matsuzawa, Effect of pravastatin on survival in patients with advanced hepatocellular carcinoma. A randomized controlled trial. *Br J Cancer* 84, 886-891. (2001)
113. Hsu C, CN Chen, LT Chen, CY Wu, PM Yang, MY Lai, PH Lee, AL Cheng, Low-dose thalidomide treatment for advanced hepatocellular carcinoma. *Oncology* 65, 242-249 (2003)
114. Villa E, I Ferretti, A Grottola, P Buttafoco, MG Buono, F Giannini, M Manno, H Bertani, A Dugani, F Manenti, Hormonal therapy with megestrol in inoperable hepatocellular carcinoma characterized by variant oestrogen receptors. *Br J Cancer* 84, 881-885. (2001)
115. Kern MA, MM Schoneweiss, D Sahi, M Bahlo, AM Haugg, HU Kasper, HP Dienes, H Kaferstein, K Breuhahn, P Schirmacher, Cyclooxygenase-2 inhibitors suppress the growth of human hepatocellular carcinoma implants in nude mice. *Carcinogenesis* 25, 1193-1199 (2004)
116. Wada A, K Fukui, Y Sawai, K Imanaka, S Kiso, S Tamura, I Shimomura, N Hayashi, Pamidronate induced anti-proliferative, apoptotic, and anti-migratory effects in hepatocellular carcinoma. *J Hepatol* 44, 142-150 (2006)
117. Yu J, L Qiao, L Zimmermann, MP Ebert, H Zhang, W Lin, C Rocken, P Malfertheiner, GC Farrell, Troglitazone inhibits tumor growth in hepatocellular carcinoma in vitro and in vivo. *Hepatology* 43, 134-143 (2006)
118. Schiffer E, C Housset, W Cacheux, D Wendum, C Desbois-Mouthon, C Rey, F Clergue, R Poupon, V Barbu, O Rosmorduc, Gefitinib, an EGFR inhibitor, prevents hepatocellular carcinoma development in the rat liver with cirrhosis. *Hepatology* 41, 307-314 (2005)
119. Newell P, A Villanueva, JM Llovet, Molecular targeted therapies in hepatocellular carcinoma: from pre-clinical models to clinical trials. *J Hepatol* 49, 1-5 (2008)
120. Llovet JM, J Bruix, Novel advancements in the management of hepatocellular carcinoma in 2008. *J Hepatol* 48 Suppl 1, S20-37 (2008)
121. Greten TF, F Korangy, MP Manns, NP Malek, Molecular therapy for the treatment of hepatocellular carcinoma. *Br J Cancer* 100, 19-23 (2009)
122. Tanaka S, S Arai, Molecularly targeted therapy for hepatocellular carcinoma. *Cancer Sci* 100, 1-8 (2009)
123. Huynh H, PK Chow, N Palanisamy, M Salto-Tellez, BC Goh, CK Lee, A Somani, HS Lee, R Kalpana, K Yu, PH Tan, J Wu, R Soong, MH Lee, H Hor, KC Soo, HC Toh, P Tan, Bevacizumab and rapamycin induce growth suppression in mouse models of hepatocellular carcinoma. *J Hepatol* 49, 52-60 (2008)
124. Piguat AC, D Semela, A Keogh, L Wilkens, D Stroka, C Stoupis, MV St-Pierre, JF Dufour, Inhibition of mTOR in combination with doxorubicin in an experimental model of hepatocellular carcinoma. *J Hepatol* 49, 78-87 (2008)
125. Motzer RJ, B Escudier, S Oudard, TE Hutson, C Porta, S Bracarda, V Grunwald, JA Thompson, RA Figlin, N Hollaender, G Urbanowitz, WJ Berg, A Kay, D Lebwohl, A Ravaud, Efficacy of everolimus in advanced renal cell carcinoma: a double-blind, randomised, placebo-controlled phase III trial. *Lancet* 372, 449-456 (2008)
126. Di Fiore F, E Van Cutsem, P Laurent-Puig, S Siena, M Frattini, W De Roock, A Lièvre, A Sartore-Bianchi, A Bardelli, S- Tejpar, Role of KRAS mutation in predicting response, progression-free survival, and overall survival in irinotecan-refractory patients treated with cetuximab plus irinotecan for a metastatic colorectal cancer: Analysis of 281 individual data from published series. *J Clin Oncol* 26, A4035 (2008)
127. Mohr L, M Geissler, HE Blum, Gene therapy for malignant liver disease. *Expert Opin Biol Ther* 2, 163-175. (2002)
128. Mohr L, A Yeung, C Aloman, D Wittrup, JR Wands, Antibody-directed therapy for human hepatocellular carcinoma. *Gastroenterology* 127, S225-231 (2004)
129. Geissler M, L Mohr, MY Ali, CF Grimm, M Ritter, HE Blum, Immunobiology and gene-based immunotherapy of hepatocellular carcinoma. *Z Gastroenterol* 41, 1101-1110. (2003)
130. Butterfield LH, Immunotherapeutic strategies for hepatocellular carcinoma. *Gastroenterology* 127, S232-241 (2004)
131. Stefani AL, L Barzon, I Castagliuolo, M Guido, M Pacenti, C Parolin, F Farinati, G Palu, Systemic efficacy of combined suicide/cytokine gene therapy in a murine model of hepatocellular carcinoma. *J Hepatol* 42, 728-735 (2005)
132. Pei Z, L Chu, W Zou, Z Zhang, S Qiu, R Qi, J Gu, C Qian, X Liu, An oncolytic adenoviral vector of Smac increases antitumor activity of TRAIL against HCC in human cells and in mice. *Hepatology* 39, 1371-1381 (2004)
133. Shinozaki K, O Ebert, SL Woo, Eradication of advanced hepatocellular carcinoma in rats via repeated hepatic arterial infusions of recombinant VSV. *Hepatology* 41, 196-203 (2005)
134. Geschwind JF, YH Ko, MS Torbenson, C Magee, PL Pedersen, Novel therapy for liver cancer: direct intraarterial

injection of a potent inhibitor of ATP production. *Cancer Res* 62, 3909-3913 (2002)

135. Ko YH, BL Smith, Y Wang, MG Pomper, DA Rini, MS Torbenson, J Hullihen, PL Pedersen, Advanced cancers: eradication in all cases using 3-bromopyruvate therapy to deplete ATP. *Biochem Biophys Res Commun* 324, 269-275 (2004)

136. Chang MH, CJ Chen, MS Lai, HM Hsu, TC Wu, MS Kong, DC Liang, WY Shau, DS Chen, Universal hepatitis B vaccination in Taiwan and the incidence of hepatocellular carcinoma in children. Taiwan Childhood Hepatoma Study Group [see comments]. *N Engl J Med* 336, 1855-1859 (1997)

137. Koike Y, Y Shiratori, S Sato, S Obi, T Teratani, M Imamura, K Hamamura, Y Imai, H Yoshida, S Shiina, M Omata, Risk factors for recurring hepatocellular carcinoma differ according to infected hepatitis virus-an analysis of 236 consecutive patients with a single lesion. *Hepatology* 32, 1216-1223. (2000)

138. Muto Y, H Moriwaki, M Ninomiya, S Adachi, A Saito, KT Takasaki, T Tanaka, K Tsurumi, M Okuno, E Tomita, T Nakamura, T Kojima, Prevention of second primary tumors by an acyclic retinoid, polyphenolic acid, in patients with hepatocellular carcinoma. Hepatoma Prevention Study Group. *N Engl J Med* 334, 1561-1567 (1996)

139. Kubo S, S Nishiguchi, K Hirohashi, H Tanaka, T Shuto, O Yamazaki, S Shiomi, A Tamori, H Oka, S Igawa, T Kuroki, H Kinoshita, Effects of long-term postoperative interferon-alpha therapy on intrahepatic recurrence after resection of hepatitis C virus-related hepatocellular carcinoma. A randomized, controlled trial. *Ann Intern Med* 134, 963-967. (2001)

140. Ikeda K, Y Arase, S Saitoh, M Kobayashi, Y Suzuki, F Suzuki, A Tsubota, K Chayama, N Murashima, H Kumada, Interferon beta prevents recurrence of hepatocellular carcinoma after complete resection or ablation of the primary tumor-A prospective randomized study of hepatitis C virus-related liver cancer. *Hepatology* 32, 228-232 (2000)

141. Takayama T, T Sekine, M Makuuchi, S Yamasaki, T Kosuge, J Yamamoto, K Shimada, M Sakamoto, S Hirohashi, Y Ohashi, T Kakizoe, Adoptive immunotherapy to lower postsurgical recurrence rates of hepatocellular carcinoma: a randomised trial. *Lancet* 356, 802-807 (2000)

142. Lau WY, TW Leung, SK Ho, M Chan, D Machin, J Lau, AT Chan, W Yeo, TS Mok, SC Yu, NW Leung, PJ Johnson, Adjuvant intra-arterial iodine-131-labelled lipiodol for resectable hepatocellular carcinoma: a prospective randomised trial. *Lancet* 353, 797-801 (1999)

143. Boucher E, S Corbinais, Y Rolland, P Bourguet, D Guyader, K Boudjema, B Meunier, JL Raoul, Adjuvant intra-arterial injection of iodine-131-labeled lipiodol after

resection of hepatocellular carcinoma. *Hepatology* 38, 1237-1241 (2003)

144. Naugler WE, T Sakurai, S Kim, S Maeda, K Kim, AM Elsharkawy, M Karin, Gender disparity in liver cancer due to sex differences in MyD88-dependent IL-6 production. *Science* 317, 121-124 (2007)

145. Knight B, JE Tirmitz-Parker, JK Olynyk, C-kit inhibition by imatinib mesylate attenuates progenitor cell expansion and inhibits liver tumor formation in mice. *Gastroenterology* 135, 969-979 (2008)

146. Siegel A, Moving targets in hepatocellular carcinoma: hepatic progenitor cells as novel targets for tyrosine kinase inhibitors. *Gastroenterology* 135, 733-735 (2008)

147. O'Dwyer PJ, BJ Giantonio, DE Levy, JS Kauh, DB Fitzgerald, ABI Benson, Gefitinib in advanced unresectable hepatocellular carcinoma: results from the Eastern Cooperative Oncology Groups's study E1203. *J Clin Oncol* 24, A4143 (2006)

148. Philip PA, MR Mahoney, C Allmer, J Thomas, HC Pitot, G Kim, RC Donehower, T Fitch, J Picus, C Erlichman, Phase II study of Erlotinib (OSI-774) in patients with advanced hepatocellular cancer. *J Clin Oncol* 23, 6657-6663 (2005)

149. Thomas MB, R Chadha, K Glover, X Wang, J Morris, T Brown, A Rashid, J Dancey, JL Abbruzzese, Phase 2 study of erlotinib in patients with unresectable hepatocellular carcinoma. *Cancer* 110, 1059-1067 (2007)

150. Ramanathan RK, CP Belani, DA Singh, Phase II study of lapatinib, a dual inhibitor of epidermal growth factor receptor tyrosine kinase 1 and 2 (Her2/Neu) in patients with advanced biliary tree cancer or hepatocellular carcinoma. *J Clin Oncol* 24, A4010 (2006)

151. Gruenewald V, L Wilkens, M Gebel, A phase II open-label study of cetuximab in unresectable hepatocellular carcinoma: final results. *J Clin Oncol* 25, A4594 (2007)

152. Zhu AX, K Stuart, LS Blaszkowsky, A Muzikansky, DP Reitberg, JW Clark, PC Enzinger, P Bhargava, JA Meyerhardt, K Horgan, CS Fuchs, DP Ryan, Phase 2 study of cetuximab in patients with advanced hepatocellular carcinoma. *Cancer* 110, 581-589 (2007)

153. Siegel AB, EI Cohen, A Ocean, D Lehrer, A Goldenberg, JJ Knox, H Chen, S Clark-Garvey, A Weinberg, J Mandeli, P Christos, M Mazumdar, E Popa, RS Brown, Jr., S Rafii, JD Schwartz, Phase II trial evaluating the clinical and biologic effects of bevacizumab in unresectable hepatocellular carcinoma. *J Clin Oncol* 26, 2992-2998 (2008)

154. Malka D, C Dromain, F Farace, D Horn, J Pignon, M Ducreux, V Boige, Bevacizumab in patients with advanced hepatocellular carcinoma: preliminary results of a phase II

study with circulating endothelial cell monitoring. *J Clin Oncol* 25, 4570 (2007)

155. Faivre S, E Ramiond, J Douillard, Assessment of safety and drug-induced tumor necrosis with sunitinib in patients with unresectable HCC. *J Clin Oncol* 25, A4637 (2007)

156. Zhu AX, D Sahani, E di Tomasi, A phase II study of sunitinib in patients with advanced HCC. *J Clin Oncol* 25, A4637 (2007)

157. Koch I, A Baron, S Roberts, Influence of hepatic dysfunction on safety, tolerability and pharmacokinetics of PTK787/ZK222584 in patients with unresectable HCC. *J Clin Oncol* 23, A4134 (2005)

158. Alberts SR MB, Kim GP, et al. , NCCTG phase II trial (N044J) of AZD2171 for patients with hepatocellular carcinoma (HCC)-interim review of toxicity. . *Gastrointestinal Cancer Symposium, Orlando, Fla*, Abstract 186. , (2007)

159. Hegewisch-Becker S, M Sterneck, U Schubert, Phase I/II trial of bortezomib in patients with unresectable hepatocellular carcinoma. *J Clin Oncol* 22, A4089 (2004)

160. Wilhelm SM, C Carter, L Tang, D Wilkie, A McNabola, H Rong, C Chen, X Zhang, P Vincent, M McHugh, Y Cao, J Shujath, S Gawlak, D Eveleigh, B Rowley, L Liu, L Adnane, M Lynch, D Auclair, I Taylor, R Gedrich, A Voznesensky, B Riedl, LE Post, G Bollag, PA Trail, BAY 43-9006 exhibits broad spectrum oral antitumor activity and targets the RAF/MEK/ERK pathway and receptor tyrosine kinases involved in tumor progression and angiogenesis. *Cancer Res* 64, 7099-7109 (2004)

Key Words Radiotherapy, Targeted Therapy, Gene Therapy, Immune Therapy, Prevention, Review

Send correspondence to: Hubert E. Blum, Department of Medicine II, University of Freiburg, Hugstetter Strasse 55, D-79106 Freiburg, Germany, Tel: 49-761-270-3404, Fax: 49-761-270-3610, E-mail: hubert.blum@uniklinik-freiburg.de