[Frontiers in Bioscience 9, 216-224, January 1, 2004]

A BRIEF HISTORY OF THE DISCOVERY OF NATURAL SIMIAN IMMUNODEFICIENCY VIRUS (SIV) INFECTIONS IN CAPTIVE SOOTY MANGABEY MONKEYS

Bobby J. Gormus [1], Louis N. Martin [1] and Gary B. Baskin [2]

Divisions of [1] Microbiology and Immunology and [2] Comparative Pathology, Tulane National Primate Research Center, 18703 Three Rivers Road, Covington, LA 70433

TABLE OF CONTENTS

1. ABSTRACT

Experimental leprosy studies using *Mycobacterium leprae* inoculum isolated from a sooty mangabey monkey (SMM) resulted in the accidental discovery that SMM's asymptomatically carry simian immunodeficiency virus (SIV) that is pathogenic in macaques. We showed that the SMM virus, SIVDelta, was antigenically related to SIVmac, which had been identified in macaques, and to the human immunodeficiency virus (HIV). Similar asymptomatic natural SIV infections had been reported in African green monkeys (AGM). Our results together with observations of others led us to propose that both SIVmac and SIVDelta originated in SMM and that HIV emerged in humans as a result of early African nonhuman primate SIV trans-species infections in humans.

2. INTRODUCTION

Scientific discoveries are often the direct result of planned, systematic research aimed at testing hypotheses derived from prior systematic studies and observations. Frequently, however, discoveries are the result of a convoluted pathway that could not have been predicted or hypothesized. These latter types of discoveries can be the result of serendipity compounded by serendipity. The discoveries that captive sooty mangabey monkeys (SMM) carry asymptomatically an immunodeficiency-inducing virus that is related to the human immunodeficiency virus (HIV), that this virus was inadvertently transmitted to macaques years before its existence or origin was known, and that the passage of this virus was sometimes linked to transmissible lymphomas, fall into this latter category of the scientific process. The fact that our contribution to these discoveries was a by-product of studies of natural and experimental leprosy in SMM's is indicative of the serendipitous nature of the results.

3. LEPROSY STUDIES

In September, 1979, a female sooty mangabey monkey (SMM) (*Cercocebus atys*) housed at the Gulf South Research Institute (GSRI), New Iberia, LA, was noted as having severe skin infiltrations that had the appearance of leprosy. She had never been inoculated with an infectious agent and had been a control for a dietary cholesterol study. This SMM, AO15 or "Louise", was transferred to the Delta Regional Primate Research Center (DRPRC) (now the Tulane National Primate Research Center), Covington, LA, in December, 1979. "Louise" might have been euthanized except for the serendipitous fact that Dr. Peter Gerone, the DRPRC Director at that time, was a member of the GSRI Board of Directors and learned by that channel that the animal appeared to have leprosy. There was an on-going tuberculosis study in progress and considerable interest in mycobacterial diseases at the DRPRC at that time. Therefore, Dr. Gerone arranged for the transfer of "Louise" to our Center for further study. She was a feral monkey, approximately five years of age, that had been imported from West Africa in 1975.

In conjunction with Drs. Wayne M. Meyers and Chapman Binford, Armed Forces Institute of Pathology, Washington, DC and Dr. Gerald P. Walsh, American Registry of Pathology, Washington, DC, we began a thorough study of SMM A015. A skin biopsy revealed typical characteristics of lepromatous (LL) leprosy with high bacterial burden (1). By January, 1980, extensive

Table 1. Inoculation of rhesus monkeys with SMM-origin *M. leprae*

Recipient	SMM	Inoculation	Leprosy	Incubation	Leprosy	Other	Diseases
Rhesus	Donor	Date	Onset	Time (mo.)	Form [1]	Lymphoma	SAIDS [2]
8664	A022[3]	11/82	3/84	15	BL	+	+
B988	A022	11/82	3/84	15	I/TT	-	+
B748	A022	11/82	-	-	-	-	-
B845	A022	11/82	-	-	-	-	-
A125	A015	12/80	8/82	20	LL	-	-
A491	A015 [4]	12/80	-	38 [4]	-	-	-
	A022 [4]	2/84	1/88	47 [4]	BB	-	+

[1]Leprosy disease form based on the Ridley-Jopling (61) System: BL, borderline lepromatous; I/TT, indeterminate/tuberculoid; LL, lepromatous; BB, borderline. Degree of severity of defective anti-M. leprae cell-mediated immunity: LL>BL>BB>I/TT. [2]SAIDS diagnosed by weight loss, diarrhea, serology and necropsy after premature death (31).[3]A022 was a SIV-positive SMM experimentally inoculated with M. leprae from SMM A015; A015 was a SIV-negative SMM with naturally-acquired leprosy.
[4]No leprosy developed in A491 within 38 months of inoculation with M. leprae inoculum from SIV-negative A015, but developed leprosy within 47 months after inoculation with M. lep[rae from SIV-positive A022.

progressive disease was noted (1). Clinical, immunologic, pathologic and microbiologic studies of the etiologic agent, including DNA identification by Dr. Tomatsu Imaeda, confirmed multibacillary leprosy caused by *Mycobacterium leprae* that could not be distinguished from human-origin *M. leprae* (1). These results caused much excitement among leprosy researchers because natural leprosy had never been observed previously in a monkey (1,2). Moreover, a non-human primate model for leprosy had been sought for decades without notable success (2). If the SMM species could be shown to be uniquely susceptible to experimental leprosy, an important model that closely resembled human leprosy might be at hand.

As chance would have it, the YERKES Primate Center in Atlanta, GA had an active breeding colony of sooty mangabey monkeys, and were willing to ship a few normal animals to the DRPRC for experimental inoculation with *M. leprae* isolate from A015 and for use as controls. This was a fortunate turn of events because there was no other significant breeding colony of SMM in the world and importers were seldom able to obtain SMM. One reason for this unavailability was that the SMM was not in demand for experimental use or for other purposes and, therefore, methods of trapping them had not been widely implemented. Another reason was that the SMM was the favorite food monkey in West Africa and, therefore, were usually shot rather than captured. Surviving baby SMM were often taken home as "pets", where cross-species-exposure to numerous human and SMM pathogens was possible. If buyers for these young animals were available, they would be sold to the highest bidder. The few SMM that were commercially exported out of Africa, such as "Louise", were most likely obtained as youngsters by the described pathway.

Briefly, the ensuing experimental *M. leprae* inoculations at the DRPRC using inoculum originating in A015 were successful and led to many years of fruitful studies of leprosy using the SMM model and other nonhuman primate species (3-38). Virtually all inoculated SMM developed leprosy and at least 80% of them developed the more severe LL form that is indicative of little or no cellular immunity to *M. leprae* antigens (3,39).

4. SMM TO RHESUS MACAQUE LEPROSY TRANSMISSIONS

After it was established that *Mycobacterium leprae* was the etiologic agent causing leprosy in A015 and that leprosy could be easily transmitted from one SMM to another, it was considered possible that a monkey- or SMM-adapted strain of *M. leprae* was responsible, since it had not been previously possible to experimentally transmit leprosy to monkeys using *M. leprae* isolated from humans (2). Why was it so easy to transmit leprosy in SMM if not due to strain adaptation? In order to test the possibility of strain adaptation, and because rhesus monkeys were much more plentiful than SMM, we inoculated two rhesus monkeys in December, 1980 with *M. leprae* directly from A015 and, in November, 1982, four were inoculated with an isolate from a SMM (A022) that had been previously inoculated with A015 *M. leprae* isolate (Table 1) (20,31). Each of the rhesus monkeys inoculated in 11/82 with *M. leprae* from SMM A022 received 5 X 10^8 bacilli by intravenous (iv) route together with 5 X 10^8 intracutaneously (ic). Two of these animals (8664 and B988) developed leprosy {borderline lepromatous (BL) and indeterminate/tuberculoid (I/TT), respectively} within 15 months (Table 1). The other two rhesus (B748 and B845) failed to develop leprosy (Table 1). One of the two rhesus monkeys inoculated in 12/80 (A125) was given 1.5 X 10^8 A015 *M. leprae* by iv route and 6 X 10^8 ic. A125 developed LL leprosy within 20 months. The other monkey (A491) was inoculated with 6 X 10^8 *M. leprae* from A015 by ic route only. This monkey did not show signs of leprosy by 38 months (Table 1). A491 was subsequently re-inoculated by iv and ic routes with *M. leprae* isolated from SMM A022. A491 developed borderline (BB) leprosy 47 months after re-inoculation. Unexpectedly, three of the four rhesus monkeys that developed leprosy in this study (8664, B988 and A491) also developed a wasting syndrome that involved weight loss, diarrhea and death, similar to symptoms described in reports of rhesus monkeys with simian acquired immunodeficiency syndrome (SAIDS) (Table 1) (31,40,41). Each of the three SAIDS-positive rhesus monkeys received *M. leprae* inoculum from SMM A022 (Table 1).

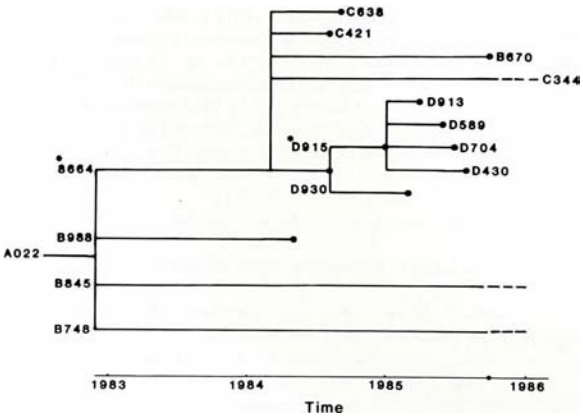

Figure 1. Rhesus monkeys 8664, B988, B845 and B748 were inoculated iv and ic with *M. leprae* inoculum taken from homogenized cutaneous lepromatous (LL) leprosy lesions of SMM A022. Rhesus 8664 and B988 developed leprosy and SAIDS. Rhesus B845 and B748 remained clinically normal. Rhesus 8664 developed lymphoma (asterisks). In an attempt to transmit lymphoma, inoculum was prepared from spleen cell suspensions and the retro-orbital lymphoma tissue of 8664 and these suspensions were passaged into rhesus monkeys C638 and C421 (spleen cells) and B670 and C344 (lymphoma cells). Cells from an abdominal tumor of 8664 were inoculated into rhesus D915 and D930. Only D915 developed lymphoma. Tumor cells or spleen cells from D915 were serially passaged into rhesus D430 and D913 and D589 and D704, respectively, none of which developed lymphoma. All but 3 of the rhesus monkeys described (B845, B748 and C344) developed SAIDS-like symptoms resulting in death (indicated by black dots). {Figure reproduced (31) with permission from the publisher}.

5. TRANSMISSIBLE LYMPHOMA AND SAIDS

It was at this point that a digression took place during the evolution of the leprosy study. Rhesus monkey 8664 developed a B-cell lymphoma, recognized in March, 1984 (Table 1). The lymphoma was found to be periorbital and was found in other tissue locations at necropsy (31). The other five rhesus monkeys described in Table 1 did not develop lymphoma .

Rhesus 8664 was euthanized in August, 1984 and cell suspensions from the retro-orbital tumor, an abdominal tumor mass or spleen were inoculated into six rhesus monkeys, including D915, which also developed a B-cell lymphoma (Figure 1) (31). Moreover, the transmissible B-cell lymphoma was found to be associated with an EBV-like herpes virus (42), similar to reports of lymphoma-inducing EBV-like viruses from other nonhuman primate species (43,44). Lymphoid (spleen) cells or tumor cells from D915 were sub-inoculated into four rhesus monkey recipients (31). These four, as well as five of six rhesus inoculated from 8664, developed clinical symptoms such as weight loss, diarrhea and death, but did not develop lymphoma (Figure 1). At necropsy, the rhesus monkeys in this study that succumbed, as well as those that died in the study described in Table 1, were found to have a variety of signs recognized to be characteristic of SAIDS (31,40,41). At this time, a possible link between experimental transmission of rhesus lymphoma tissue and SAIDS had been suggested (45). Some studies showed that SAIDS could be transmitted using cell-free inoculum from macaque lymphoma, although lymphoma was not transmitted (46). SAIDS could be transmitted in macaques using supernatants from homogenized tissues, whole blood and plasma from type D retrovirus-positive macaques (47,48). Other laboratories isolated type D retrovirus from macaques (47-50) and showed that this virus could produce experimental SAIDS (48,51,52). These results were similar to those observed in our studies (Table 1 & Figure 1).

By 1985, concurrent with our investigations, reports appeared describing a new retrovirus, termed simian T lymphotrophic virus-IIImac (STLV-IIImac, now known as SIVmac), due to its similarity to the human T lymphotrophic virus-III {HTLV-III, now known as human immunodeficiency virus (HIV)} (53-55). STLV-IIImac transmitted a SAIDS-like disease after inoculation of rhesus macaques (56). Reported electron microscopic morphology (53) and the immunosuppressive properties of STLV-IIImac were remarkably similar to the unknown virus from rhesus 8664 and D915 observed by Drs. Rangan and Baskin in our laboratory (31,42). Inoculum used for rhesus monkeys 8664 and D915 originated in SMM A022 (31). Type D retrovirus could not be detected in our macaques infected with inoculum from SMM A022 (31). Thus, the virus observed in our transmissible lymphoma studies differed from type D retrovirus, but had similarities to STLV-IIImac observed in rhesus monkeys by others.

6. SMM ORIGIN of SIV

Dr. Michael Murphey-Corb joined our faculty at the DRPRC in 1980. Her retrovirologic training and experience soon led to proof of our growing suspicions that the virus involved in the induction of SAIDS-like disease that occurred during our transmissible lymphoma studies originated in asymptomatic SMM and that it represented a previously unrecognized simian immunodeficiency virus (32). Dr. Murphey-Corb, in conjunction with Dr. Louis Martin, showed by Western blot and ELISA that antibodies cross-reactive with HTLV-III were present in the rhesus monkeys previously inoculated with leprosy inoculum isolated from SMM A022 (32). Moreover, evidence for the presence of this virus was found in 14 of 32 asymptomatic SMM, including SMM A022, the source of our rhesus inoculum (32). The data indicated that the SMM virus, termed STLV-IIIDelta (now SIVDelta), was antigenically related to HTLV-III (now HIV) and the newly described STLV-IIImac (now SIVmac)

7. *M. LEPRAE*/SIV INTERACTIONS

With the foregoing in mind, we may now return to a discussion of the leprosy study. As described above, two of four rhesus monkeys inoculated with *M. leprae* inoculum from SMM A022 (8664 and B988) developed both leprosy and SAIDS, whereas, two (B748 and B845) developed neither disease (Table 1) (20). Animals 8664,

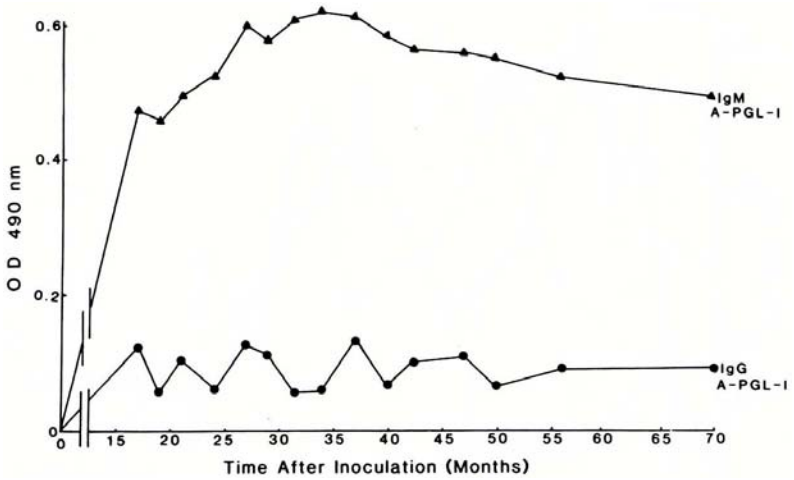

Figure 2. IgG and IgM antibody responses to *M. leprae* phenolic glycolipid-I (PGL-I) cell wall antigen (ELISA) in rhesus monkey A125 before and at intervals after inoculation with inoculum from SMM A015. {Figure reproduced (20) with permission from the publisher}.

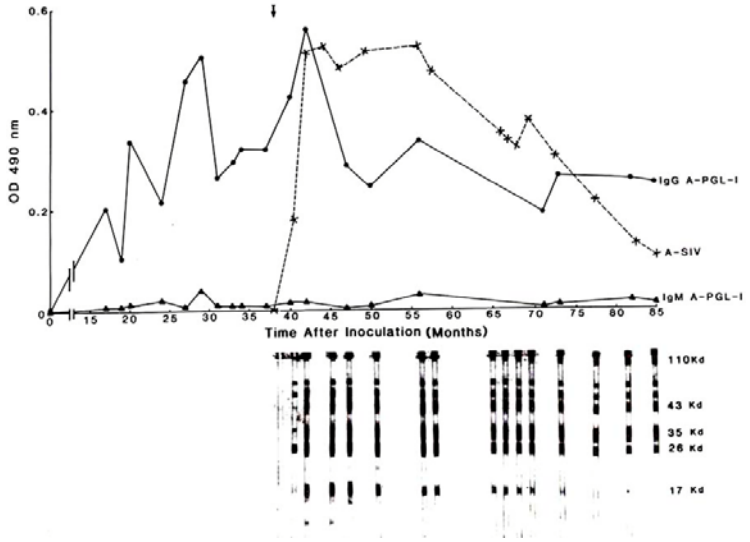

Figure 3. Antibody responses to *M. Ieprae* phenolic glycolipid-I (PGL-I) antigen and to simian T lymphotrophic virus {STLV-III, now simian immunodeficiency virus (SIV)} antigens in rhesus A491. The monkey was inoculated in December 1980 with SIV-free *M. leprae* and with SIV--contaminated *M. leprae* 38 months later (arrow). Pre- and post-inoculation serum samples, beginning at month 17, were exam-ined by ELISA for IgG (•)and IgM (triangles) antibody levels to PGL-I, for IgG antibodies to SIV (x) (top panel) and by Western blot for antibody responses to individual SIV antigens (bottom panel). Each Western blot corresponds in time to ELISA for antibodies to SIV (top). {Figure reproduced (20) with permission from the publisher}.

B988 and B845 became serologically positive for STLV-IIIDelta antibody, but B748 failed to seroconvert. It is not known why B748 failed to become infected with STLV-IIIDelta (or *M. leprae*) or why B845 failed to develop clinical SAIDS (or leprosy). B748 died of acute gastric dilatation 4 years post-inoculation. B845 survived for almost 12 years with no signs of leprosy or SAIDS before succumbing to septicemia during an unrelated procedure. B748 and B845 were both negative for SAIDS and leprosy at necropsy. Dr. Murphey-Corb's studies showed that A022 was STLV-III-positive and this virus was evidently co-transmitted to this group of rhesus monkeys along with the *M. leprae* inoculum (32).

Two rhesus were inoculated with *M. leprae* inoculum from SMM A015, which had natural leprosy and was STLV-III-negative by Western blot, virus culture and by RT-PCR analysis, but was STLV-I-positive (32). One of the A015 recipients (A125) developed LL leprosy within 20 months, but the second A015 recipient (A491) failed to develop leprosy within 38 months (Table 1) (20). Both A125 and A491 produced persisting high levels of anti-*M. leprae*-phenolic glycolipid-I (PGL-I) antibodies, suggesting that the *M. leprae* infection in A491 persisted, although no clinical signs of leprosy were visible in this animal (Figures 2 and 3). No antibodies to STLV-IIIDelta were present in A125 or initially in A491, of course, since the source of the

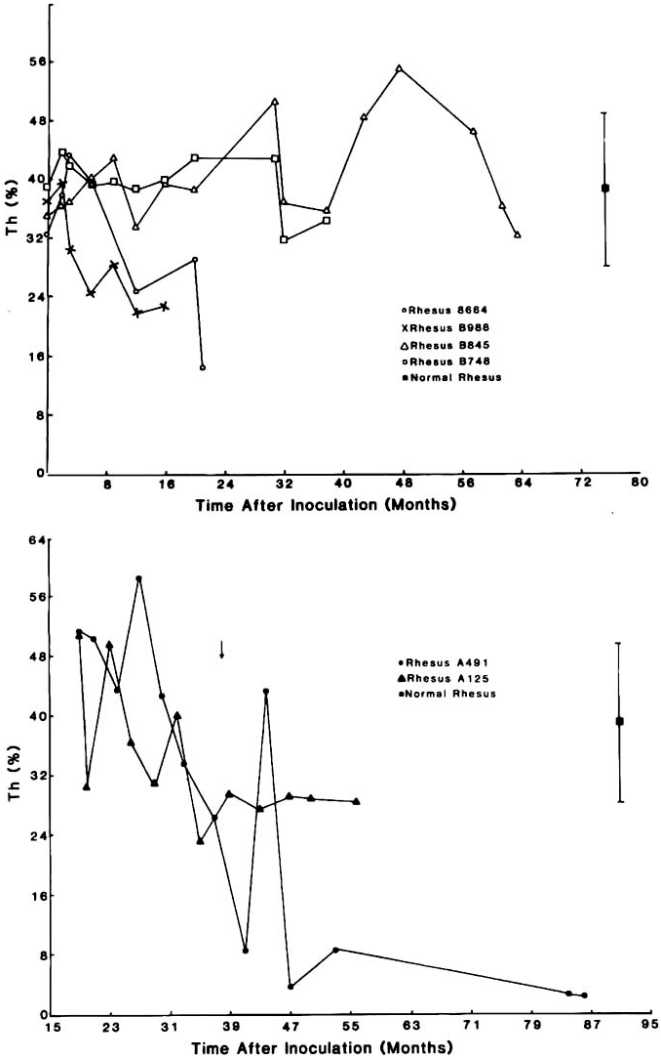

Figure 4. Percentages of CD4+ T cells (T-helper, Th) in peripheral blood of rhesus monkeys after experimental M. leprae inoculation. Mean ± 1 SE of normal rhesus monkeys (n = 58). Top Panel: Four animals inoculated at time zero with STLV-III (SIV-Delta) contaminated M. leprae isolate; 8664 and B988 developed leprosy and SAIDS; B845 developed neither disease but became serologically positive for SIV; and B748 had neither leprosy nor indications of SIV infection. Animals A491 and A125 were inoculated at time 0 with SIV-negative inocula; A491 was re-inoculated during month 38 (arrow) with SIV-containing isolate. {Figure reproduced (20) with permission from the publisher}.

inoculum (SMM A015) was STLV-III-negative (32). However, rhesus A491 was re-inoculated after 38 months with *M. leprae* isolate from A022, resulting in the appearance of high levels of anti-STLV-IIIDelta antibodies documented by Western blot (Figure 3) (20). A491 developed signs of SAIDS 28 months post-re-inoculation and developed clinical signs of borderline (BB) leprosy by 48 months. Necropsy confirmed both leprosy and SAIDS in A491 (20).

Blood CD4+ T cell percentages were longitudinally studied in the six rhesus monkeys described in Table 1 (20). Significant reductions in CD4+ percentages were observed in animals 8664 and B988, which developed SAIDS and leprosy, but no reductions in CD4+ percentages were observed in monkeys B748 or B845, which failed to develop either SAIDS or leprosy (Figure 4). A substantial significant reduction in CD4+ T cell percentages was also observed in rhesus A491 after inoculation with STLV-IIIDelta-containing *M. leprae* inoculum from SMM A022 (Figure 4). There was also a diminution in CD4+ T cell percentages over time in rhesus A125, although the CD4+ percentages remained within the low normal range (Figure 4). In retrospect, loss of CD4+ T cells was expected, as observed, except for A125, since the source of A125's inoculum (SMM A015) was STLV-III-negative. However, SMM A015 was STLV-I-positive and this virus may have been responsible for the loss of CD4+ T cells.

8. CONCLUSIONS

The data indicated that rhesus monkeys infected with STLV-III-contaminated inoculum either developed both leprosy and SAIDS or neither disease and that the loss

of CD4+ T cells paralleled the development of leprosy as well as SAIDS. No evidence was found that SMM-origin *M. leprae* differed from human *M. leprae* (1). Rather, it was concluded that the presence of asymptomatic STLV-IIIDelta (SIVDelta) infections in SMM rendered this species susceptible to leprosy (20). Moreover, the data suggest strongly that rhesus monkeys, a species that has been historically resistant to experimental leprosy (2), become susceptible to *M. leprae* disease secondary to co-infection with STLV-IIIDelta (SIVDelta) (20). We have published more recent data supporting this conclusion (7,38). Thus far, however, there has been little support from high leprosy- and HIV-endemic areas that there is a parallel situation between HIV infection and leprosy susceptibility in the human population.

9. EPILOGUE

The history described in this chapter would not be complete without mentioning that the remainder of the puzzle concerning the identity, origin and relationships between STLV-IIIDelta (SIVDelta) and STLV-IIImac (SIVmac) have been determined and reviewed (57). To summarize, SIVmac, first isolated from macaques in 1985 at the New England Regional Primate Research Center (NERPRC) (53,55,56), had its origin in SMM's at the California Regional Primate Research Center (CRPRC) where, in 1969, macaques were housed with SIV-positive SMM (57). SIV-infected macaques at the CRPRC first showed SAIDS-like symptoms in 1969 and later in 1970 (58,59) after being in contact with SIV-positive SMM's. SIV-infected macaques were inadvertently sent to other Primate Centers, including the NERPRC, where additional spread to other macaques took place. Thus, evidence suggests that both SIVDelta and SIVmac originated in SMM's and are closely related to one another and to HIV genetically (57). Concurrent with our studies in SMM's, a similar natural retroviral infection ($STLVIII_{AGM}$, now SIV_{AGM}) was reported in African green monkeys (AGM) (54,60). Our observations of natural SIV infections in SMM's together with reports of similar natural infections of AGM with SIV closely related to the human counterpart, HIV, led us to hypothesize that HIV emerged in humans as a result of early African nonhuman primate SIV trans-species infections of humans (32). More recent data have confirmed this hypothesis and revealed genetic inter-relationships between HIV strains and multiple variants of SIV isolated from captive and feral SMM, as well as other nonhuman primate species (Apetrei C, Robertson DL, Marx PA: The History of SIVs and AIDS: Epidemiology, Phylogeny and Biology of Isolates from Naturally SIV Infected Non-human Primates (NHP) in Africa, this volume).

10. REFERENCES

1. Meyers, W.M., G.P. Walsh, H.L. Brown, C.H. Binford, G.D. Imes, T.L. Hadfield, C.J. Schlagel, Y. Fukunishi, P.J. Gerone, R.H. Wolf, B.J. Gormus, L.N. Martin, M. Harboe, and T. Imaeda. Leprosy in a Mangabey Monkey-Naturally Acquired Infection. *Int J lepr other Mycobact Dis* 53, 1-14 (1985)

2. Martin, L.N., B.J. Gormus, R.H. Wolf, G.P. Walsh, W.M. Meyers, C.H. Binford, and M. Harboe. Experimental leprosy in nonhuman primates. *Adv Vet Sci Comp Med* 28, 201-236 (1984)

3. Gormus, B.J., K. Xu, S.N. Cho, G.B. Baskin, R.P. Bohm, L.N. Martin, J.L. Blanchard, P.A. Mack, M.S. Ratterree, W.M. Meyers, and G.P. Walsh. Experimental Leprosy in Monkeys. II. Longitudinal Serological Observations in Sooty Mangabey Monkeys. *Lepr Rev* 66, 105-125 (1995)

4. Gormus, B.J., D.K. Ohashi, S. Ohkawa, G.P. Walsh, W.M. Meyers, P.J. Brennan, and C.B. Trygg. Serologic Responses to *Mycobacterium leprae*-Specific Phenolic Glycolipid I Antigen in Sooty Mangabey Monkeys with Experimental Leprosy. *Int J LeprOther Mycobact Dis* 56, 537-545 (1988)

5. Gormus, B.J., K. Xu, G.B. Baskin, L.N. Martin, R.P. Bohm,Jr., J.L. Blanchard, P.A. Mack, M.S. Ratterree, W.M. Meyers, and G.P. Walsh. Experimental leprosy in rhesus monkeys: transmission, susceptibility, clinical and immunological findings. *Lepr Rev* 69, 235-245 (1998)

6. Valverde, C.R., D. Canfield, R. Tarara, M.I. Esteves, and B.J. Gormus. Spontaneous leprosy in a wild-caught cynomolgus macaque. *Int J LeprOther Mycobact Dis* 66, 140-148 (1998)

7. Gormus, B.J., M. Murphey-Corb, L.N. Martin, G.B. Baskin, P.A. Mack, K. Xu, M.S. Ratteree, P.J. Gerone, D.M. Scollard, and T.P. Gillis. Impaired responses to Mycobacterium leprae antigens in rhesus monkeys experimentally inoculated with simian immunodeficiency virus and M. leprae. *Lepr Rev* 69, 24-39 (1998)

8. Gormus, B.J., G.B. Baskin, K. Xu, R.P. Bohm, P.A. Mack, M.S. Ratterree, S.N. Cho, W.M. Meyers, and G.P. Walsh. Protective immunization of monkeys with BCG or BCG plus heat-killed Mycobacterium leprae: clinical results. *Lepr Rev* 69, 6-23 (1998)

9. Saad, M.H., B.J. Gormus, S.N. Cho, H. Bernheimer, and B. Schwerer. Detection of IgA anti-PGL-I specific antigen to Mycobacterium leprae in mangabey monkeys inoculated with M. leprae. *Lepr Rev* 66, 296-306 (1995)

10. Kashala, O., R. Marlink, M. Ilunga, M. Diese, B. Gormus, K. Xu, P. Mukeba, K. Kasongo, and M. Essex. Infection with human immunodeficiency virus type 1 (HIV-1) and human T cell lymphotropic viruses among leprosy patients and contacts: correlation between HIV-1 cross-reactivity and antibodies to lipoarabinomannan [see comments]. *J Infect Dis* 169, 296-304 (1994)

11. Cho, S.N., B.J. Gormus, K. Xu, R.P. Bohm,Jr., G.P. Walsh, W.M. Meyers, and J.D. Kim. Serologic responses to nerve antigens in sooty mangabey monkeys with experimental leprosy. *Int J Lepr Other Mycobact Dis* 61, 236-244 (1993)

12. Meyers, W.M., B.J. Gormus, and G.P. Walsh. Nonhuman sources of leprosy. *Int J Lepr Other.Mycobact Dis* 60, 477-480 (1992)

13. Baskin, G.B., B.J. Gormus, K. Xu, L.N. Martin, R.H. Wolf, C. Cantrell, G.H. Pezeshkpour, G.P. Walsh, R. Malaty, and W.M. Meyers. Experimental borderline lepromatous leprosy with intraneural erythema nodosum leprosum in a mangabey monkey (Cercocebus atys) *Int J Lepr Other Mycobact Dis* 59, 618-623 (1991)

14. Hubbard, G.B., D.R. Lee, J.W. Eichberg, B.J. Gormus, K. Xu, and W.M. Meyers. Spontaneous leprosy in a chimpanzee (Pan troglodytes) *Vet Pathol* 28, 546-548 (1991)

15. Gormus, B.J., K.Y. Xu, P.L. Alford, D.R. Lee, G.B. Hubbard, J.W. Eichberg, and W.M. Meyers. A serologic study of naturally acquired leprosy in chimpanzees. *Int J Lepr Other Mycobact Dis* 59, 450-457 (1991)

16. Meyers, W.M., B.J. Gormus, G.P. Walsh, G.B. Baskin, and G.B. Hubbard. Naturally acquired and experimental leprosy in nonhuman primates. *Am J Trop Med Hyg* 44, 24-27 (1991)

17. Hussein, N., B. Ostler, B.J. Gormus, R. Wolf, and G.P. Walsh. Intraocular pressure changes and postural changes of intraocular pressure in experimentally induced Hansen's disease of rhesus, mangabey, and African green monkeys. *Br J Ophthalmol* 74, 647-649 (1990)

18. Baskin, G.B., B.J. Gormus, L.N. Martin, M. Murphey-Corb, G.P. Walsh, and W.M. Meyers. Pathology of dual Mycobacterium leprae and simian immunodeficiency virus infection in rhesus monkeys. *Int J Lepr Other Mycobact Dis* 58, 358-368 (1990)

19. Gormus, B.J., K. Xu, W.M. Meyers, G.P. Walsh, W.R. Levis, and H.C. Meeker. Antibodies to lipoarabinomannan antigen in sooty mangabey monkeys experimentally inoculated with Mycobacterium leprae. *Int J Lepr Other Mycobact Dis* 58, 65-72 (1990)

20. Gormus, B.J., M. Murphey-Corb, L.N. Martin, J.Y. Zhang, G.B. Baskin, C.B. Trygg, G.P. Walsh, and W.M. Meyers. Interactions between simian immunodeficiency virus and Mycobacterium leprae in experimentally inoculated rhesus monkeys. *J Infect Dis* 160, 405-413 (1989)

21. Gormus, B.J., D.K. Ohashi, S. Ohkawa, G.P. Walsh, W.M. Meyers, P.J. Brennan, and C. Trygg. Serologic responses to Mycobacterium leprae-specific phenolic glycolipid-I antigen in sooty mangabey monkeys with experimental leprosy. *Int J Lepr Other Mycobact Dis* 56, 537-545 (1988)

22. Malaty, R., W.M. Meyers, G.P. Walsh, C.H. Binford, L.E. Zimmerman, G.B. Baskin, B.J. Gormus, L.N. Martin, and R.H. Wolf. Histopathological changes in the eyes of mangabey monkeys with lepromatous leprosy. *Int J Lepr Other Mycobact Dis* 56, 443-448 (1988)

23. Gormus, B.J., R.H. Wolf, G.B. Baskin, S. Ohkawa, P.J. Gerone, G.P. Walsh, W.M. Meyers, C.H. Binford, and W.E. Greer. A second sooty mangabey monkey with naturally acquired leprosy: first reported possible monkey-to-monkey transmission. *Int J Lepr Other Mycobact Dis* 56, 61-65 (1988)

24. Walsh, G.P., W.M. Meyers, C.H. Binford, B.J. Gormus, G.B. Baskin, R.H. Wolf, and P.J. Gerone. Leprosy as a zoonosis: an update. *Acta Leprol* 6, 51-60 (1988)

25. Baskin, G.B., B.J. Gormus, L.N. Martin, R.H. Wolf, J.L. Blanchard, R. Malaty, G.P. Walsh, W.M. Meyers, and C.H. Binford. Experimental leprosy in African green monkeys (Cercopithecus aethiops): a model for polyneuritic leprosy. *Am J Trop Med Hyg,* 37, 385-391 (1987)

26. Ohkawa, S., L.N. Martin, and B.J. Gormus. Lepromin-induced lymphoproliferative response of experimental leprosy monkeys: regulatory role of monocyte and lymphocyte subsets. *J Immunol* 138, 3943-3948 (1987)

27. Baskin, G.B., B.J. Gormus, L.N. Martin, R.H. Wolf, M. Murphey-Corb, G.P. Walsh, C.H. Binford, W.M. Meyers, and R. Malaty. Experimental leprosy in a rhesus monkey: necropsy findings. *Int J Lepr Other Mycobact Dis* 55, 109-115 (1987)

28. Ohkawa, S., L.N. Martin, Y. Fukunishi, and B.J. Gormus. Regulatory role of FcR+ and FcR- monocyte subsets in Mycobacterium leprae-induced lymphoproliferative response in vitro. *Clin Exp Immunol* 67, 43-50 (1987)

29. Baskin, G.B., B.J. Gormus, L.N. Martin, R.H. Wolf, E.A. Watson, G.P. Walsh, W.M. Meyers, and C.H. Binford. The lepromin test in rhesus monkeys. *Int J Lepr Other Mycobact Dis* 54, 427-436 (1986)

30. Modlin, R.L., L.D. Ormerod, G.P. Walsh, T.H. Rea, W.M. Meyers, C.H. Binford, L.N. Martin, R.H. Wolf, and B.J. Gormus. In situ characterization of T lymphocyte subpopulations in leprosy in the mangabey monkey. *Clin Exp Immunol* 65, 260-264 (1986)

31. Baskin, G.B., L.N. Martin, S.R. Rangan, B.J. Gormus, M. Murphey-Corb, R.H. Wolf, and K.F. Soike. Transmissible lymphoma and simian acquired immunodeficiency syndrome in rhesus monkeys. *JNCI* 77, 127-139 (1986)

32. Murphey-Corb, M., L.N. Martin, S.R. Rangan, G.B. Baskin, B.J. Gormus, R.H. Wolf, W.A. Andes, M. West, and R.C. Montelaro. Isolation of an HTLV-III-related retrovirus from macaques with simian AIDS and its possible origin in asymptomatic mangabeys. *Nature* 321, 435-437 (1986)

33. Baskin, G.B., R.H. Wolf, B.J. Gormus, L.N. Martin, G.P. Walsh, C.H. Binford, W.M. Meyers, and R. Malaty. Experimental leprosy in the mangabey (Cercocebus atys): necropsy findings. *Int J Lepr Other Mycobact Dis* 53, 269-277 (1985)

34. Wolf, R.H., B.J. Gormus, L.N. Martin, G.B. Baskin, G.P. Walsh, W.M. Meyers, and C.H. Binford. Experimental leprosy in three species of monkeys. *Science* 227, 529-531 (1985)

35. Martin, L.N., B.J. Gormus, R.H. Wolf, P.J. Gerone, W.M. Meyers, G.P. Walsh, C.H. Binford, T.L. Hadfield, and C.J. Schlagel. Depression of lymphocyte responses to mitogens in mangabeys with disseminated experimental leprosy. *Cell Immunol* 90, 115-130 (1985)

36. Fukunishi, Y., W.M. Meyers, C.H. Binford, G.P. Walsh, F.B. Johnson, P.J. Gerone, R.H. Wolf, B.J. Gormus, and L.N. Martin. Electron microscopic study of leprosy in a mangabey monkey (natural infection) *Int J Lepr Other Mycobact Dis* 52, 203-207 (1984)

37. Gormus, B.J., G.B. Baskin, K. Xu, M.S. Ratterree, L.N. Martin, P.A. Mack, R.P. Bohm, W.M. Meyers, and G.P. Walsh. Antileprosy protective vaccination of rhesus monkeys with BCG or BCG plus heat-killed Mycobacterium leprae: immunologic observations. *Int J Lepr Other Mycobact Dis* 68, 27-39 (2001)

38. Gormus, B.J., M. Murphey-Corb, G.B. Baskin, K. Uherka, L.N. Martin, P.A. Marx, K. Xu, and M.S. Ratterree. Interactions between Mycobacterium leprae and simian immunodeficiency virus (SIV) in rhesus monkeys. *J Med Primatol* 29, 259-267 (2000)

39. Gormus, B.J., K. Xu, G.B. Baskin, L.N. Martin, R.P. Bohm, J.L. Blanchard, P.A. Mack, M.S. Ratterree, H.M. McClure, W.M. Meyers, and G.P. Walsh. Experimental Leprosy in Monkeys. I. Sooty Mangabey Monkeys: Transmission, Susceptibility, Clinical and Pathological Findings. *Lepr Rev* 66, 96-104 (1995)

40. Holmberg, C.A., R. Henrickson, J. Anderson, and B.I. Osburn. Malignant lymphoma in a colony of Macaca arctoides. *Vet Pathol* 22, 42-45 (1985)

41. Henrickson, R.V., D.H. Maul, K.G. Osborn, J.L. Sever, D.L. Madden, L.R. Ellingsworth, J.H. Anderson, L.J. Lowenstein, and M.B. Gardner. Epidemic of acquired immunodeficiency in rhesus monkeys. *Lancet* 1, 388-390 (1983)

42. Rangan, S.R., L.N. Martin, B.E. Bozelka, N. Wang, and B.J. Gormus. Epstein-Barr virus-related herpesvirus from a rhesus monkey (Macaca mulatta) with malignant lymphoma. *Int J Cancer* 38, 425-432 (1986)

43. Voevodin, A.F., L.A. Yakoleva, B.A. Lapin, and T.L. Panomarjeva. Increased antibody responses to herpes papio (HVP) antigens in prelymphomatous baboons (Papio hamadryas) of the Sukhumi high lymphoma stock. *Int J Cancer* 32, 637-639 (1983)

44. Bocker, J.F., K.H. Tiedemann, G.W. Bornkamm, and H. zurHausen. Characterization of an EBV-like virus from African green monkey lymphoblasts. *Virol* 101, 291-295 (1980)

45. Hunt, R.D., R.J. Blake, L.V. Chalifoux, P.K. Sehgal, N.W. King, and N.L. Letvin. Transmission of naturally occurring lymphoma in macaque monkeys. *Proc Natl Acad Sci* 80, 5085-5089 (1983)

46. Letvin, N.L, W.R. Aldrich, N.W. King, B.J. Blake, M.D. Daniel, and R.D. Hunt. Experimental transmission of macaque AIDS by means of inoculation of macaque lymphoma tissue. *Lancet* 2, 599-602 (1983)

47. London, W.T., J.L. Sever, D.L. Madden, R.V. Henrickson, M. Gravell, D.H. Maul, M.C. Dalakas, K.G. Osborn, S.A. Houff, and M.B. Gardner. Experimental transmission of simian immunodeficiency syndrome (SAIDS) and Kaposi-like skin lesions. *Lancet* 2, 869-873 (1983)

48. Gravell, M., W.T. London, R.S. Hamilton, J.L. Sever, A.Z. Kapikian, G. Murti, L.O. Arthur, R.V. Gilden, K.G. Osborn, and P.A. Marx. Transmission of simian AIDS with type D retrovirus isolate. *Lancet* 1, 334-335 (1984)

49. Daniel, M.D., N.W. King, N.C. Letvin, R.D. Hunt, P.K. Sehgal, and R.C. Derosiers. A new type D retrovirus isolated from macaques with an immunodeficiency syndrome. *Science* 223, 602-605 (1984)

50. Stromberg, K., R.E. Benveniste, L.O. Arthur, H. Rabin, W.E. Giddens, H.D. Ochs, W.R. Morton, and C.C. Tsai. Characterization of exogenous type D retrovirus from a fibroma of a macaque with simian AIDS and fibromatosis. *Science* 223, 289-292 (1984)

51. Marx, P.A, D.H. Maul, K.G. Osborn, N.W. Lerche, P. Moody, L.J. Lowenstein, R.V. Henrickson, L.O. Arthur, and R.V. Gilden. Simian AIDS: Isolation of a type D retrovirus and transmission of the disease. *Science* 223, 1083-1085 (1984)

52. Gravell, M., W.T. London, G. Lecatsas, R.S. Hamilton, S.A. Houff, and J.L. Sever. Transmission of simian acquired immunodeficiency syndrome (SAIDS) with type D retrovirus isolated from saliva and urine. *Proc Soc Exp Biol Med* 177, 491-494 (1984)

53. Daniel, M.D., N.L. Letvin, N.W. King, M. Kannagi, P.K. Sehgal, R.D. Hunt, P.J. Kanki, M. Essex, and R.C. Desrosiers. Isolation of T-cell tropic HTLV-III-like retrovirus from macaques. *Science* 228, 1201-1204 (1985)

54. Kanki, P.J., M.F. Mclane, N.W. King, N.L. Letvin, R.D. Hunt, P. Sehgal, M.D. Daniel, R.C. Desrosiers, and M. Essex. Serologic characterization of a macaque T-

lymphotrophic retrovirus closely related to HTLV-III. *Science* 228, 1199-1201 (1985)

55. Kannagi, M., J.M. Yetz, and N.L. Letvin. In vitro growth characteristics of simian T-lymphotropic virus type III. *Proc Natl Acad Sci USA* 82, 7053-7057 (1985)

56. Letvin, N.L., M.D. Daniel, P.K. Sehgal, R.C. Desrosiers, R.D. Hunt, L.M. Waldron, J.J. MacKey, D.K. Schmidt, L.V. Chalifoux, and N.W. King. Induction of AIDS-like disease in macaque monkeys with T-cell tropic retrovirus STLV-III. *Science* 230, 71-73 (1985)

57. Gardner, M.B. The history of simian AIDS. *J Med Primatol* 25, 148-157 (1996)

58. Lowenstine, L.J., N.W. Lerche, J.L. Yee, A. Uyeda, M.B. Jennings, R.J. Munn, H.M. McClure, D.C. Anderson, P.N. Fultz, and M.B. Gardner. Evidence for a lentiviral etiology in an epizootic of immune deficiency and lymphoma in stump-tailed macaques. *J Med Primatol* 21, 1-14 (1992)

59. Stowell, R.E., E.K. Smith, C. Espana, and V.G. Nelson. Outbreak of malignant lymphoma in rhesus monkeys. *Lab Invest* 25, 476-479 (1971)

60. Kanki, P.J., R. Kueth, W. Becker, G. Dreesman, M.F. Mclane, and M. Essex. Antibodies to Simian T-Lymphotrophic Retrovirus Type III in African Green Monkeys and recognition of STLV-III Viral Proteins by AIDS and Related Sera. *Lancet* 1, 1330-1332 (1985)

61. Ridley, D.S. and W.H. Jopling. Classification of leprosy according to immunity. *Int J Lep Other Mycobact Dis* 34, 255-273 (1966)

Key Words: SAIDS, simian AIDS , lymphoma, leprosy, SIVDelta, SIVmac, EBV, HIV, Review

Send correspondence to: Dr Bobby J. Gormus, Divisions of Microbiology and Immunology, Tulane National Primate Research Center, 18703 Three Rivers Road, Covington, LA 70433, Tel: (985) 871-6291, Fax: (985) 871-6248, E-mail: gormus@tpc.tulane.edu