

## OVERLESIONED HEMIPARKINSONIAN NON HUMAN PRIMATE MODEL: CORRELATION BETWEEN CLINICAL, NEUROCHEMICAL AND HISTOCHEMICAL CHANGES

Yoshitsugu Oiwa<sup>1</sup>, Jamie L. Eberling<sup>1</sup>, Dea Nagy<sup>2</sup>, Phillip Pivrotto<sup>2</sup>, Marina E. Emborg<sup>3</sup> and Krys S. Bankiewicz<sup>1,2</sup>

*Center for Functional Imaging<sup>1</sup>, Lawrence Berkeley National Laboratory, University of California, Berkeley, CA, Department of Neurological Surgery<sup>2</sup>, University of California, San Francisco, CA, and Department of Neurological Science<sup>3</sup>, Rush Presbyterian Medical Center, Chicago, IL*

### TABLE OF CONTENTS

1. Abstract
2. Introduction
3. Materials and methods
  - 3.1. Subjects and treatments
  - 3.2. Clinical Rating
  - 3.3. PET study
  - 3.4. Necropsy and preparation of tissue
  - 3.5. Biochemical Assay
  - 3.6. Histochemical study
  - 3.7. Data analysis
4. Results
  - 4.1. Behavioral changes
  - 4.2. Neurochemical changes
  - 4.3. Histochemical changes
  - 4.4. Correlations between clinical findings, striatal DA, TH-IR cell counts and PET
5. Discussion
  - 5.1. Nigrostriatal damage in overlesioned hemiparkinsonian model
  - 5.2. Nigrostriatal damage in MPTP primate models
  - 5.3. Correlation between in vivo and postmortem measurements
  - 5.4. Functional recovery in MPTP primate models
  - 5.5. Relevance to human PD
  - 5.6. Utility of the model for translational studies
  - 5.7. Conclusion
6. Acknowledgments
7. References

### 1. ABSTRACT

Monkeys treated with 1-methyl-4-phenyl-1,2,3,6-tetrahydropyridine (MPTP) have been widely used as animal models of Parkinson's disease (PD). Depending on the method of administration different PD models can be developed. Systemic (iv, sc.) MPTP administration can induce an advanced parkinsonian syndrome. However, systemic administration may require intensive animal care after neurotoxin administration, as well as repeated high doses of MPTP to avoid spontaneous recovery. Unilateral intracarotid artery (ICA) MPTP administration induces a stable hemiparkinsonian syndrome, with the advantage of allowing the animal to groom and feed itself and having a control side in the same animal. However, this unilateral syndrome lacks the bilateral characteristics of advanced PD. Bilateral ICA administration can induce a reliable bilateral syndrome but inherent is the risk of severely impairing the animals and leaving them unable to maintain themselves. This report analyzed the PD model induced by administration of unilateral ICA and subsequent intravenous injections of MPTP in rhesus monkeys. The combined method of MPTP administration induces an advanced stable parkinsonian syndrome, in which the ICA

injection of MPTP initiates the parkinsonian syndrome primarily in one hemisphere and the subsequent iv. doses (administered as needed) further deplete the dopamine (DA) system to induce a bilateral lesion in a shorter period of time, with fewer side effects. We studied the relationships between the behavioral, biochemical and histochemical changes related to the combined MPTP treatments to further characterize this model. The monkeys were categorized as presenting mild (stage 2) or moderate (stage 3) parkinsonism based on a parkinsonian rating scale. Postmortem biochemical analysis showed massive DA reduction equally in the caudate nucleus and putamen ipsilateral to ICA MPTP infusion, with varying degrees of DA preservation in the contralateral striatum. Differences between stage 2 and stage 3 were attributed to DA concentrations in the caudate nucleus and putamen of the contralateral hemisphere. Tyrosine hydroxylase immunohistochemistry revealed that the midbrain DA neurons of the group A8, A9, and A10 showed differential vulnerability for MPTP. This finding was similar to that observed in idiopathic PD with significant relationships between the clinical stages and cell losses in the group A9

(substantia nigra pars compacta). Positron emission tomography (PET) using [ $^{18}\text{F}$ ] 6-fluoro-L-m-tyrosine (FMT) showed that uptake ( $K_i$ ) values correlated well with the biochemical data and are good predictors of DA levels in the contralateral striatal regions. Consistent with the immunohistochemical analysis, PET data also showed significant correlations with all groups of the DA cells. Here we describe an animal model that can play an important role in understanding the symptoms and therapeutic basis of PD since different severities of parkinsonian symptoms can be mimicked.

## 2. INTRODUCTION

The neurotoxin 1-methyl-4-phenyl-1,2,3,6-tetrahydropyridine (MPTP) produces a syndrome in human and non-human primates quite similar to idiopathic Parkinson's disease (PD) in which various motor deficits such as bradykinesia, flexed posture, balance disturbance, rigidity and tremor predominate (1, 2, 3). In fact, similar to idiopathic PD selective loss of dopaminergic neurons in the substantia nigra pars compacta (SNpc) which results in dopamine (DA) depletion in the striatum, is induced in human and non-human primates by MPTP exposure (1, 3, 4, 5). However, differences between MPTP-induced PD in non-human primates and idiopathic PD have been described. The onset of motor symptoms in human PD results from an approximately 70 - 80% reduction in striatal DA (6, 7), although more extensive DA reduction has been described in asymptomatic monkeys after MPTP treatments (8, 9). Monkeys exhibiting parkinsonian motor symptoms usually develop massive DA depletions equally in the caudate nucleus and putamen. This pattern of striatal DA loss differs from human PD in which the putamen is more affected than the caudate nucleus (7, 10, 11, 12). Regarding the midbrain dopaminergic neurons, in idiopathic PD the cell group A9, which corresponds to the SNpc and gives rise to the mesostriatal DA system innervating the caudate nucleus and putamen, is most affected. In addition cell group A10, the ventral tegmental area, and cell group A8, corresponding to the retrorubral area or ventral reticular formation, are also affected (12, 13, 14, 15). Interestingly, it has been reported that MPTP-treated monkeys present a differential vulnerability in the midbrain dopaminergic cells quite similar to PD (5, 16), although conflicting findings have also been reported and this remains an area of controversy (17, 18, 19).

Depending on the method of MPTP administration different PD models can be developed. Systemic (iv, sc.) MPTP administration can induce an advanced parkinsonian syndrome. However, systemic administration may require intensive animal care after neurotoxin administration, as well as repeated high doses of MPTP to avoid spontaneous recovery (eg: 8, 12). Bankiewicz and colleagues (20) developed a non human primate model of hemiparkinsonism by the unilateral infusion of MPTP into one internal carotid artery (ICA). In this unilateral model, the animals exhibit typical parkinsonian signs in the limbs contralateral to ICA MPTP infusion, but no motor deficits in the ipsilateral limbs because of preservation of dopaminergic innervation of the

contralateral (untreated) cerebral hemisphere. However, this unilateral syndrome lacks the bilateral characteristics of advanced PD. Bilateral ICA administration has been administered to induce a reliable bilateral syndrome (21) but inherent to this model is the risk of severely impairing the animals, incapacitating them to take care of their basic needs. The overlesioned hemiparkinsonian model is produced by a unilateral ICA MPTP infusion followed by the systemic administration of additional doses of MPTP (22, 23, 24). In this combined method of MPTP administration, the ICA injection of MPTP induces the initial hemiparkinsonian syndrome and the subsequent iv. doses (that can be administered as needed) lead to bilateral damage and the further depletion of DA. This model exhibits different levels of bilateral parkinsonism in which more prominent signs are seen in the limbs contralateral to ICA MPTP infusion. A positron emission tomography (PET) study of this model using the DA metabolic tracer, [ $^{18}\text{F}$ ] 6-fluoro-L-m-tyrosine (FMT), demonstrated a significant correlation between decreases in the striatal DA metabolism and the severity of parkinsonian signs (24). In the present report we further analyzed the relationships between the clinical PD stages, *in vivo* PET measures of DA metabolism, and postmortem biochemical and histochemical measurements.

## 3. MATERIALS AND METHODS

### 3.1. Subjects and treatments

All procedures were approved by Institutional Animal Care and Use Committee. Under surgical sterile conditions, twelve young adult rhesus monkeys (*Macaca mulatta*, 5 males and 7 females,  $5.4 \pm 1.1$  kg at the beginning of this experiment) received a single injection (rate: 4 ml/min) of 60 ml saline containing 2.5 mg of MPTP-HCl in the right carotid artery as described elsewhere (20). Each animal developed a hemiparkinsonian syndrome with bradykinesia, tremor, and rigidity on the extremities contralateral to ICA MPTP infusion. Four weeks after the ICA MPTP infusion, monkeys received 2-14 additional iv. doses of MPTP (0.3 mg/kg) in order to produce additional damage in the right hemisphere and varying levels of damage in the left hemisphere. Intravenous MPTP injections were continued twice a week until the monkeys developed stable bilateral parkinsonism. Once exhibiting bilateral parkinsonian signs, animals were observed for over 4 weeks. Monkeys showing behavioral recovery in the period of observation received additional iv. MPTP injections until they were clinically stable. Two additional untreated rhesus monkeys served as controls for the postmortem neurochemical and histochemical analysis.

### 3.2. Clinical Rating

A parkinsonian rating scale (PD scale) was used to quantify the clinical status of the monkeys as described previously (24). As shown in table 1, the scale indicates the sum of the 10 parkinsonian features. Animals are scored on a 43-point scale, with 0 corresponding to normal state, and 43 to extreme parkinsonism. A score of less than 10 indicates hemiparkinsonism (stage 1) which is not accompanied by bilateral signs of PD. A score between 10 and 15 indicates mild bilateral parkinsonism (stage 2), and

**Table 1.** Parkinsonian Rating Scale

1. Tremor (right arm/left arm)	
0 - absent	
1 - occasional, or barely detectable (normal for aged), occurring while active	
2 - frequent, or easily detectable, occurring while active or at rest	
3 - continuous, or intense, occurring while active and at rest	
2. Freezing	
0 - absent	
1 - occasional episodes of short duration (< 5 seconds)	
2 - occasional episodes of moderate duration (6 - 10 seconds)	
3 - frequent episodes or episodes of long duration (>10 seconds)	
3. Locomotion	
0 - uses all four limbs smoothly and symmetrically	
1 - walks slowly (normal for aged), noticeable limp	
2 - walks very slowly and with effort, may drag limb or refuse to bear weight	
3 - unable to ambulate	
4. Fine Motor Skills (right arm/left arm)	
0 - normal function - able to grasp/retrieve small objects, aims accurately, independent use	
1 - reduced ability in grasping/retrieving small objects, independent use, may have reduced aim	
2 - able to grasp small objects rarely, only with assistance, or with great difficulty	
3 - unable to grasp/retrieve small objects	
5. Bradykinesia (right arm/left arm)	
0 - quick, precise movements	
1 - mild slowing of movements (normal for aged)	
2 - slow deliberate movements with marked impairment initiating movements	
3 - no movements	
6. Hypokinesia	
0 - moves freely, alert, responsive	
1 - reduced activity (normal for aged), moves less frequently (without provocation)	
2 - minimal activity, moves with provocation, may have reduced facial expression	
3 - akinetic (essentially no movements)	
7. Balance	
0 - requires no assistance for maintaining posture	
1 - requires assistance for standing	
2 - requires assistance for walking, or falls	
3 - face down, or unable to maintain posture	
8. Posture	
0 - normal posture - stands erect	
1 - reduced posture - (normal for aged) - stands with feet apart, knees flexed	
2 - stooped posture - hunched, legs bent	
3 - unable to maintain posture, recumbent	
9. Startle Response	
0 - immediate, robust response to provocation	
1 - slightly diminished or delayed response - open mouth threat	
2 - minimal response or longer delay - without open mouth threat	
3 - no response to provocation	
10. Gross Motor Skills (right arm/ left arm)	
0- normal function - able to grasp/retrieve large objects accurately	
1- reduced ability/frequency grasping/retrieving large objects	
2- great difficulty grasping/retrieving large objects- rarely used	
3- unable to grasp/retrieve large objects	

a score over 16 indicates moderate bilateral parkinsonism (stage 3). The monkeys were rated at least once a week during the 6 months prior to sacrifice.

## 3.3. PET study

Animals were studied with PET 7-17 months following the last iv. dose of MPTP, and all showed stable parkinsonian signs. Prior to PET, each monkeys received a magnetic resonance (MR) imaging scan using a 1.5 T magnet and a stereotaxic frame which permitted co-registration between PET and MR data sets through the use of external fiducial markers. All monkeys were studied with PET using [<sup>18</sup>F] 6-fluoro-L-m-tyrosine (FMT), on a Siemens-CTI ECAT EXACT HR 47-slice scanner in 2D acquisition mode (25) using arterial catheterization for determination of blood input function and metabolites (26). FMT was produced by previously described methods (26). Each animal was injected with 10-15 mCi of FMT.

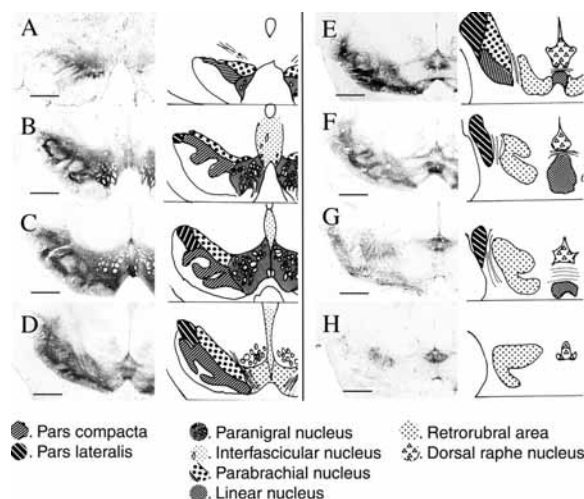
The PET and MR data-sets were co-registered and regions of interest (ROIs) were drawn on PET data with reference to the co-registered MR images. ROIs were drawn in both hemispheres for the caudate nucleus and putamen on each slice on which they appeared. After a series of 2-D ROIs were drawn, the surfaces of the ROIs were tiled together into a closed triangular mesh polyhedral surface model, defining a 3-D region, or volume of interest (VOI) (27). Regional activity density curves were constructed for each VOI using the dynamic PET data. A single exponential function for blood FMT metabolism, obtained from a fit of the blood metabolism of FMT for each animal, was applied to a decay corrected curve of total blood <sup>18</sup>F-activity for each animal. As previously described (26), a three compartment three kinetic rate constant model was constructed describing forward ( $k_1$ ) and reverse ( $k_2$ ) transport of FMT from blood into brain, as well as FMT metabolism ( $k_3$ ) in compartment 3 (FMT metabolites in brain). These rate constants were used to calculate an uptake constant for each VOI, describing the rate of FMT uptake ( $K_i$ ) during the 0 to 90 min period after FMT injection.

## 3.4. Necropsy and preparation of tissue

All the animals were euthanized 2-4 weeks following the PET procedure for postmortem biochemical and histochemical analysis, after they showed stable parkinsonian signs for 8 - 19 ( $11 \pm 4.8$ ) months after the last iv. MPTP injection. Monkeys were deeply anesthetized with sodium pentobarbital (25 mg/kg iv.) and then transcardially perfused with 500 ml of saline. The brains were rapidly removed and sliced into 2 mm coronal sections at the level of the mid-striatum using a calibrated brain slice apparatus. The slices were then frozen in dry ice and kept in a -80 °C freezer for biochemical assay. For histochemical analysis, the slabs were immersed for 48 h in 4% paraformaldehyde, then cryoprotected through graded sucrose (10-30%), and cut into 40 micron coronal sections by a cryostat after freezing in -80 °C isopentane.

## 3.5 Biochemical Assay

Samples (punches) of specific regions in the mid-striatum were obtained from the frozen slices. Punch



**Figure 1.** Tyrosine hydroxylase (TH) immunohistochemistry at eight different levels of the midbrain in a normal monkey. Drawing represents schematic of the groups of dopaminergic neurons. Cell group A9 (1), A8 (2), and A10 (3) are composed of (1): Substantia nigra pars compacta and pars lateralis, (2): retrorubral area and dorsal raphe nuclei, (3): parabrachial pigmented nucleus, paranigral nucleus, interfascicular nucleus and linear nucleus, respectively. Scale bar = 2 mm.

diameter was 1.5 mm. Punched regions were as follows: dorsolateral and ventromedial caudate nucleus (DC and VC, respectively), dorsolateral and ventromedial putamen (DP and VP, respectively), and nucleus accumbens. Each sample was sonicated in 200 microliters of homogenizing solution containing 0.1 M perchloric acid, 0.005% EDTA, and dihydroxybenzylamine as an internal standard, and then centrifuged at 15,000 rpm for 20 min at 4 °C. The separation and quantification of DA and its metabolite, homovanilic acid (HVA), were conducted by ion pair reverse-phase high performance liquid chromatography (HPLC) with electrochemical detection. A C18 octadecyl silica 3 micrometers minipore (3.2 X 100 mm) column (Varian, Walnut Creek, CA) was perfused with a MD-TM mobile phase (ESA, Chelmsford, MA) at a constant rate of 1 ml/min. A Coulochem II (ESA, Chelmsford, MA) electrochemical detector applied a -60 mV potential to electrode 1 and a +330 mV potential to electrode 2 of a coulometric analytical cell (model 5011). Following HPLC analysis, protein content in each tissue sample was determined using the Byword (Richmond, CA) so that DA and HVA levels could be expressed as ng/mg protein. HVA/DA ratios were created to evaluate DA utilization.

### 3.6. Histochemical study

For tyrosine hydroxylase (TH) immunohistochemistry, every 10th section at the level of the substantia nigra was washed in 0.1% phosphate buffered saline (PBS, pH 7.4), followed by blocking of the endogenous peroxidase with 3% H<sub>2</sub>O<sub>2</sub> for 30 min. After washing in distilled water and PBS, the sections were incubated in blocking solution (10% normal horse serum and 0.1% Triton-X 100 in PBS) for 30 min., and then incubated in the anti-TH antibody (mouse monoclonal,

Chemicon) at 1:1000 dilution for 24 h. The sections were then incubated for 1 h in the biotinylated anti-mouse IgG secondary antibody (Vector) in 1:300 dilution. The antibody binding was visualized with streptavidin horseradish peroxidase (1:300, Vector) and VIP chromogen (Vector). Sections were then coverslipped, and examined under light microscope.

Three major groups of dopaminergic cells were delimited according to numerical designations 8, 9, and 10 of the "A" series in the rat midbrain (28). Dopaminergic cell groups homologous to the group A8, A9, and A10 of the rat have also been described in human and non-human primates (29, 30, 31, 32, 33, 34, 35). The A9 cell group was composed of the substantia nigra pars compacta and pars lateralis. TH-immunoreactive (TH-IR) cells in the retrorubral area and the dorsal raphe nuclei were considered to be in the A8 group. The A10 cell group was composed of four nuclei: the parabrachial pigmented nucleus, the paranigral nucleus, the interfascicular nucleus and the linear nucleus. Eight sections of TH immunostaining were selected at each level as shown in figure 1 and projected with a projecting microscope (Ken-A-Vision Microprojector) at 40x magnification onto a sheet on a graphic tablet (ARTZ II, WACOM), and then drawings were made of the nuclei of group A8, A9, and A10. Numbers of TH-immunoreactive (IR) cells were counted using NIH Image1.6 program. TH-IR cell counts were summed over 8 sections for each cell group.

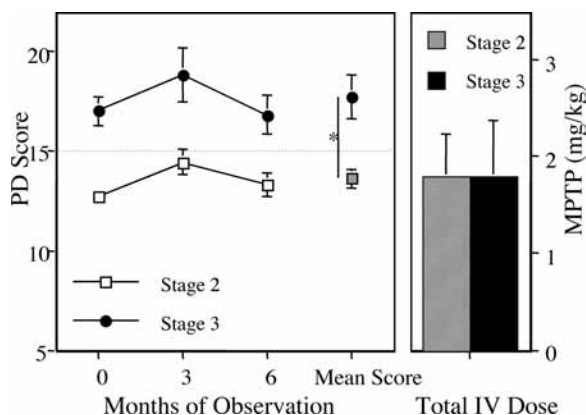
### 3.7. Data analysis

One-way ANOVA followed by Fisher's PLSD post-hoc tests were used to compare DA concentrations and TH-IR cell counts between the control, stage 2, and stage 3 animals. Correlation coefficient and the significance of the linear regression were calculated using the least-squared method. Linear regression was performed to determine the relationships between DA concentrations, midbrain TH-IR cell counts and PET measurements of FMT uptake (Ki).

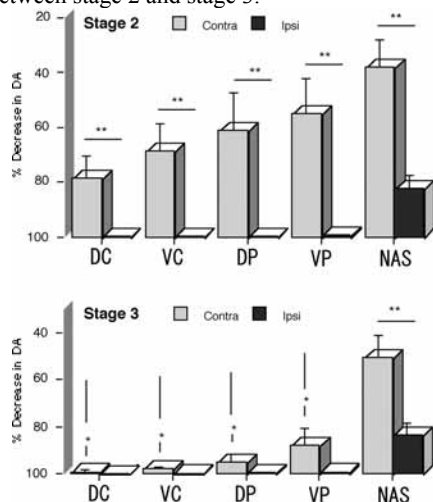
## 4. RESULTS

### 4.1. Behavioral changes

The animals receiving MPTP exhibited parkinsonism in their body trunks and limbs. Tremor, bradykinesia, and disturbance of motor skills were severe in the left (contralateral side of ICA MPTP infusion) arms, while different degrees of the symptoms were observed on their right arms. Eight monkeys were categorized as stage 2 and 4 monkeys as stage 3 by using the mean PD score for 6 months prior to sacrifice ( $13.6 \pm 0.5$  in stage 2 vs.  $17.7 \pm 1.1$  in stage 3,  $p < 0.05$ ). Each group showed stable parkinsonian signs (figure 2). As reported previously by others (4, 35, 35) the clinical response to iv. MPTP was not dose-dependent, there were no significant differences in the total iv. doses of MPTP between stage 2 and stage 3 monkeys. Asymmetry of tremor was more prominent in stage 2 than in stage 3 (37). Stage 3 monkeys showed more severe parkinsonism than stage 2 monkeys in startle response ( $0.8 \pm 0.1$  in stage 2 vs.  $1.4 \pm 0.2$  in stage 3,  $p < 0.05$ ), balance ( $1.1 \pm 0.1$  vs.  $1.6 \pm 0.2$ ,  $p < 0.05$ ) and freezing ( $0.0 \pm 0.0$  vs.  $0.9 \pm 0.5$ ,  $p < 0.05$ ).



**Figure 2.** (Left) Parkinsonian rating scale score (PD score) (mean  $\pm$  SEM) in stage 2 ( $n=7$ ) and stage 3 ( $n=5$ ) monkeys during observation period of 6 months prior to euthanasia. The monkeys were euthanized 8 - 19 ( $11 \pm 4.8$ ) months after the last iv. administration of MPTP. Unpaired t-test: \*  $P < 0.05$ , stage 2 compared to stage 3. (Right) Total iv. dose of MPTP (mean  $\pm$  SEM) in stage 2 and stage 3 monkeys. No significant difference in MPTP dose was seen between stage 2 and stage 3.



**Figure 3.** DA concentration (mean  $\pm$  SEM) in subregions of caudate nucleus and putamen, and nucleus accumbens ipsilateral and contralateral to ICA MPTP infusion in stage 2 ( $n=7$ ), stage 3 ( $n=5$ ), and normal ( $n=2$ ) monkeys (DC: dorsolateral caudate nucleus, VC: ventromedial caudate nucleus, DP: dorsolateral putamen, VP: ventromedial putamen, NAS: nucleus accumbens). One way ANOVA: \*  $P < 0.05$ , stage 2 compared to stage 3 in each striatal region. Paired t-test: \*\*  $P < 0.05$ , ipsilateral side compared to contralateral side of ICA MPTP injection in each stage.

#### 4.2. Neurochemical changes

Concentrations of DA and HVA (mean  $\pm$  SEM) in the caudate nucleus, putamen and nucleus accumbens of control and MPTP-treated monkeys are shown in table 2 and figure 3. In stage 2 and stage 3 monkeys, marked depletions of DA (> 99% loss) were observed in the subregions of the caudate nucleus and putamen on the side ipsilateral to ICA MPTP infusion, while DA loss was more moderate in the nucleus accumbens (82-84%). DA loss on the contralateral side was also significant in the subregions

of the caudate nucleus, putamen, and nucleus accumbens, but less extensive and more variable than on the ipsilateral side. The DA loss was more robust in the contralateral caudate and putamen of the stage 3 animals (88-99%) than those of the stage 2 (55-79%). HVA concentrations were also significantly decreased in the subregions of the ipsilateral striatum, as well as in the caudate nucleus on the contralateral side. Increases in DA utilization, calculated as HVA/DA ratio, were inversely related to the amount of DA concentration found in each region. DA utilization was elevated relative to controls in each subregion of the caudate nucleus and putamen ipsilateral to ICA MPTP infusion, while no significant elevation was observed in the contralateral striatum of the stage 2 animals.

#### 4.3. Histochemical changes

As shown in figure 4, TH-immunohistochemistry showed the greatest loss of TH-IR cells on the side ipsilateral to ICA MPTP infusion with relative preservation on the contralateral side in stage 2 and 3 animals. Quantitative analysis showed that the ipsilateral A9 cell number decreased to 9.7% and 11.0% of the control animals in stage 2 and 3, respectively. There were relative preservation of the A10 (52.4 and 54.3% of the control in stage 2 and 3, respectively) and A8 cells (68.0 and 58.3% of the control in stage 2 and 3, respectively) (figure 5). On the contralateral side, the loss of the A9 cells decreased with the severity of the syndrome (63.5% of the control in stage 2 vs. 24.5% of the control in stage 3,  $p < 0.05$ ), while the cells were preserved in the A10 (74.5% in stage 2 vs. 64.4% in stage 3,  $p > 0.05$ ) and A8 (93.5% in stage 2 vs. 62.9% in stage 3,  $p > 0.05$ ) groups.

#### 4.4. Correlations between clinical findings, striatal DA, TH-IR cell counts and PET FMT uptake

As we have previously reported in these animals (24), using PET and FMT we found a significant correlation between clinical measures of parkinsonism and DA metabolism. Further (see figure 6), Ki values for the caudate nucleus and putamen were significantly correlated with averages of DA concentration in the ventromedial and dorsolateral subregions of the caudate nucleus and putamen respectively ( $r = 0.63$ ,  $p < 0.05$  and  $r = 0.71$ ,  $p < 0.05$ ).

Figure 7 shows the correlation between TH-IR cell counts in cell group A9, A8 and A10 and PET Ki values of the caudate nucleus and putamen. TH-IR cell counts in cell group A9 showed a significant relationship with Ki values in the caudate nucleus ( $r = 0.83$ ,  $p < 0.0001$ ), and in the putamen ( $r = 0.93$ ,  $p < 0.0001$ ). TH-IR cell counts in cell groups A8 were also significantly correlated with DA concentrations in both the caudate ( $r = 0.69$ ,  $p = 0.002$ ) and putamen ( $r = 0.61$ ,  $p = 0.002$ ). Although significant, the correlation with cell group A10 was not as strong ( $r = 0.42$ - $0.49$ ,  $p < 0.05$ ).

### 5. DISCUSSION

#### 5.1. Nigrostriatal damage in the overlesioned hemiparkinsonian model

In the present study, combined administration of ICA and iv. doses of MPTP produced various degrees of

## Overlesioned hemiparkinsonian monkey model

**Table 2.** DA and HVA concentrations (mean  $\pm$  SEM) in the middle striatum measured by HPLC with electrochemical detection. DA utilization ratio was calculated by HVA/D

Brain Region	DA (ng/mg protein)		HVA (ng/mg protein)		DA utilization (HVA/DA)	
	<u>Ipsilateral</u>	<u>Contralateral</u>	<u>Ipsilateral</u>	<u>Contralateral</u>	<u>Ipsilateral</u>	<u>Contralateral</u>
Dorsal caudate						
Control	270.3 $\pm$ 34.1		184.4 $\pm$ 21.0		0.69 $\pm$ 0.02	
Stage 2	0.20 $\pm$ 0.05 <sup>a</sup>	57.8 $\pm$ 22.6 <sup>a</sup>	5.19 $\pm$ 0.60 <sup>a</sup>	132.9 $\pm$ 30.3	40.7 $\pm$ 12.0	4.69 $\pm$ 1.47
Stage 3	0.33 $\pm$ 0.14 <sup>a</sup>	2.27 $\pm$ 1.71 <sup>a,b</sup>	8.44 $\pm$ 1.19 <sup>a</sup>	43.1 $\pm$ 12.1 <sup>a,b</sup>	55.8 $\pm$ 22.3 <sup>a</sup>	71.7 $\pm$ 37.3 <sup>a,b</sup>
Ventral caudate						
Control	251.6 $\pm$ 11.7		212.0 $\pm$ 9.4		0.84 $\pm$ 0.03	
Stage 2	0.21 $\pm$ 0.05 <sup>a</sup>	78.9 $\pm$ 24.4 <sup>a</sup>	9.92 $\pm$ 1.92 <sup>a</sup>	152.5 $\pm$ 21.5 <sup>a</sup>	71.9 $\pm$ 23.1 <sup>a</sup>	6.01 $\pm$ 3.84
Stage 3	0.52 $\pm$ 0.13 <sup>a</sup>	5.38 $\pm$ 1.57 <sup>a,b</sup>	15.7 $\pm$ 4.7 <sup>a</sup>	59.9 $\pm$ 13.9 <sup>a,b</sup>	39.5 $\pm$ 16.4	19.9 $\pm$ 9.2
Dorsal putamen						
Control	259.6 $\pm$ 26.0		248.9 $\pm$ 17.3		0.98 $\pm$ 0.09	
Stage 2	0.69 $\pm$ 0.11 <sup>a</sup>	100.8 $\pm$ 35.5 <sup>a</sup>	12.3 $\pm$ 1.1 <sup>a</sup>	202.3 $\pm$ 35.6	21.2 $\pm$ 4.0 <sup>a</sup>	3.42 $\pm$ 0.86
Stage 3	0.97 $\pm$ 0.15 <sup>a</sup>	12.2 $\pm$ 9.9 <sup>a,b</sup>	16.8 $\pm$ 1.4 <sup>a</sup>	81.2 $\pm$ 27.9 <sup>a,b</sup>	19.2 $\pm$ 3.0 <sup>a</sup>	20.9 $\pm$ 6.9 <sup>a,b</sup>
Ventral putamen						
Control	219.6 $\pm$ 12.8		290.0 $\pm$ 37.1		1.35 $\pm$ 0.24	
Stage 2	1.34 $\pm$ 0.34 <sup>a</sup>	98.3 $\pm$ 28.0 <sup>a</sup>	35.3 $\pm$ 4.6 <sup>a</sup>	248.6 $\pm$ 37.3	35.1 $\pm$ 8.7 <sup>a</sup>	3.04 $\pm$ 0.38
Stage 3	1.77 $\pm$ 0.31 <sup>a</sup>	26.1 $\pm$ 16.2 <sup>a,b</sup>	33.4 $\pm$ 3.1 <sup>a</sup>	115.5 $\pm$ 29.7 <sup>a,b</sup>	21.4 $\pm$ 4.1	9.26 $\pm$ 3.02 <sup>a,b</sup>
Nucleus accumbens						
Control	159.0 $\pm$ 17.3		249.5 $\pm$ 26.9		1.66 $\pm$ 0.31	
Stage 2	28.3 $\pm$ 7.1 <sup>a</sup>	98.3 $\pm$ 25.7 <sup>a</sup>	77.5 $\pm$ 8.0 <sup>a</sup>	223.0 $\pm$ 29.1	3.58 $\pm$ 0.64	2.43 $\pm$ 0.27
Stage 3	25.8 $\pm$ 8.2 <sup>a</sup>	78.3 $\pm$ 25.3 <sup>a</sup>	82.8 $\pm$ 17.1 <sup>a</sup>	182.7 $\pm$ 30.1	3.71 $\pm$ 0.62	2.47 $\pm$ 0.22

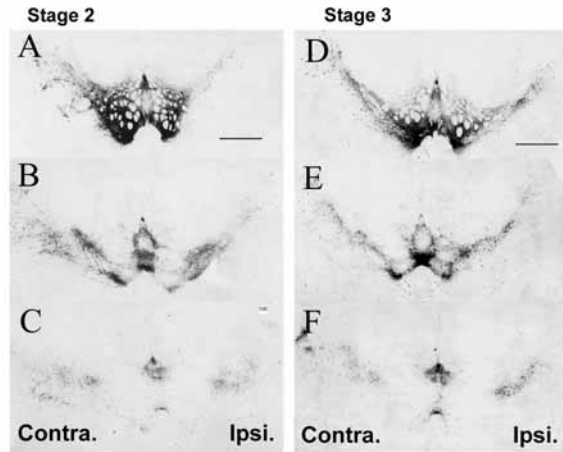
<sup>a</sup> p < 0.05 for comparison with control; <sup>b</sup> p < 0.05 for comparison with stage 2.

bilateral parkinsonism in rhesus monkeys. The monkeys exhibited severe parkinsonian signs in the limbs contralateral to ICA MPTP infusion, and also mild to moderate signs in the ipsilateral limbs. The postmortem biochemical analysis revealed that DA depletions were extensive (more than 99%) in the subregions of the caudate nucleus and putamen ipsilateral to ICA MPTP infusion, but more moderate and variable in the subregions of the contralateral striatum. Considering that the hemiparkinsonian syndrome induced by unilateral ICA MPTP infusion shows DA preservation in the contralateral striatum (20), the variability in DA levels observed in the contralateral hemisphere in the current study can be explained by the variability in clinical response to iv. injection of MPTP (4, 36, 37). Stage 3 monkeys showed significantly lower DA concentrations in the caudate nucleus and putamen contralateral to ICA MPTP infusion than stage 2 monkeys. The nucleus accumbens showed mild to moderate DA reduction on both sides compared to the caudate nucleus and putamen, with no significant differences between stage 2 and stage 3 monkeys. The immunohistochemical findings showed that the cell group A9 appears to be most susceptible to MPTP neurotoxicity. Significant differences between stage 2 and stage 3 animals were seen in the number of TH-IR cells in the contralateral A9 cells, while in the ipsilateral side the A9 cells showed extensive loss in all animals. Thus, clear relationships were demonstrated between the PD stages, striatal DA

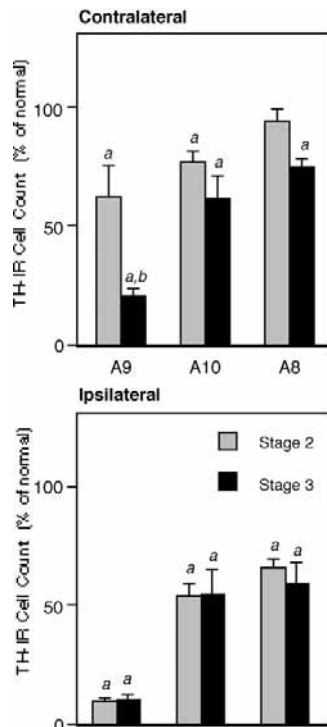
concentrations and nigral DA cell loss in the overlesioned hemiparkinsonian monkeys.

### 5.2. Nigrostriatal damage in MPTP primate models

Systemic administration of MPTP is characterized by individual variability to the neurotoxin. Further differences between published reports may be due to differences in regimens of MPTP administration and species of monkeys. Symptomatic animals with MPTP-induced parkinsonism generally show an extensive (more than 95%) decrease in striatal DA (1, 8, 9). However, a similar loss in striatal DA was also observed in vervet (8) and macaque (9, 37) monkeys which failed to show cardinal signs of parkinsonism after MPTP administration. Similarly, Schneider (39) showed that only deficits of cognitive function were induced in macaque monkeys with 93.7 - 97.9% DA reduction in the caudate nucleus and 89.1% reduction in the putamen by chronic treatment of low dose MPTP. These studies show that regional differences in striatal DA levels are quite small between symptomatic and asymptomatic animals. They also suggest that the putamen, which is relatively preserved in these mildly affected animals, and/or increases in DA utilization expressed as HVA/DA ratios may play a compensatory role in motor functions. However, Albanese and coworkers (40) described in the common marmoset that chronic regimen of low doses of MPTP during a period of 4 months produced progressive parkinsonism with DA loss in the



**Figure 4.** Representative photographs of tyrosine hydroxylase immunohistochemistry of the midbrain in stage 2 and 3 monkey. Panels A, B, and C of stage 2, and panels D, E, and F of stage 3 are corresponding to the level C, E, and G shown in figure 1, respectively. Ipsi.: the ipsilateral side of ICA MPTP infusion, Contra.: the contralateral side of ICA MPTP infusion. Scale bar = 2 mm.



**Figure 5.** Cell counts (% of normal, mean ± SEM) of tyrosine hydroxylase-immunoreactive (TH-IR) neurons of the stage 2 and 3 animals. One way ANOVA: <sup>a</sup>  $P < 0.05$ , compared to control. <sup>b</sup>  $P < 0.05$ , stage 3 compared to stage 2.

striatum of approximately 50%. They suggested that little change in DA turnover resulting from inhibitory action of MPTP on TH or monoamine oxidase accounted for the presence of symptoms with relative DA preservation. In that regard, Bezard and collaborators (41) reported in a

progressive PD model that onset of the symptoms occurred with approximately 80% loss of striatal DA metabolism, associated with the failure of up-regulation of postsynaptic receptors. In the current study, there were no significant elevations in HVA/DA ratios in the contralateral striatum of stage 2 monkeys, while DA was relatively preserved (68.6 - 78.6% loss in the caudate nucleus and 55.2 - 61.2% loss in the putamen), suggesting that compensatory mechanisms were insufficient for the preservation of motor function. Analysis of the impact of DA dysfunction in the other areas beyond the nigrostriatal pathway may be necessary for alternative explanations of the symptoms. For example, tremor, most commonly observed in the bilateral limbs of stage 2 monkeys, may be related to functional changes in the globus pallidus (42, 43, 44) and the nucleus accumbens, where DA activity is involved in motivational significance and motor activity (45, 46).

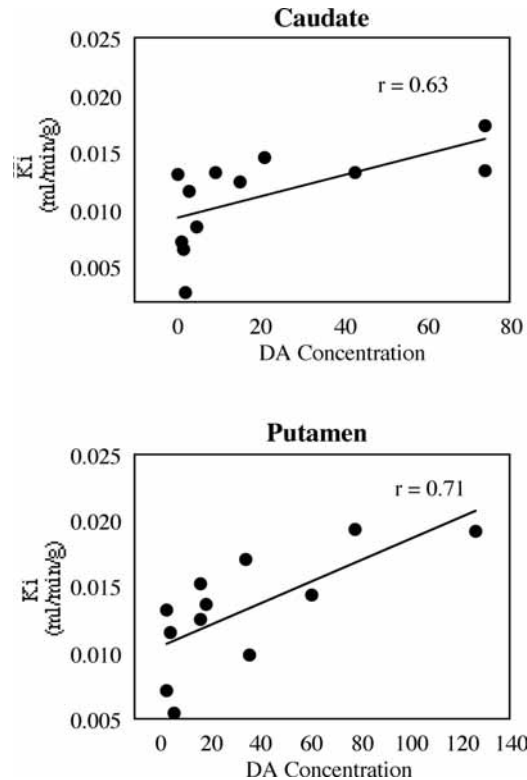
### 5.3. Correlation between in vivo and postmortem measurements

The use of PET and the DA metabolic tracer, FMT, enables the *in vivo* visualization of striatal DA deficiency in experimental studies (26, 47, 48, 49, 50). In parkinsonian MPTP-treated monkeys, reductions in uptake of [<sup>18</sup>F]6-fluoro-L-dopa (FDOPA) are associated with behavioral changes (48) and reductions in striatal DA concentration (50). Other PET studies (51, 52) demonstrated DA metabolism decreased in asymptomatic monkeys exposed to low doses of MPTP and suggested that a 30% reduction in DA metabolism was critical for the induction of parkinsonian symptoms. The same group of animals reported here was examined by PET and FMT previously and showed significant differences in DA metabolism between stage 2 and stage 3 (24). We further show in the current report that the rate of FMT uptake ( $K_i$  value) is a significant predictor of DA concentrations in the striatum.

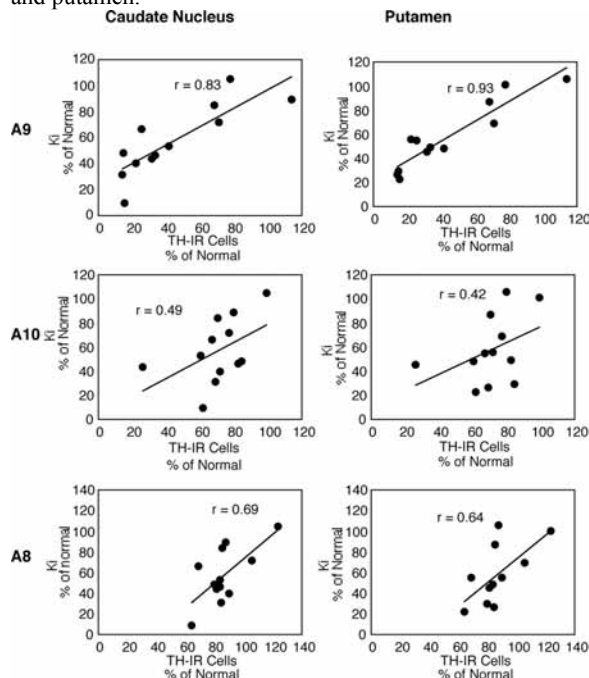
Relationships between the PET data in the striatum and the midbrain histochemistry were also confirmed in this study. The current data show a significant correlation between TH-IR cell counts in each cell group and DA losses in the caudate nucleus and putamen, indicating that MPTP affected the populations of all 3 cell groups contributing to dopaminergic innervation of the caudate nucleus and putamen. This finding is supported by morphological evidence that not only the A9 cell group but also A8 and A10 give rise to the nigrostriatal system with different degrees of dopaminergic innervation (53). Since the clinical rating correlates with both PET imaging and post-mortem measures in this model, the clinical rating score can be used to predict the extent of the lesion.

### 5.4. Functional recovery in MPTP primate models

Variability in functional recovery after MPTP treatment has previously been reported in monkeys. Considerable recovery was observed during several months after acute systemic administration of MPTP in common marmoset (12, 54) and macaque monkeys (37). However, Taylor *et al.* (55) observed persistent long-term deficits in vervet monkeys with acute administration of MPTP, and described that the initial severity was an important predicting factor for functional recovery. Chronic MPTP



**Figure 6.** The relationship between PET measures of FMT uptake ( $K_i$ ) and dopamine concentration in the contralateral (the side opposite of ICA MPTP infusion) caudate nucleus and putamen.



**Figure 7.** The relationship between PET measures of FMT uptake ( $K_i$ ) in the contralateral (the side opposite of ICA MPTP infusion) putamen and tyrosine hydroxylase immunoreactive (TH-IR) cell counts in the contralateral cell groups. Higher  $K_i$  values were associated with a greater number of TH-IR cells in A9 and A8 groups.

administration produces slow progression of symptoms, but behavioral recovery is also observed after ceasing MPTP (40, 56). The functional impairment and recovery are quite complex and care needs to be taken for behavioral assessment, based on the evidence that degrees of recovery of motor and cognitive function are quite different depending upon the tests used to assess function (57). Further, repeated high doses of MPTP may be necessary to avoid spontaneous recovery.

Following ICA MPTP infusion, hemiparkinsonian monkeys showed various degrees of recovery in spontaneous and task-related behaviors (57, 58). Interestingly hemiparkinsonian monkeys presenting a unilateral syndrome with impaired fine motor skills in the first week post ICA MPTP infusion, have been reported to display a stable syndrome for a period of 6-8 years (59). Nevertheless, this unilateral syndrome lacks the bilateral characteristics that may be required in studies focusing on advanced PD. Bilateral ICA MPTP infusions that induce a bilateral parkinsonian syndrome showed persisting stable motor deficits during a period of 12 months (60), but inherent to this model is the risk of severely and acutely impairing the animals, incapacitating them to take care of their basic needs. Using the overlesioned hemiparkinsonian model, we found that if the symptoms persisted for a period of 4 weeks, the animals were likely to continue to present a stable parkinsonian syndrome, suggesting that this model is appropriate for studies of therapeutic interventions for advanced PD.

### 5.5. Relevance to human PD

In idiopathic human PD, striatal DA losses have been shown to be heterogeneous, with more marked reductions in the putamen and dorsal caudate nucleus than in other parts of the striatum (7, 10, 11, 12, 61). The motor deficits in PD patients may result mostly from the disruption of dopaminergic innervation in the post commissural putamen, while the ventral caudate nucleus, which is proposed to be involved in cognitive function, tends to be preserved in PD at least in the beginning of the disease. MPTP-treated monkeys do not mimic this regional pattern of DA deficiency. In that regard, administration of low doses of MPTP to monkeys induces impaired cognitive function despite preservation of gross motor performance (45).

Studies of the substantia nigra in idiopathic PD describe a 30 to 80% loss of pigmented neurons (12, 13, 14, 62, 63, 64, 65). Different reports have shown a correlation between neuronal loss in the substantia nigra and DA deficiency in the caudate nucleus and putamen (7). These changes were also associated with clinical signs of rigidity and hypokinesia (65, 66) and the duration and the stage of the disease (63). As observed in the current study, PD showed susceptibility in all of the cell groups which project to the striatum (14, 15, 67). Thus, it is possible that cell losses of A8 and A10 also correlate with the severity of DA disruption in the striatum, however there have not been any quantitative studies addressing this issue.

### 5.6. Utility of the model for translational studies

The overlesioned hemiparkinsonian monkey model has several advantages over other models. It is a practical model in which animals are very seldom affected



## Overlesioned hemiparkinsonian monkey model

by MPTP to the extent that they cannot take care of themselves. The success rate of the model is very high. Typically 80-90% of animals that are enrolled into the project are considered good study subjects, and the mortality rate is very low. Scientifically, this model is particularly useful because it enables approximations of several stages of PD. Monkeys defined as stage 1 and 2 are good for studies of mild stages of PD, while stage 3 animals represent a more advanced stage of the idiopathic disease. Because in this model the clinical stage correlates with biochemical markers (PET /dopamine punch analysis) and midbrain DA cell counts it is possible to predict the degree of the lesion on the side contralateral to the ICA MPTP administration based on the clinical rating. In addition, three different types of therapeutic approaches can be addressed with the overlesioned model:

**Neuroprotection:** Agents that might protect dopaminergic cells from further MPTP toxicity can be studied using monkeys in stage 1 and 2. If such agents are indeed neuroprotective, further i.v. MPTP administration will induce stage 3 parkinsonism only in a placebo control group. This is more clinically relevant than the administration of the neuroprotective agent to normal animals prior to MPTP administration, since in clinical situations neuroprotection might be used in patients with sub-clinical and/or mild parkinsonism.

**Regeneration:** Therapeutic strategies aimed at improving the function of remaining dopaminergic innervation can be studied in stage 3 monkeys, since dopamine is only partially depleted on the side contralateral to the ICA infusion. If such an approach works, treated animals will move from stage 3 to stage 1 or 2.

**Neurorestoration:** This model is of particular use for studies of neurorestoration such as neurografting with primary fetal or stem cells and gene therapy. Due to severe DA depletion on the side ipsilateral to MPTP ICA administration, restored DA innervation can be examined independent of host response.

### 5.7. Conclusion

Non human primate models of PD induced by MPTP administration are useful to further understand human PD. PD characteristically presents different stages related to the progressive deterioration of the nigrostriatal DA system. The overlesioned hemiparkinsonian model induced by ICA and subsequent iv. administration of MPTP results in stable monkey models which can mimic several stages of PD. This model closely resembles PD and is a useful tool to analyze PD and to assist in the development and evaluation of potential new therapies for this disease. Since there are clear correlations between clinical stage and biochemical and histological markers in this model, the extent of the lesion can be determined based on the clinical rating.

### 6. ACKNOWLEDGMENTS

Supported by the Laboratory Technology Applications Division (formerly ER LTT), Office of

Energy Research, US Department of Energy under a CRADA (Cooperative Research and Development Agreement) between Lawrence Berkeley National Laboratory and Somatix Therapy Corporation, Alameda, CA under US DOE Contract DE-AC03-76SF00098. We would like to thank Dr. Brian A. Horger, Genentech, South San Francisco, CA, and Alex Cummins of NINDS, NIH, Bethesda, MD, for their contribution to biochemical and histological analysis.

### 7. REFERENCES

1. Burns, R.S., C.C. Chiueh, S.P. Markey, M.H. Ebert, D.M. Jacobowitz & I.J. Kopin: A primate model of parkinsonism: Selective destruction of dopaminergic neurons in the pars compacta of the substantia nigra by N-methyl-4-phenyl-1,2,3,6-tetrahydropyridine. *Proc Natl Acad Sci USA* 80, 4546-4550 (1983)
2. Langston, J.W., P.A. Ballard, J.W. Tetrud & I. Irwin: Chronic Parkinsonism in humans due to a product of meperidine-analog synthesis. *Science* 219, 979-980 (1983)
3. Langston, J.W., L.S. Forno, C.S. Rebert & I. Irwin: Selective nigral toxicity after systemic administration of 1-methyl-4-phenyl-1,2,3,6-tetrahydropyridine (MPTP) in the squirrel monkey. *Brain Res* 292, 390-394 (1984)
4. Elsworth, J.D., A.Y. Deutch, D.E. Redmond Jr., J.R. Sladek Jr. & R.H. Roth: Effects of 1-methyl-4-phenyl-1,2,3,6-tetrahydropyridine (MPTP) on catecholamines and metabolites in primate brain and CSF. *Brain Res* 415, 293-299 (1987)
5. German, D.C., M. Dubach, S. Askari, S.G. Speciale & D.M. Bowden: 1-Methyl-4-phenyl-1,2,3,6-tetrahydropyridine-induced parkinsonian syndrome in *Macaca fascicularis*: which midbrain dopaminergic neurons are lost? *Neuroscience* 24, 161-174 (1988)
6. Agid, Y: Parkinson's disease: Pathophysiology. *Lancet* 337, 1321-1324 (1991)
7. Bernheimer, H., W. Birkmayer, O. Hornykiewicz, K. Jellinger & F. Seitelberger: Brain dopamine and the syndromes of Parkinson and Huntington: Clinical, morphological and neurochemical correlates. *J Neurol Sci* 20, 415-455 (1973)
8. Elsworth, J.D., A.Y. Deutch, D.E. Redmond Jr., J.R. Taylor, J.R. Sladek Jr. & R.H. Roth: Symptomatic and asymptomatic 1-methyl-4-phenyl-1,2,3,6-tetrahydropyridine-treated primates: biochemical changes in striatal regions. *Neuroscience* 33, 323-331 (1989)
9. Pifl, C.H., G. Schingnitz & O. Hornykiewicz: Effect of 1-methyl-4-phenyl-1,2,3,6-tetrahydropyridine on the regional distribution of brain monoamine in the rhesus monkey. *Neuroscience* 44, 591-605 (1991)
10. Kish, S.J., K. Shannak & O. Hornykiewicz: Uneven pattern of dopamine loss in the striatum of patients with

## Overlesioned hemiparkinsonian monkey model

idiopathic Parkinson's disease. *N Engl J Med* 318, 876-880 (1988)

11. Pifl, C.H., G. Schingnitz & O. Hornykiewicz: The neurotoxin MPTP does not reproduce in the rhesus monkey the interregional pattern of striatal dopamine loss typical of human idiopathic Parkinson's disease. *Neurosci Lett* 92, 228-233 (1988)

12. Waters, C.M., S.P. Hunt, P. Jenner & C.D. Marsden: An immunohistochemical study of the acute and long-term effects of 1-methyl-4-phenyl-1,2,3,6-tetrahydropyridine in the marmoset. *Neuroscience* 23: 1025-1039 (1987)

13. Bogerts, B., J. Hantsch & M. Herzer: A morphometric study of the dopamine-containing cell groups in the mesencephalon of normals, Parkinson patients, and schizophrenics. *Biol Psychiat* 18, 951-69 (1983)

14. Hirsch, E., A.M. Graybiel & Y.A. Agid: Melanized dopaminergic neurons are differentially susceptible to degeneration in Parkinson's disease. *Nature* 334, 345-348 (1988)

15. Javoy-Agid, F. & Y. Agid: Is the mesocortical dopaminergic system involved in Parkinson's disease? *Neurology* 30, 1326-1330 (1980)

16. Schneider, J.S., A. Yuwiler & C.H. Markham: Selective loss of subpopulations of ventral mesencephalic dopaminergic neurons in the monkey following exposure of MPTP. *Brain Res* 411, 144-150 (1987)

17. Chiueh, C., R. Burns, S. Markey, D. Jacobowitz & I. Kopin: Primate model of parkinsonism: selective lesion of nigrostriatal neurons by 1-methyl-4-phenyl-1,2,3,6-tetrahydropyridine produces an extrapyramidal syndrome in rhesus monkeys. *Life Sci* 36, 213-218 (1985)

18. Deutch, A.Y., J.D. Elsworth, M. Goldstein, K. Fuxe, D.E.J. Redmond, J.R.J. Sladek & R.H. Roth: Preferential vulnerability of A8 dopamine neurons in the primate to the neurotoxin 1-methyl-4-phenyl-1,2,3,6-tetrahydropyridine. *Neurosci Lett* 68, 51-56 (1986)

19. Kitt, C.A., L.C. Cork, F. Eidelberg, T.H. Joh & D.L. Price: Injury of nigral neurons exposed to 1-methyl-4-phenyl-1,2,3,6-tetrahydropyridine: a tyrosin hydroxylase immunocytochemical study in monkey. *Neuroscience* 17, 1089-1103 (1986)

20. Bankiewicz, K.S., E.H. Oldfield, C.C. Chiueh, D.M. Dopman, D.M. Jacobowitz & I.J. Kopin: Hemiparkinsonism in monkeys after unilateral internal carotid artery infusion of 1-methyl-4-phenyl-1,2,3,6-tetrahydropyridine (MPTP). *Life Sci* 39, 7-16 (1986)

21. Smith, R.D., Z. Zhang, R. Kurlan, M. McDermott & D.M. Gash: Developing a stable bilateral model of parkinsonism in rhesus monkeys. *Neuroscience* 52, 7-16 (1993)

22. Bankiewicz, K.S., M.E. Emborg, W.W. McLaughlin, P.J. Pivrotto, J.R. Bringas, R.S. Hundal, B.Y. Yang, D. Nagy, R. Snyder, S.Z. Zhou, J.L. Eberling & W.J. Jagust: Utilization of a non-human model of Parkinson's disease for therapeutic applications of gene therapy. *Exp Neurol* 145, S15 (1997)

23. Bankiewicz, K.S., R.S. Hundal, P.J. Pivrotto, W.W. McLaughlin, J.R. Bringas, B.Y. Yang, M.E. Emborg, F.F. Wu & I. Irwin: 1997. Behavioral and biochemical changes in MPTP-treated monkeys after L-dopa administration. *Exp Neurol* 145, S14 (1997)

24. Eberling, J.L., W.J. Jagust, S. Taylor, J. Bringas, P. Pivrotto, H.F. VanBrocklin & K.S. Bankiewicz: A novel MPTP primate model of Parkinson's disease: Neurochemical and clinical changes. *Brain Res* 805, 259-262 (1998)

25. Wienhard, K., M. Dahlbom, L. Eriksson, C. Michel, T. Bruckbauer, U. Pietrzyk & W.-D. Heiss: The ECAT EXACT HR: Performance of a new high resolution positron scanner. *J Comput Assist Tomogr* 18, 110-118 (1994)

26. Jordan, S., J.L. Eberling, K.S. Bankiewicz, D. Rosenberg, P.G. Coxson, H.F. VanBrocklin, J.P. O'Neil, M.E. Emborg & W.J. Jagust: 6-[18F]fluoro-L-m-tyrosine: Metabolism, PET kinetics, and MPTP lesions in primates. *Brain Res* 750, 264-276 (1997)

27. Klein, G.J., X. Teng, W.J. Jagust, J.L. Eberling, A. Acharya, B.W. Reutter & R.H. Huesman: A methodology for specifying PET volumes-of-interest using multi-modality techniques. *IEEE Trans Med Imag* 16, 405-415 (1997)

28. Dahlström, A. & K. Fuxe: Evidence for the existence of monoamine-containing neurons in the central nervous system. *Acta Physiol Scand* 62, 1-55 (1964)

29. Garver, D.L. & J.R. Sladek Jr.: Monoamine distribution in primate brain. I Catecholamine-containing perikarya in the brain stem of *Macaca speciosa*. *J Comp Neurol* 159, 289-304 (1975)

30. Schofield, S.P. & B.J. Everitt: The organization of catecholamine-containing neurons in the brain of the rhesus monkey (*Macaca mulatta*). *J Anat* 132, 391-418 (1981)

31. Tanaka, C., M. Ishikawa & S. Shimada: Histochemical mapping of catecholaminergic neurons and their ascending fiber pathways in the rhesus monkey brain. *Brain Res Bull* 9, 255-270 (1982)

32. Poirier LJ, Giguère M, Marchand R: Comparative morphology of the substantia nigra and ventral tegmental area in the monkey, cat and rat. *Brain Res Bull* 11, 371-391 (1983)

33. Pearson, J., M. Goldstein, K. Markey & L. Brandeis: Human brainstem catecholaminergic neuronal anatomy as

## Overlesioned hemiparkinsonian monkey model

indicated by immunocytochemistry with antibodies to tyrosine hydroxylase. *Neuroscience* 8, 3-32 (1983)

34. Halliday, G.M. & I. Törk: Comparative anatomy of the ventromedial mesencephalic tegmentum in the rat, cat, monkey and human. *J Comp Neurol* 252, 423-445 (1986)

35. Domburg, P.H.M.F.van & H.J.ten Donkelaar: The human substantia nigra and ventral tegmental area: A neuroanatomical study with notes on aging and aging diseases. *Advances in anatomy, embryology, and cell biology*. Springer-Verlag, New York 121 (1991)

36. DiPaolo, T., P. Bedard, M. Diagle & R. Boucher: Long-term effects of MPTP on central and peripheral catecholamine and indoleamine concentrations in monkeys. *Brain Res* 379, 286-293 (1986)

37. Eidelberg, E., B.A. Brooks, W.W. Morgan, J.G. Walden & R.H. Kokemoor: Variability and functional recovery in the N-methyl-4-phenyl-1,2,3,6-tetrahydropyridine model of parkinsonism in monkeys. *Neuroscience* 18, 817-822 (1986)

38. Eberling, J.L., P. Pivrotto, J. Bringas & K.S. Bankiewicz: Tremor is associated with PET measures of nigrostriatal dopamine function in MPTP-lesioned monkeys. *Exp Neurol* 165, 342-346 (2000)

39. Schneider, J.S.: Chronic exposure to low doses of MPTP. II. Neurochemical and pathological consequences in cognitively-impaired, motor asymptomatic monkeys. *Brain Res* 534, 25-36 (1990)

40. Albanese, A., R. Granata, B. Gregori, M.P. Piccardi, C. Colosimo & P. Tonali: Chronic administration of 1-methyl-4-phenyl-1,2,3,6-tetrahydropyridine to monkeys: behavioral, morphological and biochemical correlates. *Neuroscience* 55, 823-832 (1993)

41. Bezard, E., S. Dovero, C. Prunier, P. Ravenscraft, S. Chalon, D. Guilloteau, A.R. Crossman, B. Bioulac, J.M. Brotchie, & C.F. Gross: Relationship between the appearance of symptoms and the level of nigrostriatal degeneration in a progressive 1-methyl-4-phenyl-1,2,3,6-tetrahydropyridine-lesioned macaque model of Parkinson's disease. *J Neurol* 21, 6853-6861 (2001)

42. Bagmen, T., B. Carmine & M.R. DeLong: Parkinsonian tremor is associated with low frequency neuronal oscillations in selective loops of the basal ganglia. *Adv Behav Biol* 41, 317-325 (1994)

43. Bergman, H., T. Wichmann & M.R. DeLong: Reversal of experimental parkinsonism by lesions of subthalamic nucleus. *Science* 249, 1436-1438 (1990)

44. Guridi, J., M.T. Herrero, M.R. Luquin, J. Guillein, M. Ruberg, J. Laguna, M. Vila, F. Javoy-Agid, Y. Agid, E. Hirsch & J.A. Obeso: 1996. Subthalamotomy in parkinsonian monkeys. Behavioural and biochemical analysis. *Brain* 119, 1717-1727 (1996)

45. Salamore, J.D.: The behavioral neurochemistry of motivation: methodological and conceptual issues in studies of the dynamic activity of nucleus accumbens dopamine. *J Neurosci Meth* 64, 137-149 (1996)

46. Wilson, C., G.G. Nomikos, M. Collu & H.C. Fibiger: Dopaminergic correlates of motivated behavior: importance of drive. *J Neurosci* 15, 5169-5178 (1995)

47. Eberling, J.L., K.S. Bankiewicz, S. Jordan, H.F. VanBrocklin & W.J. Jagust: PET studies of functional compensation in a primate model of Parkinson's disease. *NeuroReport* 8, 2727-2733 (1997)

48. Melega, W.P., J.M. Hoffman, J.S. Schneider, M.E. Phelps & J.R. Barrio: 6-[18F]fluoro-L-dopa metabolism in MPTP-treated monkeys: assessment of tracer methodologies for positron emission tomography. *Brain Res* 543, 271-276 (1991)

49. Melega, W.P., M.J. Raleigh, D.B. Stout, A.A. DeSalles, S.R. Cherry, M. Blurton-Jones, G.G. Morton, S.C. Huang & M.E. Phelps: Longitudinal behavioral and 6-[18F]fluoro-L-DOPA-PET assessment in MPTP-hemiparkinsonian monkeys. *Exp Neurol* 141, 318-329 (1996)

50. Pate, B.D., T. Kawamata, T. Yamada, E.G. McGeer, K.A. Hewitt, B.J. Snow, T.J. Ruth & D.B. Calne: Correlation of striatal fluorodopa uptake in the MPTP monkey with dopaminergic indices. *Ann Neurol* 34, 331-338 (1993)

51. Doudet, D.J., H. Miyake, R.T. Finn, C.A. McLellan, T.G. Aigner, R.Q. Wan, H.R. Adams & R.M. Cohen: 6-18F-L-dopa imaging of the dopamine neostriatal system in normal and clinically normal MPTP-treated rhesus monkeys. *Exp Brain Res* 78, 69-80 (1989)

52. Wullner, U., P. Pakzaban, A.L. Brownell, P. Hantraye, L. Burns & T. Shoup: Dopamine terminal loss and onset of motor symptoms in MPTP-treated monkeys: a positron emission tomography study with 11C-CFT. *Exp Neurol* 126, 305-309 (1994)

53. Jimenez-Castellanos, J. & A.M. Graybiel: Subdivisions of the dopamine-containing A8-A9-A10 complex identified by their differential mesostriatal innervation of striosomes and extrastriosomal matrix. *Neuroscience* 23, 223-242 (1987)

54. Ueki, A., P.N. Chong, A. Albanese, S. Rose, J.K. Chivers, P. Jenner and C.D. Marsden: Further treatment with MPTP does not produce parkinsonism in marmosets showing behavioral recovery from motor deficits induced by an earlier exposure to the toxin. *Neuropharmacology* 28, 1089-1097 (1989)

55. Taylor, J.R., J.D. Elthworth, R.H. Roth, J.R. Sladek Jr. & D.E. Redmond Jr.: Severe long-term 1-methyl-4-phenyl-1,2,3,6-tetrahydropyridine-induced parkinsonism in the vervet monkey (*cercopithecus aethiops sabaeus*). *Neuroscience* 81, 745-755 (1997)

## Overlesioned hemiparkinsonian monkey model

56. Bezard, E., C. Imbert, X. Deloire, B. Bioulac & C.E. Gross: A chronic MPTP model reproducing the slow evolution of Parkinson's disease: evolution of motor symptoms in the monkey. *Brain Res* 766, 107-112 (1997)

57. Schneider, J.S., T.I. Lidsky, T.Hawks, J.C. Mazziotta & J.M. Hoffman: Differential recovery of volitional motor function, lateralized cognitive function, dopamine agonist-induced rotation and dopaminergic parameters in monkeys made hemi-parkinsonism by intracarotid MPTP infusion. *Brain Res* 672, 112-127 (1995)

58. Kurlan, R., H. Michael, B.A. Kim & D.M. Gash: The time course and magnitude of spontaneous recovery of parkinsonism produced by intracarotid administration of 1-methyl-4-phenyl-1,2,3,6-tetrahydropyridine to monkeys. *Ann Neurol* 29, 677-679 (1991)

59. Emborg-Knott, M.E. & E.F. Domino: MPTP-Induced hemiparkinsonism in nonhuman primates 6-8 years after a single unilateral intracarotid dose. *Exp Neurol* 152, 214-20 (1998)

60. Smith, R.D., Z. Zhang, R. Kurlan, M. McDermott & D.M. Gash: Developing a stable bilateral model of parkinsonism in rhesus monkeys. *Neuroscience* 52, 7-16 (1993)

61. Murray, A.M., F.B. Weihmueller, J.F. Marshall, H.I. Hurtig, G.L. Gottlieb & J.N. Joyce: Damage to dopamine system differs between Parkinson's disease and Alzheimer's disease with parkinsonism. *Ann Neurol* 37, 300-312 (1995)

62. Halliday, G.M., Y.W. Li, P.C. Blumberg, T.H. Joh, R.G.H. Cotton, P.R.C. Howe, W.W. Blessing & L.B. Gerfen: Neuropathology of immunohistochemically identified brainstem neurons in Parkinson's disease. *Ann Neurol* 27, 373-385 (1990)

63. Ma, S.Y., M. R  ytt  , J.O. Rinne, Y. Collan & U.K. Rinne: Correlation between neuromorphometry in the substantia nigra and clinical features in Parkinson's disease using disector counts. *J Neurol Sci* 151, 83-87 (1997)

64. Pakkenberg B, A. M  ller, H.J.G. Gundersen, A. Mouritzen Dam & H. Pakkenberg: The absolute number of nerve cells in substantia nigra in normal subjects and in patients with Parkinson's disease estimated with an unbiased stereological method. *J Neurol Neurosurg Psychiatry* 54, 30-33 (1991)

65. Rinne, J.O., J. Rummukainen, L. Paljarvi & U.K. Rinne: Dementia in Parkinson's disease is related to neuronal loss in the medial substantia nigra. *Ann Neurol* 26, 47-50 (1989)

66. Paulus, W. & K. Jellinger: The neuropathologic basis of different clinical subgroups of Parkinson's disease. *J Neuropathol Exp Neurol* 50, 743-755 (1991)

67. German, D.C., K. Manaye, W.K. Smith, D.J. Woodward & C.B. Saper: Midbrain dopaminergic cell loss in Parkinson's disease: Computer visualization. *Ann Neurol* 26, 507-514 (1989)

**Key Words:** Monkey, Dopamine, PET, Tyrosine hydroxylase, MPTP, Parkinson's disease

**Send correspondence to:** Krys Bankiewicz, M.D., Ph.D., University of California, San Francisco, Neurological Surgery. Mission Center Building 0555, 1855 Folsom Street, Room 230, San Francisco, CA 94103. Tel: 415-502-3132, Fax: 415-514-2777, E-mail: kbank@itsa.ucsf.edu