

## NEOADJUVANT CHEMORADIATION FOR ADENOCARCINOMA OF THE PANCREAS

Tara M. Breslin, Nora A. Janjan, Jeffrey E. Lee, Peter W. T. Pisters, Robert A. Wolff, James L. Abbruzzese, Douglas B. Evans

*Departments of Surgical Oncology (TMB, JEL, PWTP, DBE), Radiation Oncology (NAJ), and Gastrointestinal Oncology and Digestive Diseases (RAW, JLA), The University of Texas M. D. Anderson Cancer Center, Houston, TX*

Received 6/4/98 Accepted 5/5/98

### TABLE OF CONTENTS

1. Abstract
2. Introduction
3. Pretreatment Radiographic Staging
4. Surgical Technique
5. Pathologic Assessment of Surgical Specimens
6. Multimodality Treatment Strategies
7. Newer Radiation Sensitizing Agents
8. Perspective
9. Acknowledgement
10. References

### 1. ABSTRACT

Adjuvant 5-fluorouracil and concurrent radiation may improve survival following complete surgical resection in patients with pancreatic adenocarcinoma. However, the morbidity and prolonged recovery associated with pancreaticoduodenectomy frequently prevents the timely delivery of postoperative chemoradiation. Therefore, the University of Texas M.D. Anderson Cancer Center (MDACC) has investigated the use of neoadjuvant chemoradiation in potentially resectable pancreatic cancer. We have incorporated a standardized approach to pretreatment staging, operative technique and pathologic evaluation. Our initial experience suggests that preoperative chemoradiation is well tolerated and may reduce loco-regional recurrence. Patients treated with rapid-fractionation preoperative chemoradiation had a significantly shorter duration of treatment compared with patients who received postoperative chemoradiation or standard-fractionation preoperative chemoradiation. New and more potent radiation-sensitizing agents such as gemcitabine may further enhance local control. Novel therapies directed at specific molecular events involved in pancreatic tumorigenesis may be incorporated into preoperative and postoperative regimens to attempt to reduce systemic relapse.

### 2. INTRODUCTION

Clinical research in pancreatic adenocarcinoma at the University of Texas M. D. Anderson Cancer Center (MDACC) has focused on the development of treatment strategies to improve local-regional tumor control, minimize treatment related toxicity, and maximize survival duration for patients with potentially resectable disease. Patients who undergo pancreaticoduodenectomy alone for adenocarcinoma of the pancreatic head or uncinate process have a median survival of 12 months, and a high incidence of local tumor recurrence (50% - 80%) due to the common finding of positive margins following pathologic evaluation of pancreaticoduodenectomy specimens (1). The available prospective and retrospective data suggests improved survival duration and local regional tumor control when

pancreaticoduodenectomy is combined with 5-FU-based chemoradiation as shown in table 1 (2-8). However, the morbidity and prolonged recovery associated with pancreaticoduodenectomy frequently prevents the timely delivery of postoperative chemoradiation (8,9). The risk of delaying postoperative adjuvant chemoradiation, combined with small published experiences of successful pancreatic resection following radiation therapy alone, prompted investigators at the MDACC to initiate studies in which chemoradiation was given before pancreaticoduodenectomy for patients with potentially resectable adenocarcinoma of the pancreas. The preoperative use of chemoradiation is supported by the following considerations: 1) The high frequency of positive-margin resections recently reported supports the concern that the retroperitoneal margin of excision, even when negative, may be only a few millimeters (10); surgery alone may therefore be an inadequate strategy for local tumor control. 2) Patients with disseminated disease evident on restaging studies after chemoradiation will not be subjected to laparotomy. 3) Because radiation therapy and chemotherapy will be given first, delayed postoperative recovery will have no effect on the delivery of multimodality therapy. 4) The preoperative delivery of chemoradiation does not increase perioperative morbidity or mortality in patients who undergo pancreaticoduodenectomy and in fact, recent data suggests that preoperative chemoradiation may decrease the incidence of pancreaticojejunal anastomotic fistula the most common complication following pancreaticoduodenectomy (11).

Critical to the accurate analysis of preoperative or postoperative adjuvant therapy is the incorporation of a standardized approach to patient selection (pretreatment staging), operative technique, and pathologic evaluation of surgical specimens. Standardization of these important variables is necessary to make accurate comparisons between treatment groups. Lack of precise definitions of patient groups has made much of the available data on the use of multimodality therapy for pancreatic cancer difficult

**Table 1.** Recent Chemoradiation Studies in Patients with Resectable Pancreatic Cancer

Reference	No. Patients*	EBRT Dose (Gy)	Chemotherapy Agent(s)	Median Survival (mo)
<u>Postoperative (adjuvant)</u> Kalser (1985) (5)	21	40	5-FU	20
Surgery alone	22	-	-	11
GITSG (1987) (3)	30	40	5-FU	18
Whittington (1991) (7)	28	45-63	5-FU, Mito-C	16
Foo (1993) (2)	29	35-60	5-FU	23
Yeo (1997) (8)	120	> 45	5-FU	20
Surgery alone	53	-	-	14
<u>Preoperative (neoadjuvant)</u>				
Hoffman (1998) (4)	24	50.4	5-FU, Mito-C	16
Staley (1996) (6)	39	30-50.4	5-FU	19

Abbreviations: EBRT, external-beam radiation therapy; 5-FU, 5-fluorouracil; Mito-C, mitomycin C.\*All patients underwent a pancreatectomy with curative intent.

to interpret. Therefore, we will briefly outline the radiographic staging, surgical technique, and pathologic evaluation of the resected specimen which are critical to the conduct of clinical trials examining the use of innovative multimodality therapies. This review will focus on current and future neoadjuvant chemoradiation strategies for patients with potentially resectable adenocarcinoma of the pancreas.

## 3. PRETREATMENT RADIOGRAPHIC STAGING

Stringent pretreatment staging to exclude patients with locally advanced (unresectable) or metastatic disease is critical to allow accurate interpretation of results from studies examining the value of multimodality therapy in patients with pancreatic cancer. In order to determine the extent of local-regional disease and screen for the presence of extrapancreatic metastases, patients should receive a careful physical exam, chest roentgenography, and abdominal computed tomography (CT) scan. High-quality contrast-enhanced CT is used to define the relationship of the tumor to the celiac axis and superior mesenteric vessels (12). At MDACC, we generally use helical CT in the evaluation of patients with presumed pancreatic neoplasms. The development of helical or spiral scanning has improved scan speed; the continuous rotation of the x-ray tube around the gantry allows the entire pancreas to be imaged during the bolus phase of contrast enhancement. In addition, scan data can be processed to display images in three-dimensional and multiplanar formats. Dilute Gastrografin or 2% barium sulfate is used to opacify the stomach and small bowel before scanning. Water can be used as an oral contrast agent when it is necessary to evaluate the gastric wall or duodenum. Precontrast CT of the liver and pancreas is performed at 10-mm slice thickness to localize the pancreas. Nonionic contrast material (300 mg/dl) is then delivered intravenously by an automatic injector at a rate of 2 to 3 ml/second for a total of 150 ml. Helical CT of the pancreas is performed 60 to 70 seconds after the start of the injection. A dynamic series of scans through the pancreas is completed at 3-mm slice thickness with a pitch factor of 1.5 to 2.0, depending on the anatomic extent of the tumor. The slice thickness can be increased to 5-mm in a large patient. The rest of the abdomen is then scanned at 7-mm slice thickness.

In the absence of extrapancreatic disease, the relationship of the low-density tumor mass to the superior mesenteric artery (SMA) and celiac axis is the main focus of

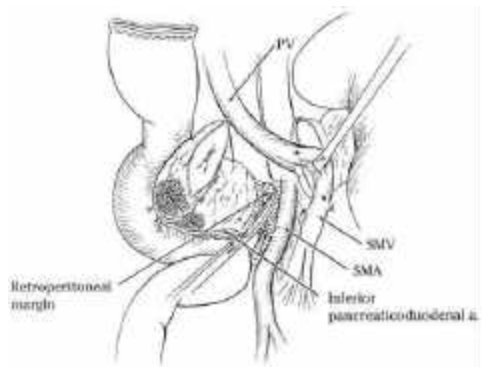
preoperative imaging studies. In assessing resectability, the goal is to accurately predict the likelihood of obtaining a negative retroperitoneal margin of resection. Anatomically, the retroperitoneal margin corresponds to the tissue along the proximal 3-4 cm of the SMA as shown in figure 1. The CT criteria used at MDACC to define potentially resectable disease includes: 1) the absence of extrapancreatic disease, 2) the absence of direct tumor extension to the SMA and celiac axis as defined by the presence of a fat plane between the low-density tumor and these arterial structures, and 3) a patent superior mesenteric-portal vein (SMPV) confluence (figure 2). The accuracy of this form of radiographic staging is demonstrated by a recent report by Spitz and colleagues from MDACC demonstrating a resectability rate of 80% (94/118) and a low rate of microscopic retroperitoneal margin positivity (17%) in patients with adenocarcinoma of the pancreatic head or uncinate process in patients who meet this radiographic criteria (9). The accuracy of CT in predicting unresectability and the inaccuracy of intraoperative assessment of resectability are both well established.

## 4. SURGICAL TECHNIQUE

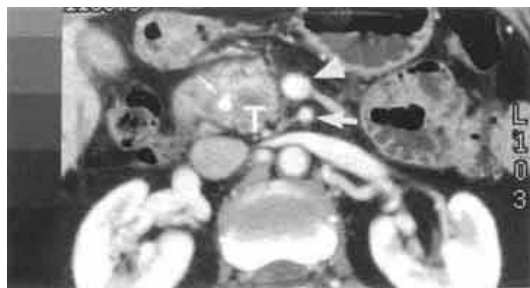
The surgical resection is divided into six clearly defined steps (figure 3)(13):

1. Identification of the infrapancreatic superior mesenteric vein (SMV): A Cattell-Braasch maneuver is performed by mobilizing the right colon and incising the visceral peritoneum to the ligament of Treitz (14). When complete, this maneuver allows cephalad retraction of the right colon and small bowel, exposes the third and fourth portions of the duodenum. Mobilization of the retroperitoneal attachments of the mesentery in order to facilitate exposure of the SMV is particularly important in patients who require venous resection. The lesser sac is entered by taking the greater omentum off of the transverse colon. The middle colic vein is identified, ligated, and divided prior to its junction with the SMV. Routine division of the middle colic vein allows greater exposure of the infrapancreatic SMV and prevents iatrogenic traction injury during exposure of the infrapancreatic SMV.

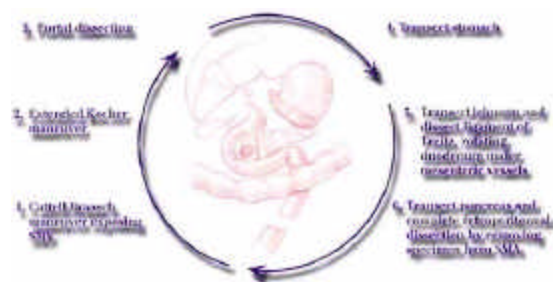2. Kocher maneuver: The Kocher maneuver is begun at the junction of the ureter and right gonadal vein. The right gonadal vein is ligated and divided, and all fibrofatty and lymphatic tissue overlying the medial aspect of the right kidney and inferior vena cava is elevated with the pancreatic head and duodenum to the left lateral edge of the aorta. Palpation of the relationship of the tumor to the



**Figure 1.** Illustration of the final step in resection of the specimen. Medial retraction of the superior mesenteric-portal vein confluence facilitates dissection of the soft tissue adjacent to the lateral wall of the proximal superior mesenteric artery (SMA). The retroperitoneal margin is defined as the soft tissue margin directly adjacent to the proximal 3-4 cm of the SMA. This margin is identified by the surgeon immediately upon specimen removal and evaluated by the surgeon and pathologist (in the adjoining pathology suite) by microscopic examination of a 2-3-mm full-face (en-face) section of the margin. The inferior pancreaticoduodenal artery is identified at its origin from the SMA, ligated, and divided. PV, portal vein; SMV, superior mesenteric vein.



**Figure 2.** Contrast-enhanced CT scan demonstrating a resectable adenocarcinoma of the pancreatic head (T). Note the normal fat plane between the tumor and both the superior mesenteric artery (large arrow) and the superior mesenteric vein (arrowhead). The intrapancreatic portion of the common bile duct contains a stent (small arrow), which was endoscopically placed for biliary drainage.



**Figure 3.** Six surgical steps used to perform the pancreaticoduodenectomy operation. The pancreatic head is removed en-bloc with the distal stomach, duodenum, proximal jejunum, bile duct and gallbladder.

SMA is not used to determine resectability(15). Instead, the relationship of the tumor to the SMA and celiac axis is objectively defined by preoperative contrast-enhanced CT; our preferred technique for assessment of these vital tumor-vessel relationships.

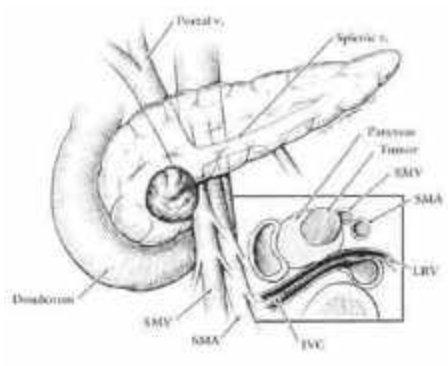
3. Portal dissection: The portal dissection is initiated by exposing the common hepatic artery proximal and distal to the gastroduodenal artery which is then ligated and divided. Encasement of a short segment of the hepatic artery is treated with segmental resection and either primary anastomosis or a reversed saphenous vein graft. The gallbladder is dissected out of the liver bed, and the common bile duct transected just cephalad to its junction with the cystic duct. Following division of the common bile duct and medial retraction of the common hepatic artery, the anterior wall of the portal vein is exposed. We do not make any attempt (at this stage in the operation) to develop a plane of dissection between the anterior surface of the SMPV confluence and the posterior surface of the neck of the pancreas. Invasion of the lateral or posterior wall of the SMPV confluence by tumors of the pancreatic head or uncinate process can be directly detected only after gastric and pancreatic transection.

4. Gastric transection: The stomach is transected at the level of the third or fourth transverse vein on the lesser curvature and at the confluence of the gastroepiploic veins on the greater curvature.

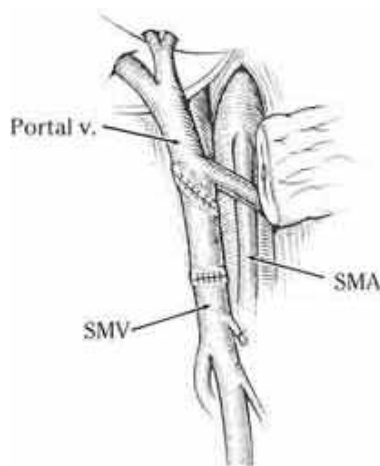
5. Mobilization of the duodenum and proximal ligament of Treitz: The jejunum is transected approximately 10 cm distal to the ligament of Treitz and its mesentery is sequentially ligated and divided. The duodenal mesentery is similarly divided to the level of the aorta, and the duodenum and proximal jejunum are reflected beneath the mesenteric vessels.

6. Pancreatic transection and retroperitoneal vascular dissection: After traction sutures are placed on the superior and inferior borders of the pancreas, the pancreas is transected with an electrocautery at the level of the portal vein. If there is evidence of tumor adherence to the portal vein or SMV, the pancreas can be divided at a more distal location in preparation for segmental venous resection. The specimen is separated from the SMV by ligating and dividing the small venous tributaries to the uncinate process and pancreatic head. Complete removal of the uncinate process combined with medial retraction of the SMPV confluence facilitates exposure of the SMA, which is then dissected to its origin at the aorta.

The retroperitoneal dissection along the SMPV confluence and SMA represents the most important oncologic aspect of pancreaticoduodenectomy. This is due to the tendency of pancreatic adenocarcinoma to extend into the extrapancreatic retroperitoneal soft tissues and nerve sheaths adjacent to the right side of the SMA. Two specific issues regarding the dissection along the SMA warrant comment. First, this dissection should occur in the immediate periadventitial plane along the SMA. The SMA is readily identifiable within a 3- to 4-mm dense sheath of neural tissue located deep and medial to the SMV. The periadventitial plane is identified and dissection proceeds cephalad along the right anterolateral surface of the SMA, separating the perivascular soft tissues from the artery. This ensures the maximal retroperitoneal margin and also minimizes the risk of iatrogenic vascular injury. This latter point is particularly important because iatrogenic injury to the SMA or major bleeding from the friable superior and



**Figure 4.** Illustration of the three-dimensional relationship between a pancreatic head tumor and the superior mesenteric vein (SMV) and artery (SMA). The intimate relationship between the pancreatic head and the lateral and posterior walls of the SMV can result in venous invasion by a pancreatic head carcinoma in the absence of tumor involvement of the SMA (insert). IVC, inferior vena cava; LRV, left renal vein.



**Figure 5.** Illustration of our preferred method of reconstruction of the superior mesenteric vein (SMV) using an internal jugular vein interposition graft. The splenic vein - portal vein junction is usually easily preserved by tangential excision of the SMV to include a longer segment of the lateral wall of the portal vein. SMA = superior mesenteric artery.

inferior pancreaticoduodenal branches can occur if dissection occurs through an imprecise plane in the lateral soft tissues to the right of the SMA. Second, the SMA may be injured once the specimen is completely freed from the SMV/portal vein and lateral traction is applied to the specimen; at this point in the dissection, the SMA is often pulled or "bowed" out to the right where it is vulnerable to injury unless dissection proceeds under direct vision of the artery.

Tumor involvement of the SMV and SMPV confluence is considered by most surgeons to be a contraindication to pancreaticoduodenectomy. However, reports of venous resection at the time of pancreaticoduodenectomy often involve patients with

arterial involvement suggesting retroperitoneal tumor extension that could not be completely resected (16). In contrast, isolated involvement of the SMPV confluence without radiographically evident involvement of the SMA (figure 4) can be managed intraoperatively with resection of the involved segment of vein and vascular reconstruction (figure 5). Detailed evaluation of patients requiring venous resection and reconstruction reveals a long-term outcome that is comparable to that of similarly staged patients not requiring vascular resection (16, 17). Thus, isolated involvement of the SMPV confluence is an anatomic issue that requires a technical strategy but does not in and of itself represent an adverse prognostic factor precluding potentially curative resection.

## 5. PATHOLOGIC ASSESSMENT OF SURGICAL SPECIMENS

Accurate pathologic assessment of surgical specimens is critical for both the evaluation of innovative preoperative treatment strategies and the development of reproducible prognostic predictors of patient survival and treatment failure. Retrospective pathologic analysis of archival material does not allow accurate assessment of margins of resection or number of lymph nodes retrieved. The standard pathologic evaluation of the pancreaticoduodenectomy specimen developed at MDACC<sup>18</sup> begins by first performing frozen-section evaluations of the common bile duct transection margin and the pancreatic transection margin. A positive bile duct or pancreatic transection margin is treated with re-resection. The retroperitoneal transection margin is defined as the soft-tissue margin directly adjacent to the proximal 3- to 4-cm of the SMA. This margin is evaluated by permanent-section microscopic examination of a 2- to 3-mm full-face (en-face) section of the margin. Re-resection (for a microscopically positive margin) is not possible in the retroperitoneum where the aorta and SMA origin limit the extent of surgical resection. Samples of multiple areas of each tumor, including the interface between tumor and adjacent uninvolved tissue, are submitted for paraffin-embedded histologic examination (5 to 10 blocks). Four-microns-thick sections are cut and stained with hematoxylin and eosin. Final pathologic evaluation of permanent sections include a description of tumor histology and differentiation, gross and microscopic evaluation of the tissue of origin (pancreas, bile duct, ampulla of Vater, or duodenum), and assessments of maximal transverse tumor diameter, the presence or absence of perineural, lymphatic, and vascular invasion, and lymph node status and location (as outlined on the anatomical pathology dissection board). When segmental resection of the superior mesenteric vein is required, the area of presumed tumor invasion of the vein wall is serially sectioned and examined in an attempt to discriminate benign fibrous attachment from direct tumor invasion. In patients who receive preoperative chemoradiation, the grade of treatment effect is assessed on permanent sections (table 2)(19).

The high incidence of local recurrence following pancreaticoduodenectomy mandates that greater attention be paid to the retroperitoneal margin. This margin can be studied accurately only at the time of specimen removal, and attempts at retrospective analysis of this important excision margin are prone to inaccuracy. Recent reports of patients who underwent pancreaticoduodenectomy and

## Neoadjuvant Chemoradiation

**Table 2.** Grading System for Chemoradiation Treatment Effect (44)

Grade	Histologic Appearance
I	Characteristic cytologic changes of malignancy are present, but little (<10%) or no tumor cell destruction is evident
II	In addition to characteristic cytologic changes of malignancy, 10-90% of tumor cells are destroyed
IIA	Destruction of 10-50% of tumor cells
IIB	Destruction of 51-90% of tumor cells
III	Few (<10%) viable-appearing tumor cells are present
IIIM	Sizable pools of mucin are present
IV	No viable tumor cells are present
IVM	Acellular pools of mucin are present

**Table 3.** Median Survival for Patients Who Underwent Surgical Resection for Adenocarcinoma of the Pancreas and Were Found to Have a Positive Margin of Resection

Reference (Year)	N	Margin	Median Survival (mo)
Tepper (1976) (20)	17*	G/M	8
Trede (1990) (21)	54	G/M	10
Whittington (1991) (7)	19	G	†
Willet (1993) (10)	37	G/M	11
Nitecki (1995) (22)	28	G	9
Yeo (1995) (23)	58	G/M	10
Lillemoe (1996) (24)	64	G/M	12

Abbreviations: G, grossly positive margin; M, microscopically positive margin. \*All patients also had positive regional lymph nodes. †Two patients alive at 18 months of follow-up.

were found to have a positive margin of resection demonstrate the impact of margin positivity on survival duration. The survival duration of 8 to 12 months in margin-positive patients was no different than the median survival reported for patients with locally advanced disease treated with palliative chemoradiation without surgical resection of the pancreas (table 3)(7, 10, 20-24). These studies did not precisely define the retroperitoneal margin, however, it is reasonable to assume that the margin most frequently reported as positive in patients who undergo pancreaticoduodenectomy is along the superior mesenteric vein or proximal SMA (24).

Several other tumor characteristics have been evaluated as potential prognostic indicators. In a recent study by Allison and colleagues, aneuploid DNA content (and the % of S-phase cells), tumor size (> 2.5 cm), and the percentage of tumor-positive lymph nodes were the tumor characteristics predictive of decreased survival duration by multivariate analysis (25). The presence of mutant K-ras DNA (85% of specimens) and positive surgical resection margins were not prognostic indicators for patient survival. However, median survival for the 96 patients included in this analysis was only 10 months. In contrast, recent data from MDACC reported by Bold and colleagues demonstrated that the presence of mutant K-ras DNA was the most powerful predictor of tumor recurrence (26). In agreement with the study by Allison, poorly differentiated histology and lymph node metastases predicted tumor recurrence and decreased survival. The median survival for the 104 patients reported by Bold was 23 months.

To determine which patient subsets may benefit from the most aggressive treatment strategies, accurate pathologic staging and histologic assessment of response to preoperative therapy are mandatory.

## 6. MULTIMODALITY TREATMENT STRATEGIES

External-beam radiation therapy (EBRT) and concomitant 5-fluorouracil (5-FU) chemotherapy (chemoradiation) have been shown to prolong survival in patients with locally advanced adenocarcinoma of the pancreas (27). Those data were the foundation for a prospective, randomized study of adjuvant chemoradiation (500 mg/m<sup>2</sup>/day of 5-FU for 6 days and 40 Gy of radiation) following pancreaticoduodenectomy conducted by the Gastrointestinal Tumor Study Group (GITSG); that trial also demonstrated a survival advantage from multimodality therapy compared with resection alone(3, 5). However, because of a prolonged recovery, 5 (24%) of the 21 patients in the adjuvant chemoradiation arm could not begin chemoradiation until more than 10 weeks after pancreaticoduodenectomy. This, despite the obvious selection bias in patient accrual; the patients likely to be considered for protocol entry were those who recovered rapidly from surgery and had a good performance status. Similar findings have recently been reported from the European Organization for Research and Treatment of Cancer (EORTC). The EORTC initiated a study in 1987 comparing adjuvant 5-FU-based chemoradiation following pancreatectomy with surgery alone ( 28). Between 1987 and 1995, 218 patients were randomized to receive either chemoradiation or no further treatment following pancreaticoduodenectomy for adenocarcinoma of the pancreas (55%) or periampullary region (45%). Median survival duration, reported in abstract form, was 23.5 months for those who received adjuvant therapy and 19.1 months for those who received surgery alone; subset analysis for patients with adenocarcinoma of pancreatic origin has not been reported. Importantly, 22% of those randomized to receive chemoradiation did not receive intended therapy due to postoperative complications or

## Neoadjuvant Chemoradiation

patient refusal. A similar selection bias is likely in effect when attempts are made to retrospectively compare patients who received postoperative adjuvant chemoradiation with patients who were treated only with pancreaticoduodenectomy.

Recently reported data from Yeo and colleagues at Johns Hopkins University add further support to the use of multimodality therapy (8). Those investigators reviewed all patients who underwent pancreaticoduodenectomy for adenocarcinoma of the pancreatic head during a 4-year period. One-hundred and twenty patients received adjuvant chemoradiation, and 53 underwent pancreaticoduodenectomy alone. Median survival for those receiving adjuvant therapy was 19.5 months compared with 13.5 months for the group who received surgery alone.

The primary disadvantage of postoperative chemoradiation is the inability to deliver postoperative therapy to all patients in a timely manner because of perioperative complications or delayed recovery following pancreaticoduodenectomy. In contrast, if radiation therapy and chemotherapy are given first, delayed postoperative recovery will have no effect on the delivery of multimodality therapy. The first report of preoperative chemoradiation and pancreaticoduodenectomy from MDACC used a standard-fractionation treatment schema (19). Radiation therapy was delivered over 5.5 weeks with 18-MeV photons using a four-field technique to a total dose of 50.4 Gy, prescribed to the 95% isodose, at 1.8 Gy/fraction (28 fractions), 5 days/week. 5-fluorouracil (5-FU) was given concurrently by continuous infusion at a dosage of 300 mg/m<sup>2</sup>/day, 5 days/week, through a central venous catheter. The recently reported multicenter Eastern Cooperative Oncology Group (ECOG) trial documented the need for hospital admission in 51% of patients during or within four weeks of completing chemoradiation (4). This finding caused us to change the delivery of radiation therapy and 5-FU to a rapid-fractionation program of chemoradiation designed to avoid the gastrointestinal toxicity seen with our standard 5.5 week program while attempting to maintain the excellent local tumor control achieved with multimodality therapy (29). Rapid-fractionation chemoradiation was delivered over 2 weeks with 18-MeV photons using a four-field technique to a total dose of 30 Gy, prescribed to the 95% isodose, at 3 Gy/fraction (10 fractions), 5 days/week. 5-FU was given concurrently by continuous infusion at a dosage of 300 mg/m<sup>2</sup>/day, 5 days/week. This program was based on the principle that the total radiation dose required to obtain a given biological effect decreases as the dose per fraction increases. Restaging with chest roentgenography and abdominal CT was performed 4 weeks following completion of chemoradiation in preparation for pancreaticoduodenectomy. Thirty-five patients received this treatment, 27 were taken to surgery and 20 (74%) underwent successful pancreaticoduodenectomy. Local tumor control and patient survival were equal to our results with standard-fractionation (5.5 wks) chemoradiation (30).

In patients who receive chemoradiation prior to planned pancreaticoduodenectomy, a repeat staging CT scan after chemoradiation reveals liver metastases in approximately 25% (9). If these patients had undergone pancreaticoduodenectomy at the time of diagnosis, it is probable that the liver metastases would have been

subclinical; these patients would therefore have undergone a major surgical procedure only to have liver metastases discovered soon after surgery. In the MDACC trials, patients who were found to have disease progression at the time of restaging had a median survival of only 7 months (9). The avoidance of a lengthy recovery period and the potential morbidity of pancreaticoduodenectomy in patients with such a short expected survival duration represents a distinct advantage of preoperative over postoperative chemoradiation. When delivering multimodality therapy for any disease, it is beneficial, when possible, to deliver the most toxic therapy last, thereby avoiding morbidity in patients who experience rapid disease progression not amenable to currently available therapies.

The survival advantage for the combination of chemoradiation and surgery compared with surgery alone (table 1) likely results from improved local-regional tumor control. Because of the poor rates of response to 5-FU-based systemic therapy in patients with measurable metastatic disease, it is unlikely that current chemoradiation regimens significantly impact the development of distant metastatic disease. Recent data from MDACC support this belief (6). Thirty-nine patients with biopsy-proven adenocarcinoma of the pancreatic head received preoperative infusional 5-FU (300 mg/m<sup>2</sup>/day, M-F) and external-beam irradiation (50.4 Gy) followed by pancreaticoduodenectomy and electron-beam intraoperative radiation therapy (10 Gy). Thirty-eight patients were evaluable for analysis of patterns of treatment failure; there was one perioperative death. Overall, there were 38 recurrences in 29 patients: 8 (21%) recurrences were local-regional (pancreatic bed and/or peritoneal cavity), and 30 (79%) were distant (lung, liver, and/or bone). The liver was the most frequent site of tumor recurrence, and liver metastases were a component of treatment failure in 53% of patients (69% of all patients who had recurrences). Fourteen patients (37% of all patients; 48% of patients who had recurrences) had liver metastases as their only site of recurrence. Isolated local or peritoneal recurrences were documented in only four patients (11%). In contrast, previous reports of pancreaticoduodenectomy for adenocarcinoma of the pancreas have documented local recurrence in 50% to 80% of patients (1). This improvement in local-regional control was seen despite the fact that 14 of 38 evaluable patients had undergone laparotomy with tumor manipulation and biopsy prior to referral for chemoradiation and reoperation. If these 14 patients were excluded, only two patients (8%) would have experienced local or peritoneal recurrence as any component of treatment failure. However, because of the large percentage of patients who developed distant metastatic disease, predominantly in the liver, improved local-regional tumor control translated into only a small improvement in median survival compared with that in other recently published studies. Therefore, in the absence of more effective systemic therapy, the goal of chemoradiation (preoperative or postoperative) and pancreatotomy should be to maximize local-regional tumor control while minimizing treatment time, treatment-related toxicity, and cost.

In an effort to compare preoperative and postoperative chemoradiation strategies we recently reported on the multimodality treatment of 142 consecutive patients with localized adenocarcinoma of the pancreatic

## Neoadjuvant Chemoradiation

head deemed resectable on the basis of pretreatment radiographic images (9). The subset of 41 patients who completed protocol-based preoperative chemoradiation and pancreaticoduodenectomy (27 patients received standard-fractionation chemoradiation (50.4 Gy) and 14 patients received rapid-fractionation chemoradiation (30 Gy) were compared to 19 patients who received pancreaticoduodenectomy and postoperative adjuvant chemoradiation. Overall median follow-up for these 60 patients was 19 months. No patient who received preoperative chemoradiation experienced a delay in surgery because of chemoradiation toxicity, but 6 (24%) of 25 eligible patients did not receive intended postoperative chemoradiation because of delayed recovery following pancreaticoduodenectomy. Patients treated with rapid-fractionation preoperative chemoradiation had a significantly ( $P < .01$ ) shorter duration of treatment (median, 62.5 days) compared with patients who received postoperative chemoradiation (median, 98.5 days) or standard-fractionation preoperative chemoradiation (median, 91.0 days) (figure 1). No patient who received preoperative chemoradiation and pancreaticoduodenectomy experienced a local recurrence; peritoneal (regional) recurrence occurred in 10% of these patients. Local or regional recurrence occurred in 21% of patients who received pancreaticoduodenectomy and postoperative chemoradiation.

Despite the ability of surgeons to perform pancreaticoduodenectomy safely, it remains too extensive and complex a procedure to enable the consistent postoperative delivery of standard-fractionation adjuvant chemoradiation. In the absence of compelling data demonstrating superior survival results with either a preoperative or postoperative treatment approach, all available data suggests that a greater proportion of patients receive potentially beneficial adjuvant therapy when chemoradiation is administered in a neoadjuvant setting. Further, preoperative chemoradiation treatment strategies will spare a significant number of patients the morbidity and mortality associated with laparotomy, as up to one-fourth of patients will evidence metastatic disease at the time of preoperative restaging following chemoradiation.

## 7. NEWER RADIATION SENSITIZING AGENTS

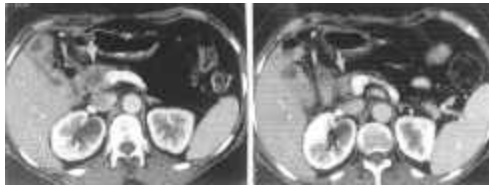
Paclitaxel is a plant product isolated from the stem bark of *Taxus brevifolia*, the western yew, a small evergreen indigenous to the Pacific Northwest (31). Paclitaxel enhances the polymerization of tubulin to stable microtubules, inhibiting spindle cell function during mitosis, thereby preventing normal cell replication. Cells exposed to paclitaxel experience growth arrest in the G2/M phase of the cell cycle – a state during which they are especially sensitive to irradiation. In clinical trials, patients with a variety of solid tumors including ovary, breast, and metastatic pancreatic adenocarcinoma have demonstrated objective responses to taxanes (paclitaxel and docetaxel) despite significant tumor burdens which failed to respond to conventional therapy (31, 32). Recently, Safran and colleagues from the Brown University Oncology Group performed a phase I study using paclitaxel and concurrent EBRT in patients with locally advanced pancreatic and gastric adenocarcinoma (33). Dose limiting toxicity was due to abdominal pain, nausea, and anorexia and occurred at 60 mg/m<sup>2</sup>/week. Four objective (radiographic) partial

responses were observed in 13 patients with pancreatic cancer.

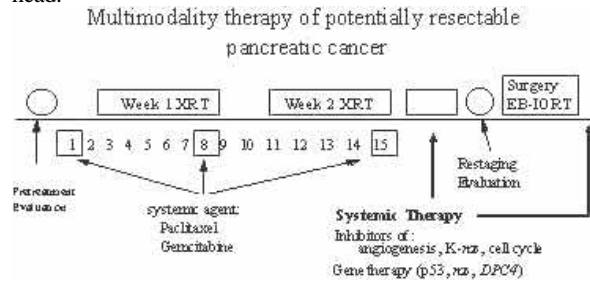
The above data provide the rationale for the recently reported study from Vanderbilt of preoperative paclitaxel (30 to 75 mg/m<sup>2</sup>/wk.) and concurrent standard-fractionation EBRT (45 Gy; 1.8 Gy/fraction) for patients with potentially resectable adenocarcinoma of the pancreatic head (34). Five patients have been entered and four have undergone successful pancreaticoduodenectomy and are alive with a minimum follow-up of 15 months. At MDACC, paclitaxel (60 mg/m<sup>2</sup>/wk for 3 wks) has been combined with rapid-fractionation chemoradiation (30Gy/2 wks; 3 Gy/fraction). Preliminary experience with this regimen has demonstrated minimal toxicity and improved histologic response in the resected pancreatic tumor compared to previous studies with 5-FU-based preoperative chemoradiation (Evans, unpublished data).

Gemcitabine (2',2'-difluorodeoxycytidine, Gemzar) is a deoxycytidine analogue capable of inhibiting DNA replication and repair. Following a phase I study (35), gemcitabine was evaluated in a multicenter trial of 44 patients with advanced pancreatic cancer (36). While only five objective responses were documented, the investigators noted frequent subjective symptomatic benefit, often in the absence of an objective tumor response. Toxicity appeared minor and included myelosuppression, particularly thrombocytopenia, as well as a flu-like syndrome and mild hemolytic-uremic syndrome. Based on these observations, two subsequent trials of gemcitabine in patients with advanced pancreatic cancer have been completed. In one randomized trial, gemcitabine was compared to 5-FU in previously untreated patients (37). Patients treated with gemcitabine had a median survival of 5.65 months compared to 4.41 months ( $p=0.0025$ ) in those treated with 5-FU. Twenty-four percent of patients treated with gemcitabine were alive at 9 months compared to 6% of patients treated with 5-FU. In addition, more clinically meaningful effects on disease-related symptoms (pain control, performance status, weight gain) were seen with gemcitabine (23.8% of patients) than with 5-FU (4.8% of patients). Similar systemic effects and demonstrable disease responses were documented in patients who were treated with gemcitabine after experiencing disease progression while receiving 5-FU (38).

Gemcitabine is also a potent radiation sensitizer of human pancreatic cancer cells in vitro, supporting studies examining its use in vivo. Laboratory studies suggest that the inhibitory effect of gemcitabine on DNA synthesis (when combined with irradiation) is prolonged in tumor compared to normal tissues (39). This may provide a window of opportunity for the combination of gemcitabine and EBRT when delivered in a fractionated schedule. Such data provide the basis for the recently reported phase I studies of this drug-radiation combination. Blackstock and colleagues treated 8 patients with combined standard-fractionation EBRT (50.4 Gy/5.5 wks; 1.8 Gy/fraction) and twice weekly, escalating doses of gemcitabine (20 mg/m<sup>2</sup>, 40 mg/m<sup>2</sup>, 60 mg/m<sup>2</sup>); no grade IV toxicities were observed, the MTD has not been reached (40). McGinn and colleagues reported the treatment of 13 patients in a multi-institutional setting with standard-fractionation EBRT (50.4 Gy) and an escalating weekly dose of gemcitabine (200 mg/m<sup>2</sup>, 300 mg/m<sup>2</sup>, 400 mg/m<sup>2</sup>) (41). Three patients



**Figure 6.** Computed tomography scans before (left) and after (right) treatment with concurrent gemcitabine and external-beam radiation therapy. The arrow identifies the site of the primary adenocarcinoma within the pancreatic head.



**Figure 7.** The future of multimodality therapy for patients with potentially resectable adenocarcinoma of the pancreatic head. Treatment schemas emphasize the importance of minimizing toxicity, and treatment duration, while attempting to improve therapeutic efficacy. Cytotoxicity is enhanced by combining radiation therapy with more potent radiation-sensitizing agents. Systemic therapy is continued after both chemoradiation and surgery with systemic agents of low toxicity directed at specific molecular events involved in pancreatic tumorigenesis (i.e., inhibition of angiogenesis, the use of protease inhibitors [matrix metalloproteinase inhibitors], inhibition of *ras*-dependent signal transduction, or strategies for the use of gene therapy). Abbreviations: EB-IORT, electron-beam intraoperative radiation therapy.

required hospital admission for nausea and vomiting. Enrollment continues at a gemcitabine dose of 500 mg/m<sup>2</sup>/wk, and the MTD has not yet been reached. Wolff and colleagues from MDACC have reported a phase I study of rapid-fractionation EBRT (30 Gy/2 wks; 3 Gy/fraction) and concomitant weekly gemcitabine in patients with locally advanced adenocarcinoma of the pancreatic head (42). Gemcitabine was given during the first two weeks of irradiation and continued weekly to complete a 7-week course of systemic therapy. At this schedule of administration, 500 mg/m<sup>2</sup>/wk was judged to be above the MTD for this drug-radiation combination. Five of 10 evaluable patients demonstrated response to treatment with an occasional impressive radiographic response (figure 6).

Hoffman and colleagues have reported a phase I study of preoperative standard-fractionation EBRT (50.4 Gy) and escalating weekly doses of gemcitabine (300 mg/m<sup>2</sup>, 400 mg/m<sup>2</sup>, 500 mg/m<sup>2</sup>) (43). Eight of 15 patients were hospitalized after chemoradiation. Pancreaticoduodenectomy was completed in 8 patients, yet 6 of these 8 patients were found to have positive resection margins following pathologic analysis of the resected specimen.

## 8. PERSPECTIVE

The future of multimodality therapy for patients with potentially resectable adenocarcinoma of the pancreas depends on the development of treatment schemas which emphasize minimizing toxicity, and treatment duration, while attempting to improve therapeutic efficacy. New, more potent radiation-sensitizing agents enhance cytotoxicity and maximize local control. Systemic therapies will be directed at specific molecular events involved in pancreatic tumorigenesis (i.e., inhibition of angiogenesis, the use of protease inhibitors [matrix metalloproteinase inhibitors], or inhibition of *ras*-dependent signal transduction (figure 7). These agents should be of low toxicity to permit administration during the preoperative period as well as prolonged postoperative administration.

## 8. ACKNOWLEDGEMENT

This work was supported by grants from the University Cancer Foundation, and the Various Donors Fund for Pancreatic Cancer Research at M. D. Anderson Cancer Center.

## 9. REFERENCES

1. D.B. Evans, J.L. Abbruzzese, & T.A. Rich: Cancer of the pancreas. In: *Cancer: Principles and Practice of Oncology*. Eds: DeVita VT Jr, Hellman S, Rosenberg SA, Lippincott, Philadelphia, (1997)
2. Foo M, Gunderson L, Nagorney D, McLlath D, Van Heerden J, Robinow J, Kvols, L, Garton, G, Martenson, J, & Cha, S: Patterns of failure in grossly resected pancreatic ductal adenocarcinoma treated with adjuvant irradiation +/- 5 fluorouracil. *Int J Radiat Oncol Biol Phys* 26, 483-489 (1993)
3. Gastrointestinal Tumor Study Group: Further evidence of effective adjuvant combined radiation and chemotherapy following curative resection of pancreatic cancer. *Cancer* 59, 2006-10 (1987)
4. Hoffman J, Lipsitz S, Pisansky T, Weese J, Solin L, & Benson AB. Phase II trial of preoperative radiation therapy and chemotherapy for patients with localized, resectable adenocarcinoma of the pancreas: An Eastern Cooperative Oncology Group study. *J Clin Oncol* 16: 317-23 (1987)
5. Kalser M, & Ellenberg S: Pancreatic cancer. adjuvant combined radiation and chemotherapy following curative resection. *Arch Surg* 120, 899-903 (1985)
6. Staley C, Lee J, Cleary K, Abbruzzese J, Fenoglio C, Rich T, & Evans, D. Preoperative chemoradiation, pancreaticoduodenectomy, and intraoperative radiation



## Neoadjuvant Chemoradiation

therapy for adenocarcinoma of the pancreatic head. *Am J Surg* 171, 118-25 (1996)

7. Whittington R, Bryer M, Haller D, Solin L, & Rosato E: Adjuvant therapy of resected adenocarcinoma of the pancreas. *Int J Radiat Oncol Biol Phys* 21, 1137-43 (1991)

8. Yeo C, Abrams R, Grochow L, Sohn T, Ord S, Hruban R, Zahurak M, Dooley W, Coleman J, Sauter P, Pitt H, Lillemoe K, & Cameron J. Pancreaticoduodenectomy for pancreatic adenocarcinoma: postoperative adjuvant chemoradiation improves survival. *Ann Surg* 225: 621-33 (1997)

9. Spitz F, Abbruzzese J, Lee J, Pisters P, Lowy A, & Fenoglio C: Preoperative and postoperative chemoradiation strategies in patients treated with pancreaticoduodenectomy for adenocarcinoma of the pancreas. *J Clin Oncol* 15, 928-37, (1997)

10. Willett C, Lewandrowski K, Warshaw A, Efird J, & Compton C: Resection margins in carcinoma of the head of the pancreas. Implications for radiation therapy. *Ann Surg* 217, 144-48, (1993)

11. Lowy AM, Lee JE, Pisters PWT, Davidson BS, Fenoglio CJ, Stanford P, Jinnah R, & Evans DB. Prospective, randomized trial of octreotide to prevent pancreatic fistula following pancreaticoduodenectomy for malignant disease. *Ann Surg* 226, 632-41 (1997)

12. Fuhrman G, Charnsangavej C, Abbruzzese J, Cleary K, Martin R, Fenoglio C, & Evans DB: Thin-section contrast-enhanced computed tomography accurately predicts the resectability of malignant pancreatic neoplasms. *Am J Surg* 167, 104-11 (1994)

13. DB Evans, JE Lee, & PWT Pisters: Pancreaticoduodenectomy (Whipple operation) and total pancreatectomy for cancer. In: *Mastery of Surgery*. Eds: Nyhus LM, Baker RJ, Fishcer JF: Little, Brown and Co Boston (1996)

14. Cattell RB, & Braasch JW. A technique for the exposure of the third and fourth portions of the duodenum. *Surg Gynecol Obstet* 11, 379-80 (1960)

15. Robinson E, Lee J, Lowy A, Fenoglio C, Pisters P, & Evans D: Reoperative pancreaticoduodenectomy for periampullary carcinoma. *Am J Surg* 172, 437-38 (1996)

16. Leach SD, Lowy AM, Fuhrman GM, Lee JE, Curley SA, & Evans DB. Pancreatic malignancy involving the superior mesenteric-portal vein confluence is not a contraindication to pancreaticoduodenectomy. *Br J Surg* 85, 611-17 (1998)

17. Fuhrman G, Leach S, Staley C, Cusack J, Charnsangavej C, Cleary K, El Naggar A, Fenoglio C, Lee J, & Evans D: Rationale for en bloc vein resection in the treatment of pancreatic adenocarcinoma adherent to the superior mesenteric-portal vein confluence. *Ann Surg* 223, 154-62 (1996)

18. Staley C, Cleary K, & Abbruzzese J: Need for standardized pathologic staging of pancreaticoduodenectomy specimens: *Pancreas* 12, 373-80 (1996)

19. Evans DB, Rich T, & Byrd D: Preoperative chemoradiation and pancreaticoduodenectomy for adenocarcinoma of the pancreas. *Arch Surg* 127, 1335-1339 (1992)

20. Tepper J, Nardi G, & Sutt H: Carcinoma of the pancreas: review of MGH experience from 1963 to 1973. Analysis of surgical failure and implications for radiation therapy. *Cancer* 37, 1519-24 (1976)

21. Trede M, Schwall G, & Saeger H: Survival after pancreatoduodenectomy. 118 consecutive resections without an operative mortality. *Ann Surg* 211, 447-58 (1990)

22. Nitecki S, Sarr M, Colby T, & Van Heerden J: Long-term survival after resection for ductal adenocarcinoma of the pancreas. Is it really improving? *Ann Surg* 221, 59-66 (1995)

23. Yeo C, Cameron J, Lillemoe K, Sitzmann J, Hruban R, Goodman S, Dooley W, Coleman J, & Pitt H: Pancreaticoduodenectomy for cancer of the head of the pancreas. 201 patients. *Ann Surg* 221, 721-33 (1995)

24. Lillemoe K, Cameron J, & Yeo C, et al: Pancreaticoduodenectomy: Does it have a role in the palliation of pancreatic cancer? *Ann Surg* 223, 718-28 (1996)

25. Allison DC, Piantadosi S, Hruban RH, Dooley WC, Fishman EK, Yeo CJ, Lillemoe KD, Pitt HA, Lin P, &

## Neoadjuvant Chemoradiation

Cameron JL. DNA content and other factors associated with ten-year survival after resection of pancreatic carcinoma. *J Surg Onc* 67, 151-59 (1998)

26. Bold R, Evans DB, Hess KR, Grau AM, Sinicrope F, Cleary KR, Chiao PJ, & Abbruzzese JL. Molecular genetics of pancreatic cancer. *Gastroenterology* 114,S0029 (1998)

27. Gastrointestinal Tumor Study Group: A multi-institutional comparative trial of radiation therapy alone and in combination with 5-fluorouracil for locally unresectable pancreatic carcinoma. *Ann Surg* 189, 205-8 (1979)

28. Klinkenbijl J, Sahmoud T, Pel van R, Couvreur M, Veenhof C, Arnaud J, Hennipman A, Wils J, & Jeekel J. Radiotherapy and 5-FU after curative resection for cancer of the pancreas and peri-ampullary region: A phase III trial of the EORTC GITCCG. *Eur J Cancer* 33 (S8), 1239 (1997)

29. Evans DB, Abbruzzese J, Cleary K, Buchholz D, & Rich T: Rapid-fractionation preoperative chemoradiation for malignant periampullary neoplasms. *J R Coll Surg Edinb* 40, 319-23 (1995)

30. Pisters PWT, Abbruzzese JL, Cleary KR, Janjan N, Goswitz M, Rich T, Fenoglio C, Lee J, & Evans D: Pilot study of rapid-fractionation preoperative chemoradiation pancreaticoduodenectomy (PD) and intraoperative radiation therapy (IORT) for resectable pancreatic adenocarcinoma (Abstract). *Proc Am Soc Clin Oncol* 16, 1076 (1997)

31. Rowinsky E, & Donehower R: Paclitaxel. *N Eng J Med* 332, 1004-14 (1995)

32. Cortes J, & Pazdur R: Docetaxel. *J Clin Oncol* 13, 2643-55 (1995)

33. Safran H, King TP, Choy H, Hesketh PJ, Wolf B, Altenhein E, Sikov W, Rosmarin A, Akerley W, Radie-Keane K, Cicchetti G, Lopez F, Bland K, & Wanebo HJ: Paclitaxel and concurrent radiation for locally advanced pancreatic and gastric cancer: A phase I study. *J Clin Oncol* 15, 901-07 (1997)

34. Blanke CD, Choy H, Beauchamp D, Delbeke D, Shyr Y, Mertz H, Washington M, Johnson DH, & Leach SD: Phase I/II study of paclitaxel-based neoadjuvant chemoradiation for patients with potentially resectable

adenocarcinoma of the pancreatic head (Abstract). *Proc Am Soc Clin Oncol* 17, 1103 (1998)

35. Abbruzzese JL, Grunewald R, Weeks EA, Gravel D, Adams T, Nowak B, Mineishi S, Tarassoff P, Satterlee W, Raber MN, & Plunkett, W: A phase I clinical, plasma and cellular pharmacology study of gemcitabine. *J Clin Oncol* 9, 491-98 (1991)

36. Casper ES, Green MR, Kelsen DP, Heelan RT, Brown TD, Flombaum CD, Trochanowski B, & Tarassoff PG: Phase II trial of gemcitabine (2',2'-difluorodeoxycytidine) in patients with adenocarcinoma of the pancreas. *Invest New Drugs* 12, 29-34 (1994)

37. Burris HA 3rd, Moore MJ, Andersen J, Green MR, Rothenberg ML, Modiano MR, Cripps MC, Portenoy RK, Storniolo AM, Tarassoff P, Nelson R, Dorr FA, Stephens CD, & Von Hoff DD: Improvements in survival and clinical benefit with gemcitabine as first-line therapy for patients with advanced pancreas cancer: a randomized trial. *J Clin Oncol* 15, 2403-13 (1997)

38. Rothenberg ML, Burris HA III, Andersen JS, Moore M, Green MR, Portenoy RK, Casper ES, Tarassoff PG, Storniolo AM, & Von Hoff DD: Gemcitabine: effective palliative therapy for pancreas cancer patients failing 5-FU (Abstract). 14, 198 (1995)

39. Lawrence TS, Chang EY, Hahn TM, Hertel LW, & Shewach DS: Radiosensitization of pancreatic cancer cells by 2', 2'-difluoro-2'-deoxycytidine. *Intl J Rad Onc. Biol Physics* 34, 867-72 (1996)

40. Blackstock AW, Bernard SA, Richards F, Savage P, & Tepper JE: Phase I study of concurrent radiation and twice-weekly gemcitabine in advanced/metastatic pancreatic cancer. *Proc Am Soc Clin Oncol* 17, 1015 (1998)

41. McGinn CJ, Smith DC, Szarka CE, Pinover WH, Loehrer PJ, Morphis JG, Nicol S, Shewach DS, Lawrence TS, & O'Dwyer PJ: A phase I study of gemcitabine in combination with radiation therapy in patients with localized, unresectable pancreatic cancer. 17, 1014 (1998)

42. Wolff RA, Evans DB, Gravel DM, Lenzi R, Pisters PWT, Lee JE, Janjan NA, Goswitz MS, & Abbruzzese JL: Phase I trial of gemcitabine combined with radiation for the treatment of locally advanced pancreatic adenocarcinoma. 17, 1091 (1998)

## Neoadjuvant Chemoradiation

43. Hoffman JP, McGinn CJ, Szarka CE, Morphis JG, Cooper HS, Wilkes J, Nicol S: A phase I study of preoperative gemcitabine with radiation therapy followed by postoperative gemcitabine for patients with localized, resectable pancreatic adenocarcinoma. *Proc Am Soc Clin Oncol* 17, 1090 (1998)
44. Evans DB, Rich TA, Byrd DR, Cleary K, Connelly J, Levin B, Charnsangavej C, Fenoglio C, Ames F: Preoperative chemoradiation and pancreaticoduodenectomy for adenocarcinoma of the pancreas. *Arch Surg* 127, 1335 (1992)

**Key words:** Pancreas cancer, Multimodality therapy, Chemoradiation

---

Send correspondence to: Douglas B. Evans, MD, Department of Surgical Oncology, Box 106, The University of Texas M. D. Anderson Cancer Center, 1515 Holcombe Boulevard, Houston, TX 77030. Tel: (713) 794-4324, Fax: (713) 745-4426, E-mail: [devans@note.mdacc.tmc.edu](mailto:devans@note.mdacc.tmc.edu)