

ELECTROSIGMOIDOGRAM IN THE VARIOUS PATHOLOGIC CONDITIONS OF THE SIGMOID COLON

Ahmed Shafik

Department of Surgery and Experimental Research, Faculty of Medicine, Cairo University, Cairo, Egypt.

Received 7/22/98 Accepted 8/20/98

TABLE OF CONTENTS

1. Abstract
2. Introduction
3. Material and methods
 - 3.1. Subjects
 - 3.2. Methods
 - 3.3. Statistics
4. Results and Discussion
 - 4.1. Normal subjects
 - 4.2. Ulcerative colitis
 - 4.3. Sigmoid diverticulitis
 - 4.4. Sigmoid polyposis
 - 4.5. Sigmoid colon cancer
 - 4.6. Sigmoidectomy
5. Acknowledgment
6. References

1. ABSTRACT

The current study investigates the electrosigmoidographic (ESG) patterns in 50 patients with sigmoid colon pathologies and 10 healthy controls. Three electrodes were applied to the skin of the lower abdomen and the reference electrode was placed on the lower limb. Ulcerative colitis patients showed a "tachyarrhythmic" ESG; the PPs had a higher frequency with a lower amplitude and velocity than the normal controls. The sigmoid diverticulitis exhibited a "bradyarrhythmic" pattern; the PP variables were lower than normal. The PPs in sigmoid polyposis were "scarce" and were recorded only occasionally. In sigmoid colon cancer, the electric waves were normal proximal to the tumor and absent opposite and distal to it; a "silent" ESG was recorded in sigmoidectomy patients. Various ESG patterns were recordable in the different pathologic conditions of the sigmoid colon. It is thus suggested that percutaneous ESG can be included as an investigative tool in the diagnosis of sigmoid colon pathologies. The method is simple, easy, non-invasive and non-radiologic.

2. INTRODUCTION

The sigmoid colon is often the site of pathologic conditions such as ulcerative colitis, diverticulitis, polyposis and cancer. The diagnosis of these diseases depends on endoscopic and barium enema studies. Although these methods are commonly diagnostic in such lesions, yet, endoscopy and biopsy are invasive procedures.

Electric activity has been recorded from different parts of the gut in normal subjects and patients with various pathologies of the bowel (1-11). This activity manifests as slow waves or pacesetter potentials (PPs) and action potentials (APs). The PPs in normal subjects are regular

and consistent when repeated in the same individual (1-11). They are followed randomly by spikes of APs, which are inconsistent and are associated with an elevated rectal pressure (10,11). Various pathologies of the gut have been associated with characteristic electrographic irregularities (3,9,12-19).

Electric activity has also been recorded from the sigmoid colon as PPs and APs (20). The electrodes were applied to the sigmoid colon through its lumen. A normal electrosigmoidogram (ESG) could be characterized for the healthy volunteers (20). The procedure was performed percutaneously (21) and the electric signals were confirmed by the intrasigmoid electrodes. The PPs were recorded as regular negative deflections. They had constant frequency, amplitude and velocity of conduction when recordings were repeated in the same subject. The APs followed the PPs and were inconsistent. The PPs registered transcutaneously had the same amplitude, frequency and velocity as those recorded intrasigmoidally (20,21). However, APs could be registered only intrasigmoidally and not transcutaneously (20,21). The intervening abdominal wall and the inconsistency and low amplitude of APs seem to impede their recording transcutaneously.

The current communication describes the transcutaneous ESG in the various pathologic conditions of the sigmoid colon aiming at evaluating its possible role as an investigative tool in the diagnosis of such conditions.

3. MATERIAL AND METHODS

3.1. Subjects

The study was comprised of 60 subjects: 15 patients with ulcerative colitis, 12 with diverticulitis, 8 with

Table 1. Clinical data of the 60 studied subjects.

Condition	No.	Mean age (years)	Sex		Mean duration of symptoms (months)
			M	F	
Healthy volunteers	10	46.3 ± 8.5	7	3	-
Ulcerative colitis	15	38.6 ± 6.8	8	7	96.2 ± 21.3
Diverticulitis	12	61.3 ± 4.2	7	5	86.4 ± 18.2
Sigmoid polyposis	8	21.3 ± 2.3	4	4	52.2 ± 6.2
Sigmoid cancer	9*	53.2 ± 8.8	6	3	7.3 ± 2.1
Sigmoidectomy	6	50.3 ± 7.7	6	-	5.2 ± 2.8

* All patients were Duke's C stage.

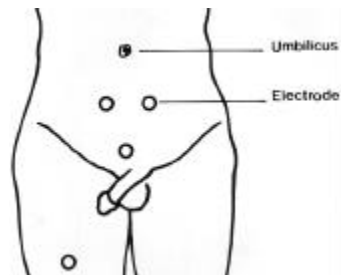


Figure 1. The sites of the electrodes



Figure 2. Percutaneous electrosigmoidogram from a normal control subject showing regular pacesetter potentials.



Figure 3. Percutaneous electrosigmoidogram from a patient with ulcerative colitis showing a "tachyarrhythmic" pattern. The pacesetter potentials (PPs) had a higher frequency and lower amplitude and conduction velocity than normal. The PP variables were not the same from the 3 electrodes.

sigmoid familial polyposis, 9 sigmoid cancer patients, 6 patients with sigmoidectomy for sigmoid cancer and 10 healthy volunteers as controls.

Table 1 depicts the clinical data of the 60 subjects. The diagnosis of the patients had been based on radiologic and endoscopic investigations. An informed consent was obtained from each subject, and the study was approved by our Faculty Review Board and Ethical Committee. All the sigmoid cancer patients were of the Duke's C stage.

3.2. Methods

The technique of transcutaneous electrosigmoidography has been previously described (20). Briefly, with the bowel and urinary bladder empty, the subject was placed in a supine position and 3 silver-silver chloride electrodes (Smith Kline-Beckman, Los Angeles,

CA, USA) were fixed to the abdominal skin by an electrode gel (Johnson & Johnson, Warren, NJ; figure 1). One electrode was applied 2-3 cm from each side of the middle of a line drawn from the umbilicus to the symphysis pubis. A third electrode was placed just above the symphysis pubis, and a reference electrode was applied to one of the lower limbs. The signals were recorded on paper (Van Gogh EP 8b, Disa, Copenhagen) and stored on a magnetic tape (Recall Store 14, Disa, Copenhagen). High and low pass filters (6 decibel / octave) were set at 0.01 and 0.5 Hz, respectively. At least two 30-minute recording sessions were performed for each subject on different days.

3.3. Statistics

The results were analyzed statistically using the Student's t-test. Differences assumed statistical significance at $p < 0.05$ and values were given as mean \pm standard deviation (SD).

4. RESULTS AND DISCUSSION

No complications were encountered during the study and the recordings were completed in all the subjects.

4.1. Normal subjects

PPs were recorded as monophasic slow waves which consisted of negative deflections (figure 2). The frequency, amplitude, and velocity of conduction are shown in table 2. These parameters were reproducible when the examination was repeated in the same individual subject with no significant difference ($p > 0.05$). The APs could not be recorded in any of the subjects studied while the PPs were registered throughout the recording sessions.

4.2 Ulcerative colitis

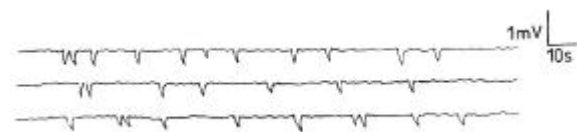
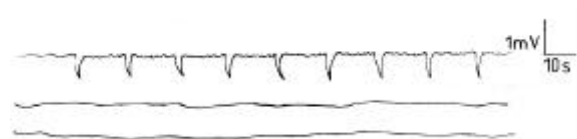The frequency of the PPs was significantly higher than normal ($p < 0.05$) while the amplitude and conduction velocity were lower ($p < 0.05$, $p < 0.05$, respectively, figure 3). The PP rhythm was irregular and PP variables were not the same from the 3 electrodes; they differed from one electrode to the other in the same subject (figure 3). The pattern in each electrode was preserved i.e. the PPs frequency was higher and amplitude and velocity were lower than normal (figure 3). This "tachyarrhythmic" pattern was reproducible when the test was repeated in the same individual subject.

4.3. Sigmoid diverticulitis

The PPs showed variable frequency, amplitude

Table 2. The frequency, amplitude and velocity of conduction of the pacesetter potentials of the 60 studied subjects.

		Pacesetter potentials					
Condition	No	Frequency (cpm)		Amplitude (mV)		Velocity (cm/s)	
		Mean	Range	Mean	Range	Mean	Range
Healthy Volunteers	10	3.8 ± 1.6	3-6	0.9 ± 0.3	0.6-1.2	4.1 ± 1.1	3-5
Ulcerative Colitis	15	6.3 ± 2.1	7-10	0.4 ± 0.1	0.3-0.7	2.6 ± 0.8	2-4
Diverticulitis	12		Variable				
Polypsis	8		Occasional PPs				
Cancer	9		Silent ESG facing the tumor and distal to it				
Sigmoidectomy	6		Silent ESG				

**Figure 4.** Percutaneous electrosigmoidogram from a patient with sigmoid diverticulitis showing a “bradyarrhythmic” pattern. The frequency, amplitude and conduction velocity were lower than normal. The PP variables were not the same from the 3 electrodes.**Figure 5.** Percutaneous electrosigmoidogram from a patient with sigmoid cancer. Showing pacesetter potentials recorded from the electrode proximal to the tumor but not from the electrodes facing the tumor or distal to it.**Figure 6.** Percutaneous electrosigmoidogram from a patient with sigmoid colectomy showing a “silent” electrogram. No pacesetter potentials were recorded.

and velocity of conduction which differed from one electrode to the other in the 3 electrodes applied to the same subject (figure 4). Their frequency, amplitude and conduction velocity were, in general, lower than normal. This pattern of “bradyarrhythmia” was repeatable in the same patient.

4.4. Sigmoid polyposis

The electric activity in the 8 patients with sigmoid colon polyposis, which was a part of the whole colonic polyposis, was scarce and occasionally recorded. Ten minutes might have elapsed without recording PPs. However, during the 30-minute recording period, few random PPs were registered. They had a variable frequency, amplitude and conduction velocity which differed from one electrode to the other in the same patient. This “scarce” pattern was reproducible when the recording was repeated in the same individual subject. The PPs were recorded more frequently in the patients in whom the number of sigmoid polyps was less as shown by endoscopy, barium enema and in the post-operative

specimens. Microscopic examination of the polyps showed that they were benign, arose from the sigmoid mucosa and did not involve the muscle layer of sigmoid colon.

4.5. Sigmoid colon cancer

The electric activity which was recorded was different from the 3 electrodes, depending on the position of the cancer relative to the electrodes. PPs were recorded from the electrodes proximal to the tumor but not from that facing, or distal to, the tumor (figure 5). The frequency, amplitude and conduction velocity of the PPs were similar to those recorded from normal volunteers. The position of the electrodes in relation to the sigmoid colon was confirmed by barium enema and validated after sigmoidectomy.

4.6. Sigmoidectomy

The 8 patients who had undergone sigmoidectomy for sigmoid cancer showed no electric activity (figure 6). No PPs were registered and a “silent” electrosigmoidogram was obtained from all the recording sessions.

The aforementioned results were reproducible with no significant difference when the recordings were repeated in the same subject.

The current study has demonstrated various electrosigmoidographic patterns in pathologic conditions of the sigmoid colon which differed from those of the normal volunteers. In ulcerative colitis, a “tachyarrhythmic” ESG was recorded. The increased PP frequency seems to be related to the inflammatory process of the colon which is believed to irritate the bowel wall and to lead to an increase in its electric activity. Meanwhile, the irregular rhythm and diminished amplitude and conduction velocity of the PPs appear to be due to the ulceration and scarring of the sigmoid musculature. It is postulated that the electric waves are transmitted along the gut wall through its musculature or the myenteric plexus (22).

The lower frequency, amplitude and conduction velocity of the PPs in sigmoid diverticulitis compared to those in the normal volunteers may be attributable to the spasm of the sigmoid musculature which occurs commonly in diverticulitis. The irregularity of variables of the PPs is probably due to the presence of the diverticuli interrupting the sigmoid musculature and consequently the wave propagation. These factors might explain the “bradyarrhythmic” ESG in sigmoid diverticulitis.

There is no explanation for the scarce electric activity in sigmoid polyposis since, according to histologic evidence (23), the musculature in the sigmoid colon of familial polyposis is not involved in the pathologic process. The absence of the electric activity in the colonic wall of these patients may be due to a genetic defect in the sigmoid musculature. A further study is needed to clarify this point.

The absence of electric activity from the area facing the tumor is believed to be due to infiltration of the sigmoid musculature by the malignant tumor since all tumors in the 8 studied patients were in Duke's C stage. The interruption of muscularis seems to explain also the absence of waves from the sigmoid colon distal to the tumor. These findings suggest that the PPs spread in the sigmoid proximo-distally.

In conclusion, various ESG patterns could be recorded in the different pathologic conditions of the sigmoid colon. These comprise tachyarrhythmic ESG in ulcerative colitis, bradyarrhythmia in sigmoid diverticulitis, scarce waves in polyposis, absent waves in the area facing malignant tumors and silent ESG after sigmoidectomy. Percutaneous ESG is a simple, easy, non-invasive and non-radiologic procedure which records the electric activity of the sigmoid colon. In view of the aforementioned findings, the ESG may serve as a non-invasive investigative tool for the diagnosis of sigmoid colon pathologies.

5. ACKNOWLEDGMENT

Waltraut Reichelt and Margot Yehia assisted in preparing the manuscript.

6. REFERENCES

1. J. Berkson, E.J. Baldes & W.C. Alvarez: Electromyographic studies of gastrointestinal tract. *Am J Physiol* 102, 683 - 692 (1932)
2. J. Berkson: Electromyographic studies of the gastrointestinal tract. *Am J Physiol* 104, 67 - 72 (1933)
3. H. Geldof, E.J. Van der Schee, M. Van Blankenstein & J.L. Grashuis: Electrogastrographic study of gastric myoelectrical activity in patients with unexplained nausea and vomiting. *Gut* 27, 799 - 808 (1986)
4. J.C. Schang & G. Devroede: Fasting and postprandial myoelectric spiking in the human sigmoid colon. *Gastroenterology* 85, 1048 - 1053 (1983)
5. M. Dapoigny, J.F. Trolese, G. Bommerlae & R. Tournut: Myoelectric spiking activity of right colon, left colon and rectosigmoid of healthy humans. *Dig Dis Sci* 33, 1007 - 1012 (1988)
6. J. Frexinos, L. Bueno & J. Fioramonti: Diurnal changes in myoelectric spiking activity of the human colon. *Gastroenterology* 88, 1104 - 1110 (1985)
7. P. Kerlin, A. Zinsmeister & S. Phillips: Motor response to food of the ileum, proximal colon and distal colon of healthy humans. *Gastroenterology* 84, 762 - 770 (1983)
8. D. Garcia, G. Hita, B. Mompean, A. Hernandez, E. Pellicer, G. Morales & P. Parilla: Colonic motility:

- Electric and manometric description of mass movement. *Dis Colon Rectum* 34, 577 - 584 (1991)
9. G. Bassotti, A. Morelli & W.E. Whitehead: Abnormal rectosigmoid myoelectric response to eating in patients with severe idiopathic constipation (slow transit type). *Dis Colon Rectum* 35, 753 - 756 (1992)
 10. A. Shafik: Study of the electrical and mechanical activity of the rectum. Experimental study. *Eur Surg Res* 26, 87 - 93 (1994)
 11. A. Shafik: Study of the electromechanical activity of the rectum. II-Human study. *Coloproctology* 15, 215-217 (1993)
 12. T.L. Abell & J.R. Malagelada: Glucagon - evoked gastric dysrhythmias in humans shown by an improved electrogastrographic technique. *Gastroenterology* 88, 1932-1940 (1985)
 13. T.L. Abell, J.R. Malagelada, A.R. Lucas, M.L. Brown, M. Camilleri, V.L.W. Go, F. Azpiroz, C.W. Callaway, P.C. Kao, A.R. Zinsmeister & D.M. Huse: Gastric electromechanical and neurohormonal function in anorexia nervosa. *Gastroenterology* 93,958-965 (1987)
 14. F. Pezzolla, G. Riezzo, M.A. Maselli & I. Giorgio: Gastric electric dysrhythmia following cholecystectomy in humans. *Digestion* 49, 134-139 (1991)
 15. A. Shafik: Electrorectography in chronic constipation. *World J Surg* 19,772-775 (1995)
 16. A. Shafik: Electrorectogram in chronic proctitis. *World J Surg* 17,675-679 (1993)
 17. A. Shafik: Electrorectogram in the neuropathic rectum. *Paraplegia* 33,146-149 (1995)
 18. A. Shafik, A. Nour & A. Abdel-Fattah: Transcutaneous electrorectography. Human electrorectogram from surface electrodes. *Digestion* 56,479-482 (1995)
 19. A. Shafik: Electroesophagogram in achalasia of the esophagus. *Dis Esophagus* 9, 210-214 (1996)
 20. A. Shafik: Electrosigmoidogram, electrorectogram and their relation. *Front Biosci* 2, b12-16 (1997) PubMed No. 9294095
 21. A. Shafik: Transcutaneous electrosigmoidography. Study of the myoelectric activity of sigmoid colon by surface electrodes. *Front Biosci* 1, b1-4 (1996) PubMed No. 9159196
 22. A. Shafik: A study of the origin of the electric activity of the rectum. Is it neurogenic or myogenic? *Spinal Cord* 36, 548-553 (1998)
 23. M.R.B. Keighley & N.S. Williams: Polyposis Syndromes. In: Surgery of the Anus, Rectum and Colon. Eds: Keighley M.R.B. & Williams N.S. WB Saunders Co Ltd, London, 801-829 (1993)

Key words: Sigmoid colon, Slow waves, Pacesetter potentials, Ulcerative colitis, Cancer, Diverticulitis, Action potentials

Send correspondence to : Ahmed Shafik, MD, PhD, 2 Talaat Harb Street, Cairo, Egypt, Tel/Fax: +20-2-349 8851