

Review

COVID-19 and myocarditis: a brief review

Fatma Taher^{1,†}, Athar Eysa^{2,†}, Dalia Fahmy^{3,†}, Ahmed Shalaby², Ali Mahmoud²,
Moumen El-Melegy⁴, Ahmed Abdel Khalek Abdel Razek³, Ayman El-Baz^{2,*}

¹The College of Technological Innovation, Zayed University, 19282 Dubai, UAE

²Bioengineering Department, University of Louisville, Louisville, KY 40292, USA

³Department of Diagnostic Radiology, Mansoura faculty of medicine, 13551 Mansoura, Egypt

⁴Department of Electrical Engineering, Assiut University, 71515 Assiut, Egypt

*Correspondence: aselba01@louisville.edu (Ayman El-Baz)

†These authors contributed equally.

Academic Editor: Graham Pawelec

Submitted: 13 August 2021 Revised: 14 December 2021 Accepted: 15 December 2021 Published: 21 February 2022

Abstract

Cardiovascular complications (especially myocarditis) related to COVID-19 viral infection are not well understood, nor do they possess a well recognized diagnostic protocol as most of our information regarding this issue was derived from case reports. In this article we extract data from all published case reports in the second half of 2020 to summarize the theories of pathogenesis and explore the value of each diagnostic test including clinical, lab, ECG, ECHO, cardiac MRI and endomyocardial biopsy. These tests provide information that explain the mechanism of development of myocarditis that further paves the way for better management.

Keywords: COVID-19; Myocarditis; SARS-CoV-2

1. Introduction

In December 2019, coronavirus disease 2019 (COVID-19) was first discovered in Wuhan, China [1]. The disease is caused by SARS-CoV-2. It presents with cough, fever, sore throat, fatigue and headache [2]. In early March 2020, World Health Organization has declared COVID-19 as a pandemic [3]. As of 30th of Jan 2021, the number of COVID-19 cases worldwide according to WHO is 102 M and number of deaths related to COVID-19 is 2.2 M [4]. COVID-19 causes a spectrum of complications involving different systems in the body including the cardiovascular system such as acute MI, acute pericarditis, dysfunction of left ventricle, arrhythmia and heart failure that can develop newly or worsen, acute right sided heart failure due to massive pulmonary embolism [5] and cardiomyopathy, either due to stress or myocardial injury related to sepsis [6]. A bidirectional relationship between COVID-19 infection and cardiovascular diseases exists; infection with SARS-CoV-2 virus can worsen pre-existing cardiac conditions and develop new emerging ones [7]. Patients who had myocardial injury/myocarditis have shown a higher mortality rate and a higher risk of mechanical ventilation during hospitalization [8]. According to CDC, patients who had COVID-19 between March 2020 to January 2021 were at risk of developing myocarditis 15.7 times more than those without COVID-19 [9]. A study in patients with COVID-19 reported new onset arrhythmia requiring intensive care in 16 patients out of 36 patients [2]. COVID-19 related myocarditis has been reported in case reports and reviews; however, the pathophysiology remains unclear.

Although COVID-19 cardiac injury and myocarditis increase morbidity and mortality [10,11], the exact pathophysiology is yet to be fully understood and that renders the management challenging. Several hypotheses to understand the pathogenesis of myocarditis caused by SARS-CoV-2 include: (A) Direct damage to cardiomyocyte by the virus. SARS-CoV-2 can enter cardiomyocyte through the binding of the virus S spike protein to angiotensin converting enzyme 2 (ACE2) that can be found on the epithelium of type 2 pneumocyte in lungs and on cardiomyocytes [11–13]. SARS-CoV-2 could impair stress granule formation once it is intracellular, leading to viral replication and cell damage [7]. The use of ACE2 receptor type 1 blockers and ACE inhibitors during treating COVID-19 hypertensive patients is a matter of controversy because the viral interaction with ACE2 downregulates the anti-inflammatory function and increase angiotensin 2 effect in predisposed patients [14]. However, the current recommendation of the Council on Hypertension of the European Society of Cardiology is to continue using these medications as prescribed without changes due to lack of evidence to do otherwise, but with further research and assessment [15]. (B) Severe inflammation and cytokine storm with overproduction of inflammatory cytokines attributed to loss of negative feedback within the immune system. Here, an overwhelming immune response to a trigger ensues, and results in a rapid clinical decline and high mortality [16]. The disorganized T1 and T2 helper cells' response leads to severe systemic inflammation causing cardiomyocyte hypoxia and apoptosis. Once a cell is infected with COVID-19, primary immune system secretes proinflammatory cytokines and inter-



ferons [17]. SARS-CoV-2 has a non-structure protein that is 92% identical to a protein in SARS-CoV-1. The function of this protein is to hide the virus from the double stranded RNA pattern recognition receptors on host cells. This protein shares in inhibiting interferons production [16]. Interferons act as the first line of defense against viral infections, and since there is a delayed secretion of interferons from SARS-CoV-2 infected cells in early stages of infection, viral replication continues and attraction of inflammatory cells to involved tissues increases. This mechanism leads to severe inflammation and damage in lung and heart [17]. (C) Type II Hypersensitivity, antibody mediated autoimmunity. This theory is based on the effects of B cells and their antibody products in animal models with myocarditis [18–23]. Immune system could produce autoantibodies due to molecular mimicry between viral antigens and self-antigens, and release of self-antigens from virally infected cardiomyocytes [18].

There is no clear diagnostic approach to COVID-19 myocarditis. After reviewing case-reports and review articles, in this paper we summarize the theories of COVID-19 related cardiac injury pathogenesis and the diagnostic work-up.

2. Materials and methods

For theories explaining how COVID-19 infection can affect the cardiac muscle and cause myocarditis, we searched electronic databases including PubMed/Medline and google scholar using the keywords “COVID-19”, “Myocarditis”, “SARS-CoV-2”, and “pathogenesis”.

For the case reports, we searched PubMed/Medline from July 1, 2020 to May 29, 2021. We used the following keywords in different combinations: (COVID-19, SARS CoV 2, SARS-CoV-2 coronavirus or novel coronavirus) with “myocarditis” or “myopericarditis”. Our search was limited to case reports, and our exclusion criteria included case reports in a language other than English and patients less than 19 years old. Our search followed PRISMA guidelines, and the flowchart summarizes our search process in Fig. 1. We found 57 case reports, and one reviewer identified 32 relevant case reports. Two case reports reported 2 cases each, but in one of the reports the second patient was excluded due to age limitation (less than 19 years old). Thus, the total number of patients included in our review is 33. For all the included cases, we collected age and gender besides clinical data including clinical presentation, inflammatory markers, cardiac-related markers, cardiac testing (ECG and EMBs) and cardiac imaging (Echocardiography, CMRI, coronary angiogram and CT).

3. Results

Thirty two case reports describing a total of thirty three cases that document myocarditis/myopericarditis attributed to COVID-19 infection reported from July 1, 2020 to May 29, 2021 [3–17,24–40]. Occurrence of myocarditis related

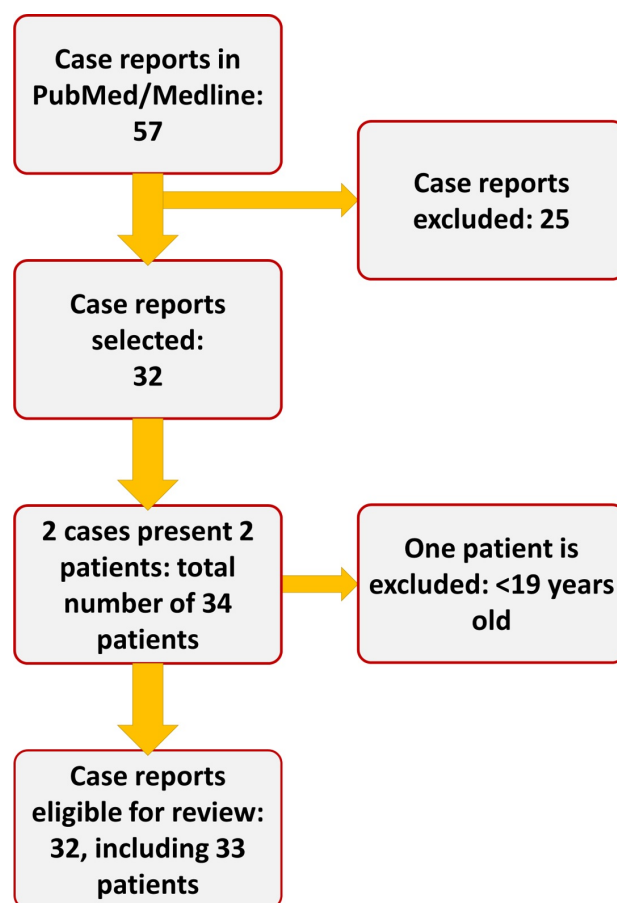


Fig. 1. The flowchart of our search process.

to COVID-19 in males was higher than females (72.7%), and the median age of the reported cases was 49 years.

48.27% of cases didn't have past medical history of significant co-morbidity. In cases with positive past medical history, obesity and hypertension history were equally predominant (33.3%), and respiratory disease history came after (20%). The common presenting symptoms included dyspnea and/or shortness of breath (51.5%), Fever and/or chills (51.5%), and chest pain and/or chest tightness (33.3%). We included full medical history and presenting symptoms in (Table 1, Ref. [24–54]). Fourteen patients developed shock, 4 patients developed septic or distributive shock and 7 patients developed cardiogenic shock. Five cases presented with acute respiratory distress syndrome (ARDS) or developed it during hospitalization. Outcome was recorded for 26 patients, of which 21 patients fully recovered or recovered with residual exercise intolerance (80.8%).

PCR testing for COVID-19 diagnosis was performed in 27 cases (81.8%). 19 cases (70.37% of those who were tested) were positive for COVID-19 RNA, and 8 cases were negative.

Table 1. Demographic features and clinical presentations.

Case report	Age and gender	Past medical history	Presentation	Shock: Y/N	ARDS: Y/N	Outcome
Jia-Hui Zeng <i>et al.</i> [6]	63 Male	allergic cough, history of smoking	Fever, shortness of breath, chest tightness after activity	Y; septic	Y	Death
Jean-François Paul <i>et al.</i> [35]	35 Male	Overweight (BMI: 29 kg/m ²)	Chest pain, fatigue	N	N	Recovery
Jared Radbel <i>et al.</i> [36]	40 Male	None	Fever, dry cough, dyspnea on exertion	Y; septic	Y	Death
Richa Purohit <i>et al.</i> [37]	82 Female	Multiple co-morbidities (not specified)	Productive cough, fever with chills, intermittent diarrhea	N	N	Not reported
Ahmet Yasar Cizgic <i>et al.</i> [38]	78 Male	Hypertension	Chest pain, shortness of breath	Not reported	Y	Not reported
Philip Wenzel <i>et al.</i> [39]	(A) 39 Male	Obesity, history of upper airway infection 4 weeks before admission (suspected COVID-19)	Shortness of breath	N	N	Recovery
	(B) 36 Male	Obesity, CAD, history of upper airway infection 4 weeks before admission (suspected COVID-19)				
Muhammed Said Beşler <i>et al.</i> [40]	20 Male	None	Febrile sensation, chest pain	N	N	Recovery
Akshay Khatri <i>et al.</i> [45]	50 Male	Hypertension, ischemic stroke	Fevers, chills, generalized malaise, non-productive cough, dyspnea for 3–4 days, an episode of near-syncope	Y; cardiogenic and distributive	N	Death
Havard Dalen <i>et al.</i> [46]	55 Female	Not reported	Fatigue, near-syncope, body and chest discomfort	Y	N	Recovery
Meylin Caballeros Lam <i>et al.</i> [47]	26 Female	Gestational DM	(A) Chest pain radiating to her left arm, tachycardia	(A) Not reported	(A) Not reported	(A) Not reported
Tamara Naneishvili <i>et al.</i> [48]	44 Female	None	Febrile illness, lethargy, muscle aches, two episodes of syncope	Y; cardiogenic	N	Recovery

Table 1. Continued.

Case report	Age and gender	Past medical history	Presentation	Shock: Y/N	ARDS: Y/N	Outcome
Alexandra Othenin-Girard <i>et al.</i> [49]	22 Male	None	Asthenia, chills, diffuse myalgia, abdominal pain and diarrhea	Y; cardiogenic	N	Recovery
Juan Carlos Ruiz-Rodríguez <i>et al.</i> [50]	65 Male	None	Community acquired pneumonia by SARS-CoV-2	Y; distributive	N	Death
Jorge Salamanca <i>et al.</i> [51]	44 Male	None	Fever, dry cough, diarrhea, myalgia before admission. Followed by severe dyspnea, syncope, severe bradycardia, hypotension, signs of peripheral hypoperfusion	Y	N	Recovery
Giancarlo Spano <i>et al.</i> [52]	49 Male	None	Dyspnea, general weakness, intermittent epigastric pain, nocturia	Not reported	Not reported	Not reported
Heiko Pietsch <i>et al.</i> [53]	59 Female	None	Dyspnea	N	Y	Recovery
Sebastiano Recalcati [54]	19 Female	None	Fever for 4 days, cutaneous rash, chest pain	N	N	Recovery
G. Perez-Acosta <i>et al.</i> [41]	61 Male	Obesity	Progressive dyspnea of 5 days, severe hypoxemic respiratory failure	Y	N	Recovery
Hamam Rasras <i>et al.</i> [42]	47 Female	None	Fever, cough for 20 days, severe dyspnea, pain in both lower limbs	Y; cardiogenic	N	Recovery
Daniel Z. Hodson <i>et al.</i> [24]	29 Mal	Asthma	Shortness of breath, wheezing, tachycardia, exercise intolerance after previous admission with confirmed COVID-19 2 months before	Not reported	Not reported	Not reported
Nicholas Berg <i>et al.</i> [43]	66 Male	Heart transplant, dystonic muscle dystrophy type 2, hypertension, chronic kidney disease, prostate cancer	Shortness of breath, dyspnea on exertion, fatigue	Not reported	Not reported	Not reported

Table 1. Continued.

Case report	Age and gender	Past medical history	Presentation	Shock: Y/N	ARDS: Y/N	Outcome
Stefan Roest <i>et al.</i> [44]	50 Male	Dilated cardiomyopathy, heart transplant	Cardiac decompensation after several months of positive COVID-19 infection	N	N	Recovery
Yale Tung-Chen <i>et al.</i> [25]	25 Male	None	Diffuse abdominal pain, nausea, fever, fatigue, anosmia, orthopnea, sore throat	Not reported	N	Recovering
Abu Baker Sheikh [26]	28 Male	None	Cough, shortness of breath, chest pain, mild headache and nausea, COVID-19 infection a month before these complains	N	N	Recovery
Ina Volis <i>et al.</i> [27]	21 Male	None	Fever	N	N	Recovery
Suzan Hatipoglu <i>et al.</i> [28]	63 Male 58 Female	Not reported Type 2 diabetes mellitus, hypertension	Exercise induced chest pain 50 days after diagnosis of COVID-19	N	N	Recovery
Lauren Cairns <i>et al.</i> [29]	37 Male	None	Fever for 10 days, diarrhea for 7 days, vomiting, poor oral intake	Y; cardiogenic	N	Recovery
Elin Hoffmann Dahl <i>et al.</i> [30]	21 Male	None	Fever, headache, unilateral painful neck swelling	Y	Y	Recovery, exercise intolerance
Guillaume Gauchotte <i>et al.</i> [31]	69 Male	Diabetes mellitus, hypertension, ischemic heart disease	Fever, asthenia, abdominal pain	Y; cardiogenic	N	Death
Andrea Baggiano <i>et al.</i> [32]	59 Male	Not reported	Worsening dyspnea	Not reported	Not reported	Not reported
Moti Gulersen <i>et al.</i> [33]	31 Female	Childhood asthma, obesity class I	1 day of fever and left sided chest pain (worse with inspiration), shortness of breath, +ve COVID-19 infection 4 weeks before this complain	Y; cardiogenic	N	Recovery
Pierre Gravinay <i>et al.</i> [34]	51 Male	Not reported	Fever, arthromyalgia, dyspnea, atypical chest pain	Not reported	Not reported	Not reported

Table 2. COVID-19 diagnostic PCR, cardiac imaging and laboratory investigation.

Case	COVID-19 test	Electrocardiogram	Echocardiogram	Cardiac biomarkers	Additional cardiac testing	Inflammatory markers
Jia-Hui Zeng <i>et al.</i> [6]	+ve Sputum testing	Sinus tachycardia, no ST-segment elevation	Enlarged left ventricle (61 mm), diffuse myocardial dyskinesia, low LVEF 32%, pulmonary hypertension, No right cardiac function decline, no pericardial effusion	Troponin I 11.37 g/L, myoglobin 390.97 ng/mL, NT-BNP 22,600 pg/mL	None	IL-6 272.40 pg/mL
Jean-François Paul <i>et al.</i> [35]	PCR: +ve Specimen unspecified	Repolarization changes in the precordial ECG leads	Normal systolic function with no pericardial effusion	hs-cTnI levels 2885 ng/L peak	CMRI: late subepicardial enhancement predominating in the inferior and lateral walls	None
Jared Radbel <i>et al.</i> [36]	NP-PCR: +ve	ST segment depression in leads V4-V6, mild global hypokinesis	Not done	Troponin T peak 30.39	Swan-Ganz catheter measurements confirmed a reduced cardiac index	CRP peak 44.1 mg/dL IL-6 peak 345 pg/mL, Ferritin 38,299 ng/mL LDH 5517 IU/L
Richa Purohit <i>et al.</i> [37]	PCR: +ve Unspecified specimen	Diffuse T-wave inversions and a prolonged QT interval	Preserved LV function, small global pericardial effusion, apical hypokinesis Serial echocardiogram: enlarging circumferential pericardial effusion, pacemaker wire reported as 'piercing' RV apex, early diastolic collapse of the RV, suggesting tamponade	Mildly elevated Troponin	None	None
Ahmet Yasar Cizgic <i>et al.</i> [38]	Not done, Dx by CT finding	Atrial fibrillation, 150 bpm, concave ST elevation except for aVR lead	Not done fear of COVID-19 transmission	Troponin T 998.1 ng/L	-Coronary angiography: no significant pathology -CT Chest: mild pericardial effusion -CMRI: not done due to precautions for COVID-19 transmission	CRP 94.6 mg/L

Table 2. Continued.

Case	COVID-19 test	Electrocardiogram	Echocardiogram	Cardiac biomarkers	Additional cardiac testing	Inflammatory markers
Philip Wenzel <i>et al.</i> [39]	(A) NP PCR: -ve	(A) T-wave inversion in the anterolateral leads	(A) preserved LV systolic function, EF 60%, no wall motion abnormalities, focal echo-bright appearance of the IVS and slightly impaired global longitudinal strain	(A) elevated natriuretic peptides, elevated cardiac troponin I	(A)-CMRI: prolonged T1 relaxation times in the posterior IVS and corresponding LGE with enhancement in the posterior septum, consistent with acute myocarditis -EMB: (1) myocardial inflammation in the absence of cardiomyocyte necrosis (2) RT-PCR for SARS-CoV-2-specific nucleic acid: +ve (-ve NP PCR for COVID-9)	(A) Not reported
	(B) NP-PCR: -ve	(B) T-wave inversions in the anterolateral leads	(B) LV dysfunction, reduced LVEF 30%, decreased global and regional longitudinal strain, increased LVED diameter	(B) elevated natriuretic peptides, elevated cardiac troponin I	(B)-CMRI: diffuse myocardial edema, LGE image with subtle subepicardial enhancement of the lateral wall -EMB: (1) myocardial inflammation in the absence of cardiomyocyte necrosis (2) RT-PCR for SARS-CoV-2-specific nucleic acid: +ve (-ve NP PCR for COVID-19)	(B) Not reported
Muhammed Said Beşler <i>et al.</i> [40]	NP-PCR: +ve	Not reported	Not reported	Troponin I 7.621 ng/mL, CK-MB 21.92 µg/L, NT-proBNP 1525 ng/L	-CMRI: myocardial edema and LGE compatible with myocarditis -T2 short tau inversion recovery (STIR) sequence: myocardial wall edema Suggested by subepicardial high signal intensity in the mid posterolateral wall of the LV	CRP 81.2 mg/L

Table 2. Continued.

Case	COVID-19 test	Electrocardiogram	Echocardiogram	Cardiac biomarkers	Additional cardiac testing	Inflammatory markers
Akshay Khatri <i>et al.</i> [45]	NP-PCR: +ve	Sinus tachycardia, ST-elevation in leads II, III, aVF, ST-depression in I, aVL	severe global LVSD, RVSD and enlargement Moderate-to-large inflammatory pericardial effusion anterior to the RV, intermittent RV impaired filling and collapse, suggestive of tamponade	High Sensitivity Troponin 544 ng/L, CK 2135 U/L, CK-MB 54.3 ng/mL	-Coronary angiography: right dominant circulation, normal coronary vessels -Cytologic analysis of pericardial fluid: reactive mesothelial cells	CRP 11.85 mg/dL ESR 46 mm/hr LDH 3332 U/L ESR 46 mm/hr Ferritin 66,165 ng/mL
Havard Dalen <i>et al.</i> [46]	+ve Unspecified specimen	Sinus tachycardia, insignificant ST-elevation in inferior leads, T-wave inversion in precordial leads, low-voltage ECG with peak-to-peak QRS amplitude less than 5 mm in the standard leads and 10 mm in V5 and V6	Moderate concentric LVH with a small cavity, EDV <70 mL, endocardial hyperechogenic pattern. epicardial signs of a tamponade: compression of the RA, dilated IVC without inspiratory diameter reduction, respiratory variation in volumes and flow velocities	Troponin T 198 ng/L, NT-proBNP 2038 ng/L	-Cardiac US: moderate concentric LVH, reduced LVEF, dilated IVC with reduced respiratory variation and pericardial effusion at a maximum of 18 mm, a small RV and a slight impression of the RA -Pericardial fluid PCR COVID-19 testing: -ve -CMRI: consistent with the diagnosis of acute perimyocarditis. T1-mapping: relaxation times of 1260–1270 ms in the anterolateral wall compared with 1090 ms in the septum. T2-mapping: relaxation times were 60–61 ms and 52–53 ms, respectively -Inversion recovery sequences: moderate epicardial LGE in the anterolateral wall EMB: postponed due to rapid improvement and COVID-9 precautions	CRP 89 mg/dL

Table 2. Continued.

Case	COVID-19 test	Electrocardiogram	Echocardiogram	Cardiac biomarkers	Additional cardiac testing	Inflammatory markers
Meylin Ca- balleros Lam <i>et al.</i> [47]	+ve PCR	Normal	Normal	Troponin T 319.4 ng/L	-CMRI: High signal intensity on T ₂ maps (53 ms, normal value <48 ms), prolonged native T ₁ values in basal and mid-inferoseptal and inferior myocardial segments (1303 ms, normal value <1200 ms). LGE showed mesocardial and subepicardial enhancement of those segments, representing 14.2% of the total ventricular mass CMRI suggested Dx of myocarditis. -EMB: not done	Not reported
Tamara Naneishvili <i>et al.</i> [48]	NP-PCR: +ve	Atrial fibrillation with 177 bpm ventricular rate	Moderate concentric biventricular hypertrophy, diffuse LV hypokinesia, moderate to severe LVSD, estimated LVEF 37% by Simpsons, pericardial effusion with no signs of tamponade	Troponin I 639 ng/L, CK 1403 U/L	-CMRI was not feasible due to the patient's critical condition and was deferred for a later date	CRP 126 mg/L
Alexandra Othenin-Girard <i>et al.</i> [49]	NP-PCR: +ve	Third-degree AV block, transient ST segment elevation in the anterolateral leads	Not done	Troponin T 2718 ng/L, CK 768 U/L, MB fraction 16% High	-EMB: (1) severe myocardial inflammation with several foci of myocyte necrosis (2) PCR for COVID-19: -ve -Coronary angiogram: aneurysm of the proximal left anterior descending coronary artery	CRP 275 mg/L

Table 2. Continued.

Case	COVID-19 test	Electrocardiogram	Echocardiogram	Cardiac biomarkers	Additional cardiac testing	Inflammatory markers
Juan Carlos Rodríguez <i>et al.</i> [50]	+ve Not specified	Not reported	No abnormalities	hs-cTnI 192 ng/L	-Transthoracic US: a 3-centimeter-thick pericardial effusion in the anterior and posterior compartment without RV dilation -Pericardial fluid culture: -ve for COVID-19 -EMB: not done	IL-6 996 pg/mL
Jorge Salamanca <i>et al.</i> [51]	NP and OP PCR: +ve	Third-degree AV block	Nondilated LV with diffuse and severe dysfunction, LVEF~15%	hs-cTnT peak 745 ng/L, CK-MB 30 U/L, NT-proBNP 24,167 pg/mL	-Coronary angiography: normal coronary arteries -CMRI: A nondilated LV without regional wall motion abnormalities, LVEF ~75%. Native T1 (mean, 1120 ms), T2 signal intensity ratio (myocardium to serratus anterior muscle on T2 images processed using a signal intensity correction algorithm), and extracellular volume (mean, 36%) were diffusely increased with less involvement of the inferolateral wall. LGE was negative CMRI findings suggesting diffuse edema without macroscopic necrosis -EMB: no significant inflammatory infiltrates, necrosis, inflammation, or fibrosis	IL-6 121.71 pg/L

Table 2. Continued.

Case	COVID-19 test	Electrocardiogram	Echocardiogram	Cardiac biomarkers	Additional cardiac testing	Inflammatory markers
Giancarlo Spano <i>et al.</i> [52]	Nasal PCR: -ve IgG blood test: +ve	Dynamic T-wave changes	Diffuse hypokinesia with severely depressed RV and LV function	elevated troponin and NT-proBNP	-CT of lungs: no pulmonary embolism, no infiltrates, left heart congestion -CMRI: edema causing diffuse thickening of the myocardium and pericardium, pericardial effusion could be seen, tissue characterization revealed diffuse LGE, elevated T1 mapping values and an elevated extracellular volume fraction of 38% (normal value: <30%), indicating diffuse fibrosis. Global myocardial strain of all heart chambers was diffusely impaired diagnosing peri-myocarditis	High CRP
Heiko Pietsch <i>et al.</i> [53]	NP-PCR: -ve	Not reported	Severe diastolic dysfunction III, increased wall thickness (IVS 14 mm), minimal pericardial effusion	hs-cTnT 83.6 pg/mL, CK 125 U/L, CK-MB 43 U/L	EMB: +ve SARS-CoV-2 RNA, intramyocardial inflammation without signs of necrosis -follow-up EMB, 3 weeks after the first EMB: -ve SARS-CoV-2 RNA, reduction of inflammatory cell infiltration	Not reported
Sebastiano Recalcati [54]	NP PCR: +ve	sinus tachycardia, diffuse ST-segment elevation	normal ventricular function, no pericardial effusion	Troponin T 367 ng/L	None	CRP 23.10 mg/L
G. Acosta <i>et al.</i> [41]	Perez-PCR: +ve	Generalized concave ST elevation	Adequate LVEF, Mild to moderate pericardial effusion	Elevated cardiac damage markers (not specified)	None	None

Table 2. Continued.

Case	COVID-19 test	Electrocardiogram	Echocardiogram	Cardiac biomarkers	Additional cardiac testing	Inflammatory markers
Hammam Ras- ras <i>et al.</i> [42]	PCR: +ve	Not reported	Biventricular DCM, severe biventricular dysfunction, LVEF 10%, low cardiac index, large LV thrombus	Troponin 734 ng/L, proBNP 2215 pg/mL	None	CRP 147 mg/L, pro- calcitonin 2.9 mg/L, fibrinogen 8.7 g/L, LDH 1542 g/mol, ferritin 2150 mg/L
Daniel Z. Hod- son <i>et al.</i> [24]	+ve, Not specified	Nor reported	Severe global hypokinesia, se- vere reduction in RVEF and LVEF, biventricular thrombi	Not reported	-CXR: Enlarged cardiac sil- houette -CMRI: global hypokinesia, LVEF 13%, large ventricular thrombi, foci of myo and pericardial fibrosis with non- ischemic pattern confirming myopericarditis	LDH 1542 g/mol, fer- ritin 2150 mg/L
Nicholas Berg <i>et al.</i> [43]	+ve, Not specified	Diffuse T wave inversions.	LVEF 37%, RVD, decreased RVEF	Troponin-I 0.04 ng/mL, BNP 47 pg/mL (normal)	-EMB: no evidence of acute cellular or antibody-mediated rejection of the transplanted heart, subendocardial fibrosis and quilty leison	None
Stefan Roest <i>et al.</i> [44]	NP-PCR: +ve ELISA IgM: +ve	Not reported	First time: Normal left and right ventricular function, no valvu- lar abnormalities Second time (6 weeks after): biventricular failure and con- gestion	First evaluation: NT-proBNP 113 pmol/L Second evaluation (6 weeks af- ter): 212 pmol/L and 519 pmol/L, 2 day after hs-cTn 55 ng/L	-CT coronary: sall eccentric plaque I the proximal LAD, no significant stenosis -EMB: focal subendocardial fi- brosis, no signs of heart trans- plant rejection, negative for COVID-19 -CMRI: LVEF 35%, LGE with extensive subepicardial enhancemet, signs of no acute heart trnasplant rejection. Finding likely due to post- myocarditis without signs of active myocarditis	Not reported

Table 2. Continued.

Case	COVID-19 test	Electrocardiogram	Echocardiogram	Cardiac biomarkers	Additional cardiac testing	Inflammatory markers
Yale Tung-Chen <i>et al.</i> [25]	NP-PCR: -ve COVID-19 ab: +ve IgG and IgM	Sinus tachycardia with no other abnormalities	normal LV dimensions, severe global hypokinesia and severe LV dysfunction	hs-TnI 6182.1 ng/mL, NT-proBNP 1340 pg/mL	-FoCUS: normal left and right ventricular dimensions, severe global hypokinesia and moderate-severe LV dysfunction, small pericardial effusion without signs of cardiac tamponade	CRP 337.1 mg/L, elevated fibrinogen >1200 mg/dL
Abu Baker Sheikh [26]	PCR: +ve a month before	Accelerated junctional rhythm with retrograde conduction, nonspecific T wave changes	LV dysfunction, decreased LVEF: 30%	BNP 19600 pg/mL, Troponin 0.43 ng/mL	-CT angiogram of chest: no pulmonary emboli	CRP 32.5 mg/dL, ESR 88 mm/h, Lactate 3.5 mmol/L, procalcitonin 1.4 ng/mL
Ina Volis <i>et al.</i> [27]	PCR: +ve	Non specific findings, minimal ST depressions, T wave inversion in lead III	Not done at time of diagnosis	Troponin-I 965 ng/L	CT angiogram of chest: no pulmonary emboli, no signs of cardiac enlargement or congestion	CRP 3.87 mg/dL
Suzan Hatipoglu <i>et al.</i> [28]	PCR: +ve	Not reported	Not reported	Troponin and NT-pro BNP normal	-CMRI: high-normal left ventricular volumes, low-normal LVEF 60%, mild hypokinesia in the basal lateral wall. findings diagnostic for myocardial oedema and acute-subacute myocarditis without ischaemia infarction -CT pulmonary angiography normal	Not reported

Table 2. Continued.

Case	COVID-19 test	Electrocardiogram	Echocardiogram	Cardiac biomarkers	Additional cardiac testing	Inflammatory markers
Lauren Cairns <i>et al.</i> [29]	NP-PCR: +ve	Not reported.	pericardial effusion, cardiac tamponade	hs-Tn 3532.9 ng/L	CT chest: pericardial effusion	Elevated ferritin, elevated LDH
Elin Hoffmann Dahl <i>et al.</i> [30]	NP-PCR: +ve	Sinus tachycardia, flattened T waves	Decreased LV function 40%	TnT 1959 ng/L, NT-pro BNP 11,169 ng/L	-CMRI: diffuse myocardial edema, suggesting acute myocardial injury -Ct angiogram: no coronary artery stenosis	CRP 334 mg/L, procalcitonin 12.9 microgram/L
Guillaume Gauchotte <i>et al.</i> [31]	NP-PCR: -ve	No signs of ischemia	Severe diffuse LV hypokinesia, LVEF 20%, pericardial effusion around the right cardiac chamber, no tamponade, cardiac dysfunction	Normal BNP, hs-TnI normal	-Coronary angiogram: no significant lesions -Myocardial autopsy: multifocal inflammatory infiltration, dystrophic cardiomyocytes without necrosis, immunohistochemical assay for COVID-19 positive, PCR for COVID-19 positive	CRP 329 mg/L, lactate 6 mmol/L
Andrea Baggiano <i>et al.</i> [32]	NP-PCR: -ve Serum COVID-19 IgG: +ve	No significant findings	Moderate LV dilatation, Mild septal hypertrophy, diffuse hypokinesia, decreased LVEF 42%	Normal BNP, hs-TnI normal	CMRI: moderate LV dilatation, hypertrophy in mid-inferior septum, moderate decrease in LVEF 37%, findings suggesting acute/subacute myocarditis -EMB: focal areas of fibrosis, increased cardiac myocyte diameter with nuclear changes, lymphocyte aggregation and myocyte necrosis. Findings diagnosing chronic active myocarditis. +ve PCR for COVID-19	CRP normal

Table 2. Continued.

Case	COVID-19 test	Electrocardiogram	Echocardiogram	Cardiac biomarkers	Additional cardiac testing	Inflammatory markers
Moti Gulersen <i>et al.</i> [33]	PCR: +ve, Serology IgG: +ve	Sinus tachycardia without is- chemic changes	Severe global biventricular dys- function, trace pericardila effu- sion	Troponin T 146 ng/L, CK-MB 4 ng/mL, Pro BNP 1668 pg/mL	-CMRI: Not done during active disease period	CRP: 31.46 mg/dL, fib- rinogen 1225 ng/dL, IL- 6 8.3 pg/mL
Pierre Gravinay <i>et al.</i> [34]	NP PCR: -ve Serology: +ve IgG and IgM	Non specific T wave changes	No significant changes	Troponin I 2900 ng/mL, NT- proBNP 900 ng/pg/mL	-CT chest: no changes -CMRI: subepicardial edema on lateral, inferior LV wall, LV apical thrombus, no wall motion abnormalities, normal LVEF, LGE suggesting acute myocarditis	CRP 270 mg/L, fibrino- gen 10 g/L

IVS, interventricular septum; NT-BNP, n-terminal brain natriuretic peptide; NT-proBNP, N-terminal pro-B-type natriuretic peptide; CK, creatine kinase; CK-MB, creatine kinase myocardial band; hs-cTnI, high-sensitive troponin I; hs-cTnT, high-sensitive cardiac troponin T; LV, left ventricle; LVEF, left ventricular ejection fraction; LVSD, left ventricular systolic dysfunction; LVH, left ventricular hypertrophy; RV, right ventricle; RVSD, right ventricular systolic dysfunction; CMRI, cardiac magnetic resonance imaging; EMB, endomyocardial biopsy; LGE, late gadolinium enhancement; EDV, end diastolic volume; TR, tricuspid regurge; LDH, lactate dehydrogenase; RVEF, right ventricular ejection fraction; CXR, chest x-ray; LAD, left anterior descending artery; FoCUS, focused cardiac ultrasound.

Eight cases didn't include the ECG findings. ECG findings in 25 cases were variable with sinus tachycardia as the most frequent finding (28%), followed by T-wave inversion and diffuse or localized ST-segment elevation equally at 24%. Less frequent findings included diffuse or localized ST-segment depression, 3rd degree AV block, repolarization changes and no significant changes.

Thirty two out of 33 cases were tested for Troponin (including hs-cTnI, hs-cTnT, Troponin T and I) and it was elevated in 30 cases (93.7%) and the level was normal in two cases. Other cardiac markers like CK-MB, pro-BNP and myoglobin were tested less often.

Echocardiography was performed in 27 cases (81.8%). Five cases had no significant changes or normal findings in their echocardiography. The most frequent finding in the cases with significant changes was left ventricular systolic dysfunction (LVSD) occurring at 68.2%, followed by reduced ejection fraction at 50%, cardiac dyskinesia or hypokinesia and pericardial effusion equally at 36.4% each, and cardiac tamponade in 18.2% of cases.

Cardiac MRI (CMRI) was done for 14 cases (42.4%); findings included diffuse and regional late gadolinium enhancement suggesting myocarditis in 11 cases (87.6%), 2 cases had findings suggesting myocardial edema and one case had negative late gadolinium enhancement.

Endomyocardial biopsy (EMB) or autopsy was performed in 9 cases only (27.27%). 4 cases showed inflammation without necrosis, 2 case showed inflammation with necrosis, 2 cases with fibrosis and one cases didn't show inflammation nor necrosis. Two biopsies for 2 patients who had heart transplant did not show any signs of rejection of the transplanted hearts, but both EMBs showed fibrosis. EMB PCR testing for SARS-COV-2 RNA was performed on 7 cases; 5 biopsies tested positive for COVID-19 with negative NP PCR testing of corresponding patients, and two biopsies tested negative with positive results of the NP PCR testing of the patients. Follow-up EMB was done only for one case; biopsy PCR testing for SARS-COV-2 RNA came back negative after being positive 3 weeks earlier. Only one EMB was tested by immunohistochemical assay for COVID-19 and was positive.

To exclude obstructive coronary artery disease as a part of the workup, 7 cases (21%) underwent coronary angiography procedure and they all came back negative for acute obstructive coronary artery disease, and one case showed aneurysm of the proximal LAD coronary artery. All the details of the procedures and tests performed are demonstrated in Table 2 (Ref. [24–45]).

4. Discussion

Cardiovascular complications caused by COVID-19 infection include myocarditis, myocardial infarction, sepsis related cardiac injury, stress induced cardiomyopathy (takotsubo cardiomyopathy), and arrhythmia [7]. However,

the exact incidence of myocardial injury and myocarditis is unknown; the only insight we have is through the small number of published case reports. A single-center retrospective study at the Seventh Hospital of Wuhan City, China demonstrated that among 187 patients with COVID-19, 27.8% of patients showed myocardial injury. They found higher mortality rate in patients with elevated troponin T levels compared to patients with normal troponin T levels (59.6% to 8.9%) [10].

In the current study, the most common comorbidities in all cases were obesity and respiratory disease history (38%). Overall recovery rate was 72%. All the patients who died had developed either distributive/septic shock or cardiogenic shock.

There is no established framework for COVID-19 myocarditis diagnosis. However, we can divide the diagnostic approach into three categories:

(A) Cardiac biomarkers: Troponin was elevated in 30 cases out of the 32 tested cases in this study. However, troponin is elevated in critical and severe pneumonia including severely ill COVID-19 patients owing to supply-demand imbalance myocardial injury. Thus, troponin can't be used as a diagnostic tool by itself, instead it can be used as a prognostic tool because higher levels are associated with mortality [55]. On the other hand, Natriuretic peptides are not sensitive nor specific in diagnosing myocarditis [56].

(B) Electrocardiogram and echocardiography: ECG findings were variable with sinus tachycardia as the most common finding, followed by ST segment elevation similar to common documented findings of ECG in myocarditis [57]. Because of the high variability of ECG findings in myocarditis, its diagnostic value is low and it is considered nonspecific [58,59]. Some cases can also have normal ECG findings with myocarditis [20]. Echocardiography can evaluate functional and structural abnormalities of the heart like pericardial effusion, systolic function and wall motion abnormalities [56,59,60], but like ECG, there is no specific findings, and myocarditis patients can present with normal echocardiography [58,59,61]. On the other hand, echocardiography could exclude other cardiac diseases in the workout of myocarditis diagnosis [17]. The prevalent echocardiographic finding was LVSD followed by reduced ejection fraction and then pericardial effusion and cardiac dyskinesia or hypokinesia with equal occurrence.

(C) Advanced cardiac procedures:

1-Cardiac magnetic resonance imaging (CMRI):

This is considered the gold standard diagnostic tool for myocarditis with high diagnostic accuracy (78%) [59,60]. Myocardial damage is diagnosed based on Lake Louis criteria that includes positive LGE (necrosis and fibrosis), regional cardiac edema on T2-weighted and early gadolinium enhancement denoting hyperemia and early capillary leakage. Presence of 2 out of 3 CMR findings raises the specificity of CMRI [59]. In the current study, CMR findings

in patients with COVID included diffuse and regional late gadolinium enhancement, myocardial edema manifested by myocardial wall thickening and high SI in T2 WI, high values in T1 mapping and high values of extracellular fluid. Only 42% of cases had CMRI, owing to difficult application of COVID-19 spread preventive measures [38]. Nonetheless, there is an increase of CMRI use as compared to a review done on COVID-19 related myocarditis case reports that were published in the first half of 2020 due to higher value in diagnosing myocarditis (43%) [17].

2-Endomyocardial biopsy (EMB): This is the most superior test for myocarditis [62]. Patients included in this study had biopsies to explore the viral panel that causes myocarditis, RNA material of SARS-CoV-2, or signs of inflammation and/or necrosis. Only 9 patients in our study had EMBs tested. EMBs is used cautiously because of the possible complications that range from hematoma, DVT, and AV fistulas to perforation, heart block, pulmonary embolization, cardiac tamponade and several more [63,64]. The incidence of such complications is directly related to the patient's clinical condition and the cardiologist's expertise [65]. Two cases came back negative for EMB PCR test for SARS-CoV-2 with a positive respiratory COVID-19 PCR test, and assuming the test results for the EMBs are not false negative, this confirms the theories of myocardial injury that don't include direct viral injury to cardiomyocytes. Five cases tested positive for EMBs SARS-CoV-2 PCR testing, while the nasopharyngeal PCR COVID-19 testing for the 3 cases was negative.

3-Coronary angiography: this is performed to exclude obstructive coronary artery disease. Patients presenting with myocarditis symptoms share a scope of symptoms and signs with patients with stress induced cardiomyopathy (COVID-19 can also cause this type of cardiac disease) [66–68] and acute myocardial infarction, thus differentiating workup, including cardiac biomarkers, coronary angiography and CMRI, is critical to treat patients [13].

5. Conclusions

The exact molecular mechanisms and diagnostic approach of COVID-19 myocarditis remain unclear, and thus the management has not been well established yet. One of the hurdles researchers need to overcome is the few number of human EMBs obtained for testing. The results of the EMBs PCR testing in our study raise a question about how long after recovering and/or recovered patients are SARS-CoV-2 PCR test negative we should still consider them susceptible to COVID-19 myocarditis. The answer to that question will help in framing a proper diagnostic and cost-effective approach to patients presenting with cardiac symptoms after COVID-19 infection. Another area to explore is occurrence of similar outcomes, complete recovery, in a patient with severe necrosis in his EMBs study [49] compared to patients without necrosis [39]. even with the increasing use of CMRI and EMBs in diagnosing COVID-

19 myocarditis, another concern is the inaccessibility of CMRI and EMBs to some patients, so another feasible diagnostic approach should be well illustrated. As The published case reports of COVID-19 myocarditis in literature are scarce, our observations cannot be generalized, and further studies in the suggested points are encouraged.

Author contributions

Conceptualization—AAKAR, DF, AE, AS, AM, FT, ME-M, and AE-B; Project administration—AE-B; Supervision—FT, AE, ME-M, and AE-B; Writing - original draft—AAKAR, DF, AE, AS, AM, FT, ME-M, and AE-B; Writing - review & editing—AAKAR, DF, AE, AS, AM, FT, ME-M, and AE-B.

Ethics approval and consent to participate

Not applicable.

Funding

The Authors like to acknowledge the financial support of Science, Technology, and Innovation Funding Authority (STIFA) in Egypt (Grant # 43744) in this work.

Conflict of interest

The authors declare no conflict of interest.

References

- [1] Zhu N, Zhang D, Wang W, Li X, Yang B, Song J, *et al.* A Novel Coronavirus from Patients with Pneumonia in China, 2019. *New England Journal of Medicine*. 2020; 382: 727–733.
- [2] Wang D, Hu B, Hu C, Zhu F, Liu X, Zhang J, *et al.* Clinical Characteristics of 138 Hospitalized Patients With 2019 Novel Coronavirus-Infected Pneumonia in Wuhan, China. *Journal of the American Medical Association*. 2020; 323: 1061–1069.
- [3] World Health Organization. WHO Director-General's opening remarks at the media briefing on COVID-19 -11 March 2020. 2020. Available at: <https://www.who.int/director-general/speeches/detail/who-director-general-s-opening-remarks-at-the-media-briefing-on-covid-19---11-march-2020> (Accessed: 25 February 2021).
- [4] World Health Organization. Actualización Epidemiológica Semanal COVID-19. World Health Organization. 2021; 1–3.
- [5] Azer SA. COVID-19: pathophysiology, diagnosis, complications and investigational therapeutics. *New Microbes and New Infections*. 2020; 37: 100738.
- [6] Zeng J, Liu Y, Yuan J, Wang F, Wu W, Li J, *et al.* First case of COVID-19 complicated with fulminant myocarditis: a case report and insights. *Infection*. 2020; 48: 773–777.
- [7] Siripanthong B, Nazarian S, Muser D, Deo R, Santangeli P, Khanji MY, *et al.* Recognizing COVID-19-related myocarditis: the possible pathophysiology and proposed guideline for diagnosis and management. *Heart Rhythm*. 2020; 17: 1463–1471.
- [8] Al-Wahaibi K, Al-Wahshi Y, Mohamed Elfadil O. Myocardial Injury is Associated with Higher Morbidity and Mortality in Patients with 2019 Novel Coronavirus Disease (COVID-19). *SN Comprehensive Clinical Medicine*. 2020; 2: 2514–2520.
- [9] Boehmer TK, Kompaniyets L, Lavery AM, Hsu J, Ko JY, Yusuf H, *et al.* Association Between COVID-19 and Myocarditis Using Hospital-Based Administrative Data — United States,

March 2020–January 2021. Morbidity and Mortality Weekly Report. 2021; 70: 1228–1232.

- [10] Guo T, Fan Y, Chen M, Wu X, Zhang L, He T, *et al.* Cardiovascular Implications of Fatal Outcomes of Patients with Coronavirus Disease 2019 (COVID-19). *JAMA Cardiology*. 2020; 5: 811.
- [11] Goulter AB, Goddard MJ, Allen JC, Clark KL. ACE2 gene expression is up-regulated in the human failing heart. *BMC Medicine*. 2004; 2: 19.
- [12] Fraser E. Long term respiratory complications of covid-19. *British Medical Journal*. 2020; 370: m3001.
- [13] Qian Z, Travanty EA, Oko L, Edeen K, Berglund A, Wang J, *et al.* Innate Immune Response of Human Alveolar Type II Cells Infected with Severe Acute Respiratory Syndrome–Coronavirus. *American Journal of Respiratory Cell and Molecular Biology*. 2013; 48: 742–748.
- [14] Li W, Moore MJ, Vasilieva N, Sui J, Wong SK, Berne MA, *et al.* Angiotensin-converting enzyme 2 is a functional receptor for the SARS coronavirus. *Nature*. 2003; 426: 450–454.
- [15] Wong MCS, Wong S, Huang J, Yan B. Relating angiotensin-converting enzyme inhibitors or angiotensin receptor blockers with incidence or mortality of COVID-19. *ESC Heart Failure*. 2020; 7: 3119–3123.
- [16] Icenogle T. COVID-19: Infection or Autoimmunity. *Frontiers in Immunology*. 2020.
- [17] Sawalha K, Abozenah M, Kadado AJ, Battisha A, Al-Akchar M, Salerno C, *et al.* Systematic Review of COVID-19 Related Myocarditis: Insights on Management and Outcome. *Cardiovascular Revascularization Medicine*. 2021; 23: 107–113.
- [18] Zhao L, Fu Z. Roles of Host Immunity in Viral Myocarditis and Dilated Cardiomyopathy. *Journal of Immunology Research*. 2018; 2018: 1–12.
- [19] Schulze K, Becker BF, Schultheiss HP. Antibodies to the ADP/ATP carrier, an autoantigen in myocarditis and dilated cardiomyopathy, penetrate into myocardial cells and disturb energy metabolism in vivo. *Circulation Research*. 1989; 64: 179–192.
- [20] Caforio ALP, Angelini A, Blank M, Shani A, Kivity S, Goddard G, *et al.* Passive transfer of affinity-purified anti-heart autoantibodies (AHA) from sera of patients with myocarditis induces experimental myocarditis in mice. *International Journal of Cardiology*. 2015; 179: 166–177.
- [21] Maisch B, Ristić AD, Hufnagel G, Pankuweit S. Pathophysiology of viral myocarditis. *Cardiovascular Pathology*. 2002; 11: 112–122.
- [22] Neu N, Craig SW, Rose NR, Alvarez F, Beisel KW. Coxsackievirus induced myocarditis in mice: Cardiac myosin autoantibodies do not cross-react with the virus. *Clinical & Experimental Immunology*. 1987; 69: 566–574.
- [23] Alvarez FL, Neu N, Rose NR, Craig SW, Beisel KW. Heart-specific autoantibodies induced by Coxsackievirus B3: Identification of heart autoantigens. *Clinical Immunology and Immunopathology*. 1987; 43: 129–139.
- [24] Hodson DZ, Reinhardt SW, Moore CL. Young Man With Shortness of Breath. *Annals of Emergency Medicine*. 2021; 77: 500–558.
- [25] Tung-Chen Y, Algora-Martín A, Rodríguez-Roca S, Díaz de Santiago A. COVID-19 multisystemic inflammatory syndrome in adults: a not to be missed diagnosis. *BMJ Case Reports*. 2021; 14: e241696.
- [26] Sheikh AB, Javed N, Sheikh AAE, Upadhyay S, Shekhar R. Diabetes Insipidus and Concomitant Myocarditis: A Late Sequelae of COVID-19 Infection. *Journal of Investigative Medicine High Impact Case Reports*. 2021; 9: 2324709621999954.
- [27] Volis I, Livneh I, Hussein K, Raz-Pasteur A. COVID-19-Associated Suspected Myocarditis as the Etiology for Recurrent and Protracted Fever in an Otherwise Healthy Adult. *The American Journal of the Medical Sciences*. 2021; 361: 522–525.
- [28] Hatipoglu S, Lyon AR, Pennell DJ. CMR unveiling the cause of post CoVid-19 infection chest pain. *Int J Cardiovasc Imaging*. 2021; 37: 2025–2026.
- [29] Cairns L, Abed El Khaleq Y, Storrar W, Scheuermann-Freestone M. COVID-19 myopericarditis with cardiac tamponade in the absence of respiratory symptoms: a case report. *Journal of Medical Case Reports*. 2021; 15: 31.
- [30] Dahl EH, Mosevoll KA, Cramariuc D, Vedeler CA, Blomberg B. COVID-19 myocarditis and postinfection Bell’s palsy. *BMJ Case Reports*. 2021; 14: e240095.
- [31] Gauchotte G, Venard V, Segondy M, Cadoz C, Esposito-Fava A, Barraud D, *et al.* SARS-Cov-2 fulminant myocarditis: an autopsy and histopathological case study. *International Journal of Legal Medicine*. 2021; 135: 577–581.
- [32] Baggiano A, Rizzo S, Basso C, Pontone G. A patient with rapid worsening dyspnoea during Covid-19 pandemic. *European Heart Journal*. 2021; 42: 717–718.
- [33] Gulersen M, Staszewski C, Grayver E, Tam Tam H, Gottesman E, Isseroff D, *et al.* Coronavirus Disease 2019 (COVID-19)-Related Multisystem Inflammatory Syndrome in a Pregnant Woman. *Obstetrics & Gynecology* 2021; 137: 418–422.
- [34] Gravinay P, Issa N, Girard D, Camou F, Cochet H. CMR and serology to diagnose COVID-19 infection with primary cardiac involvement. *European Heart Journal: Cardiovascular Imaging*. 2021; 22: 133.
- [35] Paul J, Charles P, Richaud C, Caussin C, Diakov C. Myocarditis revealing COVID-19 infection in a young patient. *European Heart Journal -Cardiovascular Imaging*. 2020; 21: 776–776.
- [36] Radbel J, Narayanan N, Bhatt PJ. Use of Tocilizumab for COVID-19-Induced Cytokine Release Syndrome. *Chest*. 2020; 158: e15–e19.
- [37] Purohit R, Kanwal A, Pandit A, Patel BM, Meininger GR, Brown JJ, *et al.* Acute myopericarditis with pericardial effusion and cardiac tamponade in a patient with COVID-19. *American Journal of Case Reports*. 2020; 21: 1–4.
- [38] Cizgici AY, Zencirkiran Agus H, Yildiz M. COVID-19 myopericarditis: it should be kept in mind in today’s conditions. *The American Journal of Emergency Medicine*. 2020; 38: 1547.e5–1547.e6.
- [39] Wenzel P, Kopp S, Göbel S, Jansen T, Geyer M, Hahn F, *et al.* Evidence of SARS-CoV-2 mRNA in endomyocardial biopsies of patients with clinically suspected myocarditis tested negative for COVID-19 in nasopharyngeal swab. *Cardiovascular Research*. 2020; 116: 1661–1663.
- [40] Beşler MS, Arslan H. Acute myocarditis associated with COVID-19 infection. *The American Journal of Emergency Medicine*. 2020; 38: 2489.e1–2489.e2.
- [41] Pérez-Acosta G, Santana-Cabrera L, Blanco-López J, Martín-González JC. COVID-19 myopericarditis: A case report. *Revista Clínica Española*. 2021; 221: 312–313.
- [42] Rasras H, Boudihi A, Hbali A, Ismaili N, Ouafi NE. Multiple cardiovascular complications of COVID-19 infection in a young patient: a case report. *The Pan African Medical Journal*. 2021; 38: 192.
- [43] Berg N, Ilonze O, Bajpai V, Guglin M, Rao R. Acute Biventricular Heart Failure After COVID-19 Infection in an Orthotopic Heart Transplant Patient: A Case Report. *Transplantation Proceedings*. 2021; 53: 1224–1226.
- [44] Roest S, Brugts JJ, van Kampen JJA, von der Thüsen JH, Constantinescu AA, Caliskan K, *et al.* COVID-19-related myocarditis post-heart transplantation. *International Journal of Infectious Diseases*. 2021; 107: 34–36.
- [45] Khatri A, Wallach F. Coronavirus disease 2019 (Covid-19) presenting as purulent fulminant myopericarditis and cardiac tamponade: a case report and literature review. *Heart & Lung*. 2020;

49: 858–863.

- [46] Dalen H, Holte E, Guldal AU, Hegvik J, Stensaeth KH, Braaten AT, *et al.* Acute perimyocarditis with cardiac tamponade in COVID-19 infection without respiratory disease. *BMJ Case Reports.* 2020; 13: e236218.
- [47] Caballeros Lam M, de la Fuente Villena A, Hernández Hernández A, García de Yébenes M, Bastarrika Alemañ G. Cardiac magnetic resonance characterization of COVID-19 myocarditis. *Revista Española De Cardiología.* 2020; 73: 863–864.
- [48] Naneishvili T, Khalil A, O’Leary R, Prasad N. Fulminant myocarditis as an early presentation of SARS-CoV-2. *BMJ Case Reports.* 2020; 13: e237553.
- [49] Othenin-Girard A, Regamey J, Lamoth F, Horisberger A, Glampedakis E, Epiney JB, *et al.* Multisystem inflammatory syndrome with refractory cardiogenic shock due to acute myocarditis and mononeuritis multiplex after SARS-CoV-2 infection in an adult. *Swiss Medical Weekly.* 2020; 150: w20387.
- [50] Ruiz-Rodríguez JC, Chiscano-Camón L, Ruiz D, Sacanell J, Argudo E, Nuvials FX, *et al.* Cardiac tamponade as a cause of cardiac arrest in severe COVID-19 pneumonia. *Resuscitation.* 2020; 155: 1–2.
- [51] Salamanca J, Díez-Villanueva P, Martínez P, Cecconi A, González de Marcos B, Reyes G, *et al.* COVID-19 “Fulminant Myocarditis” Successfully Treated with Temporary Mechanical Circulatory Support. *JACC: Cardiovascular Imaging.* 2020; 13: 2457–2459.
- [52] Spano G, Fischer K, Maillat C, Vicario G, Huber AT, Gräni C. Delayed isolated peri-myocarditis in a Covid-19 patient with respiratory symptoms but without lung involvement. *The International Journal of Cardiovascular Imaging.* 2020; 36: 2279–2280.
- [53] Pietsch H, Escher F, Aleshcheva G, Baumeier C, Morawietz L, Elsaesser A, *et al.* Proof of SARS-CoV-2 genomes in endomyocardial biopsy with latency after acute infection. *International Journal of Infectious Diseases.* 2021; 102: 70–72.
- [54] Recalcati S, Piconi S, Franzetti M, Barbagallo T, Prestinari F, Fantini F. Colchicin treatment of COVID-19 presenting with cutaneous rash and myopericarditis. *Dermatologic Therapy.* 2020; 33: e13891.
- [55] Tersalvi G, Vicenzi M, Calabretta D, Biasco L, Pedrazzini G, Winterton D. Elevated Troponin in Patients with Coronavirus Disease 2019: Possible Mechanisms. *Journal of Cardiac Failure.* 2020; 26: 470–475.
- [56] Caforio ALP, Pankuweit S, Arbustini E, Basso C, Gimeno-Blanes J, Felix SB, *et al.* Current state of knowledge on aetiology, diagnosis, management, and therapy of myocarditis: a position statement of the European Society of Cardiology Working Group on Myocardial and Pericardial Diseases. *European Heart Journal.* 2013; 34: 2636–2648.
- [57] Nieminen MS, Heikkilä J, Karjalainen J. Echocardiography in acute infectious myocarditis: Relation to clinical and electrocardiographic findings. *The American Journal of Cardiology.* 1984; 53: 1331–1337.
- [58] Gutberlet M, Thiele H. Comment on: Jeserich M, Konstantinides S, Pavlik G, Bode C, Geibel A (2009) Non-invasive imaging in the diagnosis of acute viral myocarditis. *Clin Res Cardiol* 98:753–763. *Clinical Research in Cardiology.* 2010; 99: 261–263.
- [59] Friedrich MG, Sechtem U, Schulz-Menger J, Holmvang G, Alakija P, Cooper LT, *et al.* Cardiovascular Magnetic Resonance in Myocarditis: a JACC White Paper. *Journal of the American College of Cardiology.* 2009; 53: 1475–1487.
- [60] Abdel-Aty H, Boyé P, Zagrosek A, Wassmuth R, Kumar A, Messroghli D, *et al.* Diagnostic Performance of Cardiovascular Magnetic Resonance in Patients with Suspected Acute Myocarditis. *Journal of the American College of Cardiology.* 2005; 45: 1815–1822.
- [61] Cau R, Bassareo PP, Mannelli L, Suri JS, Saba L. Imaging in COVID-19-related myocardial injury. *the International Journal of Cardiovascular Imaging.* 2020; 37: 1349–1360.
- [62] Richardson P, McKenna RW, Bristow M, Maisch B, Mautner B, O’Connell J, *et al.* Report of the 1995 World Health Organization/International Society and Federation of Cardiology Task Force on the definition and classification of cardiomyopathies. *Circulation.* 1996; 93: 841–842.
- [63] Bussani R, Silvestri F, Perkan A, Gentile P, Sinagra G. Endomyocardial Biopsy. Dilated Cardiomyopathy. 2019; 3: 135–147.
- [64] Francis R, Lewis C. Myocardial biopsy: techniques and indications. *Heart.* 2018; 104: 950–958.
- [65] Ahmed T, Goyal A. Endomyocardial Biopsy. *StatPearls: Florida, USA.* 2021.
- [66] Duployez C, Le Guern R, Tinez C, Lejeune A, Robriquet L, Six S, *et al.* Panton-Valentine Leukocidin–Secreting *Staphylococcus aureus* Pneumonia Complicating COVID-19. *Emerging Infectious Diseases.* 2020; 26: 1939–1941.
- [67] Kluge S, Janssens U, Welte T, Weber-Carstens S, Marx G, Karagiannis C. German recommendations for critically ill patients with COVID-19. *Medizinische Klinik -Intensivmedizin Und Notfallmedizin.* 2020; 115: 111–114.
- [68] Pirzada A, Mokhtar AT, Moeller AD. COVID-19 and Myocarditis: what do we Know so Far? *CJC Open.* 2020; 2: 278–285.