

Real-time contrast-enhanced specific ultrasound in staging and follow-up of splenic lymphomas

Salvatore Tafuto ¹, Orlando Catalano ², Gianvincenzo Barba ³, Fabio Sandomenico ², Roberto Lobianco ⁴, Anna Tortoriello ¹, Roberta Formato ¹, Pasquale Comella ⁵, Alfredo Siani ², Marilisa Di Meo ⁴, Rosario Vincenzo Iaffaioli ⁵ and Stefano Quattrin ¹

¹ Department of Medical Oncology, S. Maria delle Grazie Hospital Pozzuoli, Italy; ² Department of Radiology, National Cancer Institute, Naples, Italy; ³ Epidemiology and Population Genetics, Institute of Food Science, Avellino, Italy; ⁴ Department of Radiology, S. Maria delle Grazie Hospital Pozzuoli, Italy; ⁵ Department of Medical Oncology, National Cancer Institute, Naples, Italy

TABLE OF CONTENTS

1. Abstract
2. Introduction
3. Materials and methods
4. Results
5. Discussion
6. References

1. ABSTRACT

From January 2003 to April 2005 we studied 25 lymphoma patients (10 with HD, 4 with low-grade NHL, 6 with high-grade NHL and 5 with chronic lymphatic leukaemia; 14 men, 11 women, age range 28-79 years). After a baseline US study we rapidly injected 4.8 mL of the second-generation microbubble contrast agent SonoVue (Bracco, Italy). Contrast enhanced studies were carried out with the contrast-specific software named Contrast Tuned Imaging (Esaote, Italy) using a continuous, harmonic acquisition and a low acoustic pressure. The CS-US findings were correlated with results of standard tools, including CT, MRI, US follow up. CS-US revealed correctly 47 out of the 52 lesions identified by CT scan, in the absence of false positive findings (sensitivity=90%; Specificity=100%, in comparison to CT scan). Complete concordance in evaluating the lesion extension of the CS-US in respect to CT was 88%, while underestimate occurred in 9% and overestimate in 3% of cases. On the contrary, basic sonography defined correctly the dimensional alteration in 52% of the cases, underestimated in 35% and overestimated in 13%, thus showing significantly lower accuracy (chi-square = 30.0, p<0.001). In our experience, CS-US was superior to conventional sonography even from a qualitative point of view.

2. INTRODUCTION

Lymphomas are the most frequent neoplastic pathologies of the spleen. Spleen involvement occurs in up to 30% of patients with Hodgkin's lymphoma (HD) and in up to 40% of those with non-Hodgkin's lymphoma (NHL). Nearly 30% of patients show splenic involvement without splenomegaly while, oppositely, more than 30% of patients with lymphoma and splenomegaly present a congestive and reactive expression of the organ without focal involvement. The criteria for clinical staging of the spleen, proposed for either HD and NHL patients, include occurrence of clinical evidence of splenomegaly or, in its absence, of instrumental (ultrasound - US, computerised tomography - CT, magnetic resonance imaging - MRI) detection of the enlarged organ or the presence of multiple focal - neither cystic nor vascular - defects within the spleen. However, the radiological evaluation of these conditions, especially when appearing with diffuse infiltration, is difficult. The increasing use of US seemed to be promising but the sonographic aspects have not been sufficiently standardised and diagnostic criteria of proven value are not yet available (1-4).

Current US techniques show, therefore, low sensitivity and specificity, in particular as it regards the correct identification between focal and diffuse, benign or

malignant lesions (5,6,7). CT and MRI also present a low sensitivity in identifying infiltrating lesions, where nodules of discrete size or large neoplastic masses are normally of easy recognition. In any case, CT and MRI scans are not specific for the diagnosis of lymphoma, being often indistinguishable from those of other neoplastic diseases (8). The different imaging modalities (US, CT, MRI) have thus a similar low sensitivity in recognising HD- and NHL-related focal involvement of the spleen, especially in the presence of very small lesions (i.e. <1 cm).

Sensitivity of US does not exceed 35-50% whereas digitalised methods, MRI included, is slightly above 60-75%. As a consequence, the clinical problems linked to splenic or to subdiaphragmatic involvement, on the whole, represent a crucial point in staging, in therapeutic strategy planning and in prognosis evaluation of these patients. The absence of unanimous agreement on the diagnostic strategy for lymphomatous splenic localisation, sometime forces the clinician to adopt more invasive diagnostic procedures (9,10,11).

Contrast-specific ultrasonography (CS-US) is a recently developed imaging technique which appears to be more informative than conventional US. CS-US allows evaluating in real-time all the phases of contrast medium distribution within an organ, from assumption to dismissal, thus permitting to obtain signals from large vessels as well as from microcirculation (12). This scarcely-invasive diagnostic procedure could be useful in reducing the need for clinicians of CT and MRI studies, or other more invasive tests such as imaging-guided percutaneous needle aspiration, biopsy or laparoscopic biopsies, and to avoid the risk to overestimate or, more importantly, to underestimate the spleen involvement in HD and NHL patients during the staging phase of the disease (13).

3. AIM

The purpose of this study was to evaluate the sensitivity and efficacy of contrast-specific sonography in respect to standard methods, such as conventional abdominal US and CT in both the diagnosis of spleen involvement, focal or diffuse, and the follow-up of HD or NHL patients.

4. METHODS

From January 2003 to April 2005, 25 patients affected by lymphomatous disease (10 with HD, 4 with low-grade NHL, 6 with high-grade NHL and 5 with chronic lymphatic leukaemia; 14 men, 11 women, age range 28-79 years) underwent spleen CS-US. The patients referred directly to our Institution or from other centres after a diagnosis of HD or NHL with suspected diffuse or focal spleen involvement by CT. For the US contrast-specific study in real time, a last generation contrast medium, SonoVue™ (Bracco, Italy), composed of gaseous microbubbles of sulphur hexafluoride and stabilised by an elastic surfactant shell, was utilised. A phospholipidic membrane that increases the superficial tension and slows down the dissolution process constitutes the shell. The so

called second-generation contrast media show greater elasticity and resistance to acoustic pressure with related better harmonic response at low mechanical index than the first-generation media, all factors that allow for their use during real-time US imaging. With the exception of unstable angina and recent myocardial infarction, the use of SonoVue™ is absolutely safe according to the Committee for Human Medical Product. The contrast-enhanced studies were executed with the scanner EsaTune (Esaote, Italy), characterised by a contrast specific module in continuous acquisition (Contrast Tuned Imaging, CnTI®) (14,15).

The lyophilised component of the contrast medium was equal to 4.8 ml injected in a single dose. Immediately after the injection, we proceeded with the exploration of the left hypochondriac region for 3-5 minutes, until progressive extinction of the enhancement was noted. Images were stored as videos for blind retrospective evaluation. Before CS-US, the patients underwent baseline splenic sonography and contrast-enhanced helical CT of the abdomen.

For each patient, retrospective evaluation of the study was carried out by two observers not directly involved in the image acquisition; additionally, comparative analysis of the lesions was performed for the following parameters: number, site, and size of the lesions, marginal visibility, CT and US appearance.

Sensitivity (i.e. the probability to actually have a lesion in the presence of a positive finding) and specificity (i.e. the probability to have no lesions in the presence of a negative finding) of CS-US were calculated according to standard formulae with reference to CT scan.

The dimensional extension of the parenchyma lesions was defined as inappropriate, underestimated, or overestimated in respect to CT parameters, whereas the conspicuity of the lesions was defined as grade 1, 2, or 3 on the basis of the contrast gradient between the lesion and the healthy parenchyma.

Finally, 10 out of the 25 patients underwent CS-US after polychemotherapy to prospectively follow-up the clinical course of the disease at variable times (6-48 months).

Frequencies were compared by chi-square statistics analysis and $P < 0.05$ was accepted as statistically significant.

5. RESULTS

Twenty-five patients participated in the study: 10 patients were diagnosed as HD, 10 as non-Hodgkin lymphoma (4 low grade and 6 high grade), and 5 as chronic lymphatic leukaemia (Table 1). In 9 patients with splenomegaly and suspected diffuse spleen involvement, even though complete doses of contrast medium (4,8 mL) were utilised, we did not find suggestive aspects of neoplastic involvement in the organ. The brief and low

Splenic lymphomas and contrast-enhanced ultrasound

Table 1. Patient characteristics

Age (years) (Median and range)	59 (28-79)
Sex ratio (M:F)	14/11
Hodgkin disease	
- <i>Nodular sclerosis</i>	6
- <i>Lymphocyte predominant</i>	2
- <i>Mixed cellularity</i>	2
Non-Hodgkin Lymphoma	
- <i>indolent</i>	4
- <i>aggressive</i>	6
Chronic Lymphocytic Leukaemia	5

Table 2. Radiological aspects of splenic involvement

Splenic involvement	N
• Diffuse (Suspected)	9
• Focal micronodular	4
• Focal macronodular	10
• Mass like	2

Table 3. Concordance about the size of the lesions of the CS-US and US in respect to CT

Concordance	CS-US (on a total of 47 lesions)	US (on a total of 35 lesions)
Absolute	88%	52%
Underestimate	9%	35%
Overestimate	3%	13%

intensity opaqueness obtained in the US contrast enhancement, did not permit distinction, in our case study, of a congestive splenomegaly due to lymphomatous infiltration. As it regards focal splenic involvement, the CT study showed altogether 52 lesions in the remaining 16 patients. CS-US revealed correctly 47 out of the 52 lesions identified by CT scan, in the absence of false positive findings (sensitivity=90%; Specificity=100%, in comparison to CT scan). The lymphomatous lesions appeared constantly as hypovascular hypoechoic areas, primarily micronodular in 4 cases, macronodular in 10 cases and mass-like in 2 cases (table 2); an almost regular morphology, with the presence of peripheral, perilesional and intralesional vessels in the arterial phase and defined echogenicity of microcirculation in the intermediate and late phases. Two small angioma capillaries, incidentally visualised in conventional study, resulted isoechoic in the spleen parenchyma in all the phases of contrast enhancement and therefore not recognisable. Absolute concordance in estimating the lesion extension of the CS-US in respect to CT was 88%, while underestimate occurred in 9% and overestimate in 3% of cases. On the contrary, basic sonography defined correctly the dimensional alteration in 52% of the cases, underestimated in 35% and overestimated in 13%, thus showing significantly lower accuracy (chi-square = 30.0, $p < 0.001$) (Table 3). Using CS-US, a grade 1 (low) conspicuity of the lesions in respect to the surrounding parenchyma was observed only in 11% of the identified cases, in comparison to the 42% of cases of grade 1

conspicuity assessed by conventional US (chi-square=24.7, $p < 0.001$) (Table 4).

Ten patients were re-evaluated, with both contrast specific US and conventional procedures, after chemotherapy: 3 patients resulted in stable disease, and 4 patients showed complete remission of the focal spleen lesion with any of the technique (US, CS-US or CT scan) adopted. In 3 patients, in whom treatment failed to induce the remission of spleen lesions, CS-US documented an increment of lesion hypoechogenicity (becoming near anechoic) and a loss of the intralesional microcirculation.

6. DISCUSSION

Although spleen involvement is a relatively frequent event occurring in 30% of HD patients and in 40% of NHL patients, the possibility of diagnosing splenic involvement, either focal or diffuse, through imaging is actually quite low.

The sensitivity of US is between 35-50%, while that of MRI and CT, more invasive and expensive, is roughly 60-65%; moreover, these techniques do not allow to distinguish between focal or diffuse lesions, and between benign or malignant. Sensitivity further decreases in the presence of infiltrates with micronodular aspect, especially for lesion size < 1 cm. Consequently, the choice of invasive procedures, such as needle aspiration, CT/US guided biopsy and laparoscopic biopsy, becomes mandatory in selected cases to define with certainty the nature of splenomegaly or of parenchymal focal lesions. For a long time, due to the lack of diagnostic possibilities, a prophylactic splenectomy was the preferred therapeutic approach for I and IIA stages of HD and even more in patients with HD; the abandonment of "blind" splenectomy by many oncologists did not depend on the improved accuracy in imaging techniques but on the need of avoiding surgical complications and on the efficacy at any stage of systemic chemotherapy.

For these reasons, non-invasive and low cost diagnostic procedures efficiently revealing spleen lymphomatous lesions and offering unequivocal data regarding the response to the treatment are requested to be developed (16,17,18).

In light of these considerations we recently tested a new technique of CS-US imaging in a group of HD and NHL patients with focal or diffuse spleen involvement revealed by CT. In the present study, CS-US succeeded in detecting splenic involvement in HD and NHL patients showed as accurately as CT scan.

The CS-US imaging allows to evaluate in real time the phases of distribution of the contrast media within the organ from assumption to dismissal, and obtains signals from both large vessels and microcirculation.

Table 4. Concordance of the conspicuity of the lesions of the CS-US and US in respect to CT (in a total of 47 lesions)

Procedures	Conspicuity		
	1 (low)	2 (median)	3 (high)
CS-US (on a total of 47 lesions)	11%	62%	27%
US (on a total of 35 lesions)	42%	39%	19%

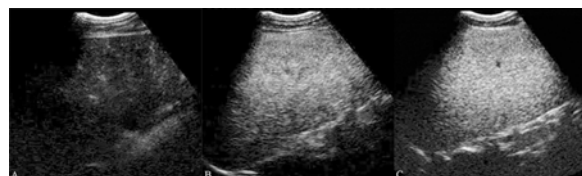

Figure 1. Diffuse splenic involvement (CS-US images taken at 16s, 32s and 54s from injection). Parenchymal enhancement is slightly inhomogeneous but dense and persistent.

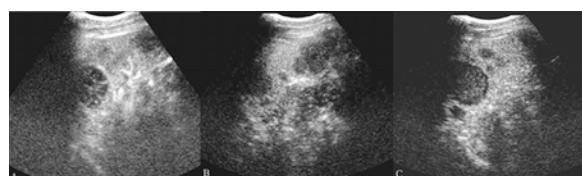


Figure 2. Mixed macro- and micronodular splenic involvement (CS-US images taken at 13s, 205s, e 242s from injection). Multiple, small and large, hypo echoic lesions are evident. Note the peri- and intralesional arteries on the first scan.

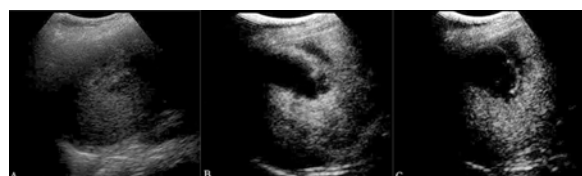

Figure 3. Single, mass-like lesion (conventional US image plus CS-US images taken at 18s and 49s from injection). Note the greater conspicuity of the enhancing intralesional septa.

The spleen is an excellent target for CS-US, being a superficial, relatively small, homogeneous, and well-vascularized organ. In normal conditions, the opaqueness of the spleen artery begins 10 seconds after injection of gaseous microbubbles of sulphur hexafluoride - SonoVue™. Up to 30-40 seconds after injection of the contrast, the spleen parenchyma reveals a rather heterogeneous contrast graphic impregnation. This aspect is due to the complex structure of the organ, with different velocity of flow within the red pulp, as already known from CT and MRI studies. Spleen parenchyma is thus poor in vascular signals, with the exception of the portions contiguous to the hilum where it is possible to accurately identify and follow the vessels. (19,20,21).

The involvement of lymphoma may be distinguished in diffuse (homogeneous splenomegaly)

(Figure 1), miliaric (when the largest lesion is <10 mm²), micronodular (when the largest lesion is < 30 mm²), macronodular (when the largest lesion is >30 mm²), mass like (lesion beyond the border of splenic contour), perisplenic infiltration (capsular or pericapsular enlargement) at hilar departure, and peri-ilar lymphadenopathy. While in low grade NHL and in HD diffuse or micronodular splenic lesions frequently occur, in high grade NHL macronodular forms are frequently observed besides micronodular forms.

With CS-US the lymphomatous lesions, as well as metastatic lesions from other tumours, appear hypoechoic in 97-100% of the cases and the larger the diameter of the lesion, the higher the probability of malignancy. Thus, the occurrence of hypoechoic lesions by CS-US is virtually diagnostic for splenic involvement in both patients with diagnosis of lymphoma and patients with a clinical history of primitive cancer, and, usually, does not require a bioptic confirmation. On the contrary, especially in HD, the diagnosis of splenomegaly does not correlate with the probability of cancer involvement and there may be marked splenomegaly in absence of an actual splenic localisation of the disease. In our study, in none of the patients was possible to distinguish congestive splenomegaly from diffuse lymphomatous infiltration by CS-US, because of the brief and rapid opaqueness (Figure 1). It is necessary, however, to emphasise the fact that, in these patients, also CT scan failed to identify specific aspects of neoplastic involvement of the organ. We believe that the diagnostic power and the efficiency of CS-US could be further improved in these situations possibly by testing the technique in larger samples and by developing last generation softwares for image-analysis.

In the 16 patients with focal splenic lesions and diagnosis of HD or NHL, CS-US has revealed 47 of the 52 lesions detected by CT scan, showing higher efficiency in comparison to conventional sonography (35/52). Therefore, in our experience, CS-US showed a higher sensitivity than conventional basic sonography. Moreover, in 88% of the cases there was concordance between CS-US and CT in estimating the extension of focal lesions and only in 9% and in 3% the lesion size was underestimated or overestimated, respectively. On the contrary, concordance between conventional sonography and CT scan occurred in only 52% of the cases; contrast sonography underestimates lesion size in 35% and overestimates in 13%. Micronodular lesions were manifested in 25% of the cases, macronodular lesion in 60%, and mass-like lesions in 15% (Figure 2,3). CS-US was superior to conventional sonography even from a qualitative point of view. In fact, in the spleen, conspicuity of the lesions respect to the surrounding parenchyma was 1 (low) in 11% of the cases identified, 2 (intermediate) in 62% of the cases identified and 3 (high) in 27% of CS-US studied patients. Instead, the study of the lesions in basic sonography offered in 42% of the cases identified a low conspicuity, in 39% an intermediate conspicuity, and only in 19% an high conspicuity.

The focal lesions resulted homogeneously hypoechoic and therefore hypovascular, with better definition in the intermediate and late phases

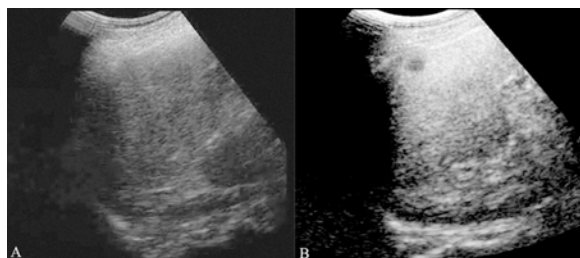


Figure 4. Splenic lesion inapparent on baseline sonography (conventional US image plus CEUS image taken at 57s from injection). A small subcapsular, hypoechoic nodule (arrow) becomes evident after contrast medium administration.

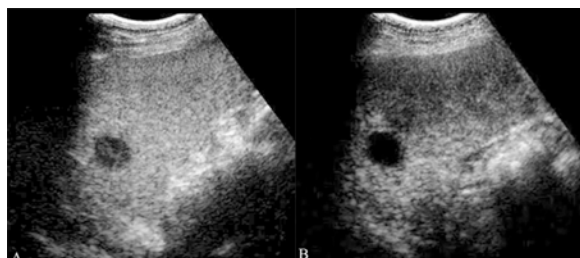


Figure 5. Follow imaging before and after chemotherapy, (pretreatment CEUS image taken at 129s from injection and post-treatment CEUS taken 141s from injection). The inactive lesion after chemotherapy (refractory, high grade, NHL patients treated with LOH-P x 6 courses) shows a marked and homogeneous hypoechogenicity without any contrast enhancement.

of parenchymal enhancement, rather than the early phase (Figure 4). In most cases, due to intralesional microcirculation, the lesions showed inhomogeneous aspects. This parameter then revealed to be very important. In fact, in the 10 patients subjected to instrumental re-evaluation after chemotherapy, 4 patients demonstrated complete remission at the splenic level with disappearance of the lesions registered by all diagnostic procedures (US, CEUS, CT) utilised. In 3 relapsed/refractory high grade NHL patient, treated with oxaliplatin at the dose of 130 mg/mq every 21 days, CEUS failed to detect the reduction of the size of the lesion but documented an increment of the hypoechogenicity and, above all, the loss of microcirculation, which are both considered response criteria (Figure 5). This finding was confirmed by positron emission tomography with 18F- fluorodeoxyglucose (FDG-PET) (performed exclusively in these 3 cases to formulate a therapeutic opinion) that did not demonstrated increased up-take of 18F-FDG in the involved sites.

In none of the participant patients hypersensitivity and/or adverse reactions were observed, confirming the safety in using this contrast medium.

In conclusion, the use of CEUS to diagnose focal splenic lymphomatous involvement is a low-cost, safe and efficacious method to obtain functional and morphological images. CEUS seems to be superior to conventional

sonography, in terms of diffusion, resolution of the lesions and estimate of lesion size. Besides, CEUS seems to be the only technique able to offer, before and after chemotherapy, the dynamic definition of macro- and microvascular perfusion of the splenic lesions. A procedure, therefore, useful in the diagnosis and staging of lymphoma, but in particular in the evaluation of the response to the treatment and the follow-up of the patient.

7. REFERENCES

1. Carde P, A Hagenbeek, M Hayat, M Monconduit, J Thomas, MJ Burgers, EM Noordijk, A Tanguy, JH Meerwaldt & R Le Fur: Clinical staging versus laparotomy and combined modality with MOPP versus ABVD in early-stage Hodgkin's disease: the H6 twin randomized trials from the European Organization for Research and Treatment of Cancer Lymphoma Cooperative Group. *J Clin Oncol* 11, 2258-2272 (1993)
2. Lister TA, D Crowther, SB Sutcliffe, E Glatstein, GP Canellos, RC Young, SA Rosenberg, CA Coltman & M Tubiana: Report of a committee convened to discuss the evaluation and staging of patients with Hodgkin's disease : Cotswolds meeting. *J Clin Oncol* 7, 1630-1636 (1989)
3. Munker R, A Stengel, A Stabler, E Hiller & G Brehm: Diagnostic accuracy of ultrasound and computed tomography in the staging of Hodgkin's disease. *Cancer* 76, 1460-1466 (1995)
4. Iaffaioli RV, A Sodano & S Tafuto: Studio pilota di Stadiazione dei Linfomi Maligni. *It Curr Radiol* VI, 159-165 (1987).
5. Hess CF, B Kurtz, W Hoffmann & M Bamberg: Ultrasound diagnosis of splenic lymphoma: analysis of multidimensional splenic indices. *Br J Radiol* 66, 859-864 (1993).
6. Soyer P, B Van Beers, F Teillet-Thiebaud, C Grandin, F Kazerouni, J Barge, J Pringot & M Levesque: Hodgkin's and non-Hodgkin's hepatic lymphoma: sonographic findings. *Abdom Imaging* 18, 339-343 (1993).
7. Cioni C, C Franchini & M Perri: Milza e linfonodi, in: Mazzocchi M (ed.) In: *Ecografia* (II edition). Eds: Idelson-Gnocchi, 649-679 (2002)
8. Rodriguez M: Computed tomography, magnetic resonance imaging and positron emission tomography in non-Hodgkin lymphoma. *Acta Radiol* 39 (Suppl):417 (1998)
9. Daskalogiannaki M, P Prassopoulos, G Katrinakis, I Tritou, G Eliopoulos & N Gourtsoyiannis: Splenic involvement in lymphomas: evaluation on serial CT examinations. *Acta Radiol* 42, 326-332 (2001)
10. Earl HM, SB Sutcliffe, IK Fry, AK Tucker, J Young, J Husband, PF Wrigley & JS Malpas : CT abdominal scanning in Hodgkin's disease. *Clin Radiol* 31, 149-153 (1980)

Splenic lymphomas and contrast-enhanced ultrasound

11. Rahmouni A, C Tempany, R Jones, R Mann, A Yang & E Zerhouni. Lymphoma: Monitoring tumor size and signal intensity with MR imaging. *Radiology* 188, 445-451 (1993)
12. Bokor D, JB Chambers, PJ Rees, TG Mant, F Luzzani & A Spinazzi: Clinical safety of SonoVue, a new contrast agent for ultrasound imaging, in healthy volunteers and in patients with chronic obstructive pulmonary disease. *Invest Radiol* 36, 104-9 (2001)
13. Cavanna L, G Civardi, F Fornari, M Di Stasi, G Sbolli, E Buscarini, D Valliva, S Rossi, P Tansini & L Buscarini: Ultrasonically guided percutaneous splenic tissue core biopsy in patients with malignant lymphomas. *Cancer* 69, 2932-2936 (1992)
14. Forsberg F, BB Goldberg, JB Liu, DA Merton, NM Rawool & WT Shi: Tissue-specific US contrast agent for evaluation of hepatic and splenic parenchyma. *Radiology* 210, 125-132 (1999)
15. Bauer A, L Solbiati & N Wessman: Ultrasound imaging with SonoVue: low mechanical index real-time imaging. *Acad Radiol* 9 (suppl.), 282-284 (2002)
16. Goerg C, WB Schwerk & K Goerg: Sonography of focal lesions of the spleen. *Am J Radiol* 156, 949-953 (1991)
17. Goerg C, WB Schwerk, K Goerg & K Havemann: Sonographic patterns of the affected spleen in malignant lymphoma. *JCU* 18, 569-574 (1990)
18. Goerg C, R Weide & WB Schwerk: Malignant splenic lymphoma: sonographic pattern, diagnosis and follow-up. *Clin Radiol* 52, 535-540 (1997)
19. Catalano O, S Tafuto, F Sandomenico, R Lobianco, ML Lentini, Graziano & A Siani.: Contrast-specific ultrasound a promising diagnostic technique in abdominal oncology. *E J Canc* 1, abs. n.5 (2003)
20. Lobianco R., S Tafuto, O Catalano, ML Lentini, Graziano, A Siani & S Quattrin.: Contrast specific ultrasound (CS-US) in staging and follow-up of splenic lymphoma. *Ann Onc* 14, Suppl 4 (2000)
21. Catalano O, F Sandomenico, I Matarazzo & A Siani : Contrast-enhanced sonography of the spleen. *Am J Radiol* 184, 1150-1156 (2005)

Key Words: Lymphomas, Tumor, Cancer, Lymph node, Contrast-Enhanced Specific Ultrasound, Staging

Send correspondence to: Dr Salvatore Tafuto, Department of Medical Oncology, S. Maria delle Grazie Hospital Pozzuoli, Italy; Tel: 390818552363, +393384791252, Fax: 390818552286, E-mail: salvatore.tafuto@libero.it

<http://www.bioscience.org/current/vol11.htm>