

Surgery for deep infiltrating endometriosis: Technique and rationale

William Kondo^{1,2}, Nicolas Bourdel¹, Monica T. Zomer², Karem Slim³, Revaz Botchorishvili¹, Benoit Rabischong¹, Gérard Mage¹, Michel Canis¹

¹Department of Gynecologic Surgery, CHU Estaing, 1 Place Lucie Aubrac, 63003 Clermont-Ferrand, France, ²Department of Gynecology, Sugisawa Medical Center, Av. Iguaçu 1236, Curitiba, Parana, Brazil, ³Department of Digestive Surgery, CHU Estaing, 1 Place Lucie Aubrac, 63003 Clermont-Ferrand, France

TABLE OF CONTENTS

1. Abstract
2. Introduction
3. Ergonomy
 - 3.1. Positioning of the patient
 - 3.2. Placement of the trocars
 - 3.3. Uterine manipulation
4. Principles of surgery
 - 4.1. Exposition and adhesiolysis
 - 4.2. Precise and careful dissection
 - 4.3. Respect the healthy tissue
5. Surgical steps
 - 5.1. Inspection of the abdominal cavity
 - 5.2. Treatment of lesions in the anterior pelvic compartment (anterior cul-de-sac, vesico-uterine septum and bladder)
 - 5.3. Treatment of the ovarian endometrioma
 - 5.3.1. Anatomy
 - 5.3.2. Surgical Procedure
 - 5.3.3. Surgical steps of ovarian cystectomy
 - 5.4. Treatment of lesions in the posterior pelvic compartment
 - 5.4.1. Dissection of the healthy tissue: mobilization of the sigmoid colon and identification of the ureter
 - 5.4.2. Ureteral dissection
 - 5.4.3. Transection of the utero-sacral ligament and identification of the pararectal space
 - 5.4.4. Identification of the lateral borders of the nodule and the posterior vaginal fornix
 - 5.4.5. Separation of the nodule from the anterior rectal wall
 - 5.4.5.1. Traditional technique
 - 5.4.5.2. Reverse technique
 - 5.4.6. Vaginal suture repair
 - 5.5. Final checklist
6. Comments
7. References

1. ABSTRACT

The surgical treatment of deep infiltrating endometriosis is challenging and complex. Currently, the gold standard for patient care is the referral to tertiary centers with a multidisciplinary team including gynecologists, colorectal surgeon and urologist with adequate training in advanced laparoscopic surgery. The surgical technique is essential to adequately manage the disease and to minimize the risk of complications; however, the technique is rarely taught and described in details. This paper reviews our current technique and all the tricks to allow the reproduction and even the improvement of this technique by other surgeons.

2. INTRODUCTION

Endometriosis, defined as the presence of endometrial gland tissue and stroma outside the uterus, is a common disease affecting 10 percent of reproductive-aged women (1). In the deep infiltrating forms of the disease, the endometriosis penetrates below the surface of the peritoneum invading more than 5mm in depth (2,3). Although it is difficult to know the actual incidence of deep infiltrating disease, in the series of Martin *et al* (4) they found the incidence of deep disease to be as high as 33% among 132 consecutive patients requiring resection of endometriosis.

Medical treatment undoubtedly does have a role in the management of pain symptoms related to deep

Surgery for deep infiltrating endometriosis

endometriosis; however, the effect is temporary and the pain often recurs after cessation of the therapy (3,5). Hormonal treatments must not be offered in the presence of obstructive uropathy, symptomatic bowel stenosis and adnexal mass of a doubtful nature. Women desiring pregnancy should not undergo medical therapy, due to interference with ovulation⁵. Therefore, in such patients surgery remains the only definitive treatment for deep endometriosis.

The surgical treatment of deep infiltrating endometriosis is challenging and complex (6), and the gold standard for patient care is the referral to tertiary centers with a multidisciplinary team including gynecologists, colorectal surgeon and urologist with adequate training in advanced laparoscopic surgery (7,8). The patients requiring surgical treatment must be informed about the risks of major complications, functional sequelae, and recurrence (6,9-13).

In this context, the surgical technique is essential to adequately manage the disease and to minimize the risk of complications; however, the technique is rarely taught and described in details. This paper will review our current technique and all the tricks to allow the reproduction and even the improvement of this technique by other surgeons.

3. ERGONOMY

Installation and exposure are keys to a safe and effective surgery. The initial steps are therefore essential, the goal is to make this sometimes complex surgery as simple as possible.

3.1. Positioning of the patient

Under general anesthesia, the patient is placed in a supine position with lower limbs accommodated in abduction and with flexion of the thighs onto the pelvis about 20°. The two arms are positioned alongside the body to avoid injuries of the brachial plexus. The placement of the lower limbs should avoid compression of the sciatic nerve, external popliteal nerve and calves. The buttocks of the patient should project slightly beyond the edge of the operating table to allow for an effective uterine manipulation (14).

3.2. Placement of the trocars

A classic laparoscopic setup is established with an umbilical trocar for the 10mm zero degree laparoscope and three 5mm trocars in the suprapubic region. One trocar is positioned at the midline, 8 to 10 cm below the umbilical trocar, and two trocars are placed in the iliac fossae, about 2 cm medial to the anterior superior iliac spine. If a bowel resection is planned, lateral trocars are positioned higher in the lateral-umbilical region, and a fifth trocar may be inserted into the right upper quadrant if necessary. This classical installation may be changed according to the patient anatomy, especially when the distance between the umbilicus and the pubic bone is short. In such cases, if the midline suprapubic trocar is inserted as described above (8 to 10cm below the umbilical trocar), it is placed too close to the pubic bone what limits the access to the pelvis. Therefore, in such patients the trocar for the optics should be inserted above the umbilicus.

3.3. Uterine manipulation

An effective uterine manipulation is mandatory! This is achieved by the placement of a high caliber curette through the cervix, which is fixed to a Pozzi clamp. This allows anterior uterine flexion and limits the risk of perforation of the uterine fundus. When necessary, this method also allows the easy performance of a digital vaginal and/or rectal examination during surgery to identify the limits of those lesions attached to the posterior vaginal fornix.

4. PRINCIPLES OF SURGERY

The principles of surgery for severe endometriosis are simple and may be didactically divided into:

- Exposition and adhesiolysis;
- Precise and careful dissection;
- Complete excision of the disease whenever feasible and or reasonable;
- Respect to the healthy tissue.

4.1. Exposition and adhesiolysis

- Adhesiolysis: all the adhesions that may exist between the posterior wall of the uterus, the adnexa, and the gastrointestinal tract are released;

- Good exposition: using effective uterine manipulation, ovarian suspension, and bowel suspension, when needed. Suspensions are achieved through the abdominal wall with sutures (Figure 1).

4.2. Precise and careful dissection

- Start with the dissection of healthy tissue in order to identify vulnerable structures (ureters, vessels and branches of the nerve plexus) and systematically progress towards the focus of pathological tissue;

- Do not wash! The carbon dioxide gas flows into the retroperitoneal space and helps the surgeon to find the correct cleavage plane. The adequate plane can be identified when the non-pathological loose connective tissue is retracted and the pressure of the pneumoperitoneum inside this tissue gives rise to the “bubbles”. These “bubbles” indicate absence of disease and guide the dissection. The instillation of liquid during the procedure limits the spread of the gas into the tissue and thus the formation of these “bubbles”. Moreover the presence of fluid creates edema which obscures the plane of dissection.

- Follow the “bubbles”! They indicate the correct and healthy plane;

- Create the “arrows” and cut them! Frequently, when the tissue or the plane to be dissected or excised is adequately exposed, “triangles” (or “arrows”) may be

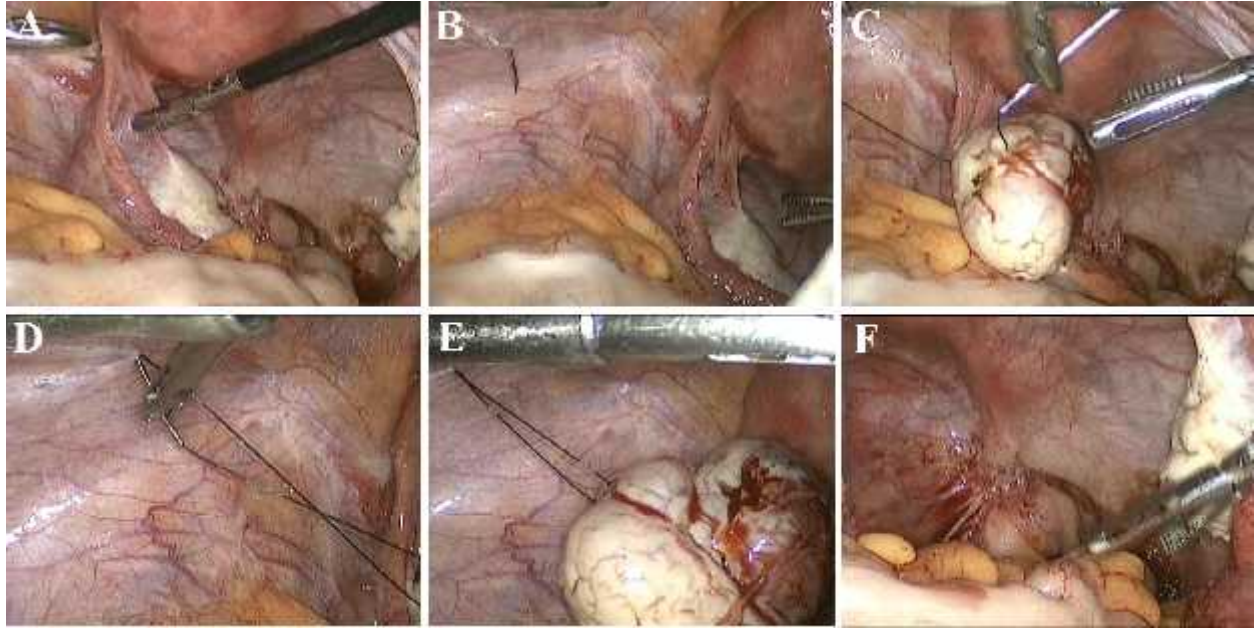


Figure 1. Ovarian suspension is achieved through the abdominal wall with sutures.

identified on the screen. These “arrows” indicate the limits between the normal and the diseased-tissue and may help the identification of the exact place to be coagulated and cut to ensure optimal excision of the disease and adequate dissection in the correct cleavage plane with minimal trauma to healthy tissue;

- Excision of the endometriotic lesions should be as complete as possible;

4.3. Respect the healthy tissue

- Precise and careful dissection is going to preserve the integrity of the non-diseased tissue. The vulnerable structures should be dissected, the “bubbles” indicate the plane to be followed, and the “arrows” show the limits of the diseased-tissue;

- Follow all the principles of microsurgery proposed during the late seventies by Winston, Gomel, Swolin and Brossens including non-traumatic handling of the tissue, preventive and meticulous hemostasis;

- Avoid unnecessary dissection, displacement and trauma of the surrounding organs and tissues. Indeed, endometriosis is a benign disease that requires surgical excision; however, it is not necessary to have large margins of normal tissue as it would be mandatory in the treatment of a cancer.

Nevertheless, the application of these principles is complex. In particular, the identification of boundaries between normal and diseased-tissue is not always easy. The presence of black spots in the area of resection means that there is presence of micro-cysts of endometriosis, which indicates that the area of resection should be extended (Figure 2). When identification of boundaries is difficult, it

is useful to read the monitor to look for the presence of “arrows” that indicate where to place the next incision (Figure 3). The indication that resection is complete is the identification of fatty tissue or normal muscle tissue. Conversely, unhealthy or fibrous tissue is suspected when there is a whitish appearance and reduced tendency to bleed. This notion of interpretation is more difficult in the deep part of the utero-sacral ligament. When the section is performed in a healthy tissue, one can realize that the sectioning of 1 or 2mm allows for the mobilization of 5, 10 or even 20 mm of the retracted tissue, confirming that the healthy tissue was released and became more mobile (Figure 4).

The identification of these limits requires perfect vision, which is only possible with strict hemostasis. However, hemostasis should not always be preventive. If tissue bleeds, it is usually a sign that it is free of endometriosis. One should also be aware that the coagulation of blood vessels can produce images that appear similar those obtained in the periphery of the lesion of endometriosis. Unnecessary dissection of vulnerable structure should be avoided. Indeed, some of these patients will require several surgical procedures throughout their life. Each one of these operations may include the dissection of fragile structures such as the ureter and it is well known that each ureterolysis traumatizes the ureteric vessels. So, when this procedure is repeated two or three times the risk of postoperative ureteral fistula obviously increases. Therefore, a complete dissection of vulnerable structures should be performed only when necessary! Certainly, when the patient has an endometriotic nodule located in the pouch of Douglas with no involvement of the utero-sacral ligament, a routine dissection of the ureters is not necessary.

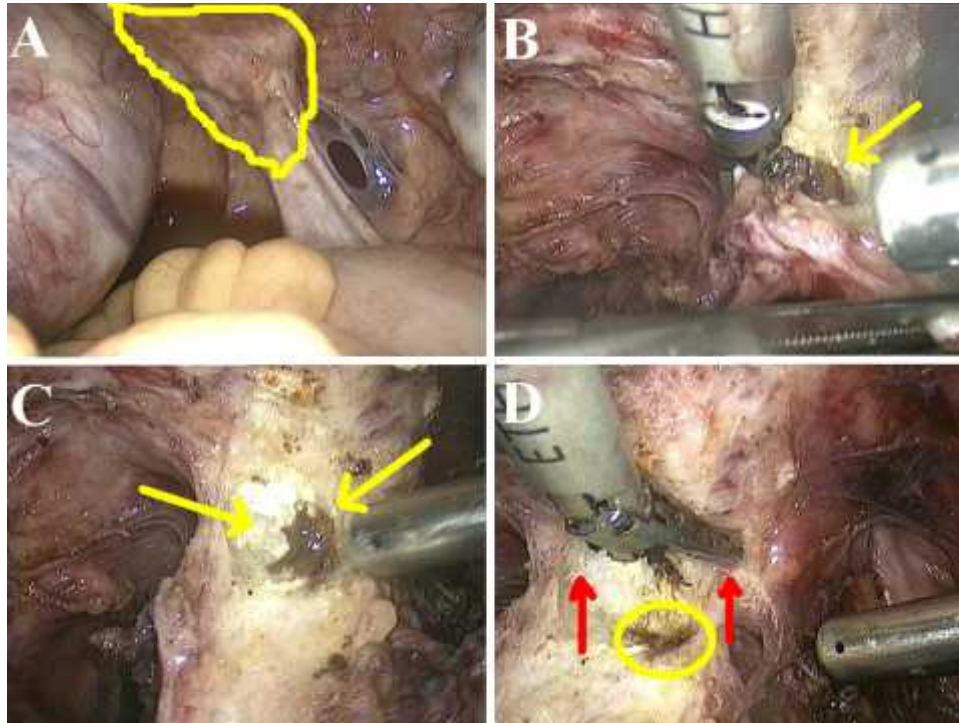


Figure 2. (A) Posterior endometriotic lesion (in yellow) infiltrating the right utero-sacral ligament and the retrocervical area. (B and C) During the resection of the retrocervical lesion a chocolate fluid is visible (yellow arrows), meaning that there are still micro-cysts of endometriosis. (D) The area of resection is extended (red arrows).

5. SURGICAL STEPS

5.1. Inspection of the abdominal cavity

The first step of the procedure should be the inspection of the entire pelvis and the abdominal cavity in order to find all the endometriotic lesions and to plan the surgery. A rotation of 360 degrees in a clockwise direction should be performed in the abdominal cavity with the laparoscope starting from the right iliac fossa, and ending in the pelvis. In the pelvis, the surgeon should check the anterior compartment (bladder, vesico-uterine septum, peritoneum, round ligaments), the uterus, the tubes, the ovaries, and the posterior compartment (retrocervical area, utero-sacral ligaments, recto-vaginal septum, rectum, and sigmoid). Also, the broad ligaments are common places to find endometriotic lesions, especially in the presence of ovarian endometriomas. The path of the ureter should be checked because the ureteral dissection usually guides the resection of deep lesions. In the presence of low rectal endometriosis, the ileocecal region should be carefully inspected as it may be affected in up to 24% of the cases (15).

5.2. Treatment of lesions in the anterior pelvic compartment (anterior cul-de-sac, vesico-uterine septum and bladder)

This step is a good step to learn about “arrows” and “bubbles”. The lesions located in the peritoneum of the anterior cul-de-sac are generally easy to excise. The first assistant should grab the normal peritoneum around the

endometriotic nodule and the surgeon should coagulate and cut the peritoneum in the normal area. This leads to the opening of the vesico-uterine space and the carbon dioxide enters into the disease-free space creating the “bubbles”. The “bubbles” should be followed and they indicate the limits of the dissection. The “arrows” connect the endometriotic lesion to the non-pathological tissue. These “arrows” indicate the exact place to cut in order to achieve the complete resection (Figures 5 and 6).

5.3. Treatment of the ovarian endometrioma

5.3.1. Anatomy

The ovarian endometrioma contains 3 different areas (Figure 7). The first is an area of adhesion between the endometrioma and the posterior leaf of the broad ligament. The second is an area of active endometriotic tissue with small amount of fibrosis, where dissection is usually easily performed. The third is an area of intense fibrosis, where the cleavage plane is difficult to find.

5.3.2. Surgical procedure

The lesions of superficial ovarian endometriosis can be treated by simple bipolar cauterization; short-time applications should be used to minimize thermal damages. Vaporization instruments such as CO₂ laser are very effective tools, when available. The cystic endometriomas can be treated in two ways:

- Ovarian cystectomy;

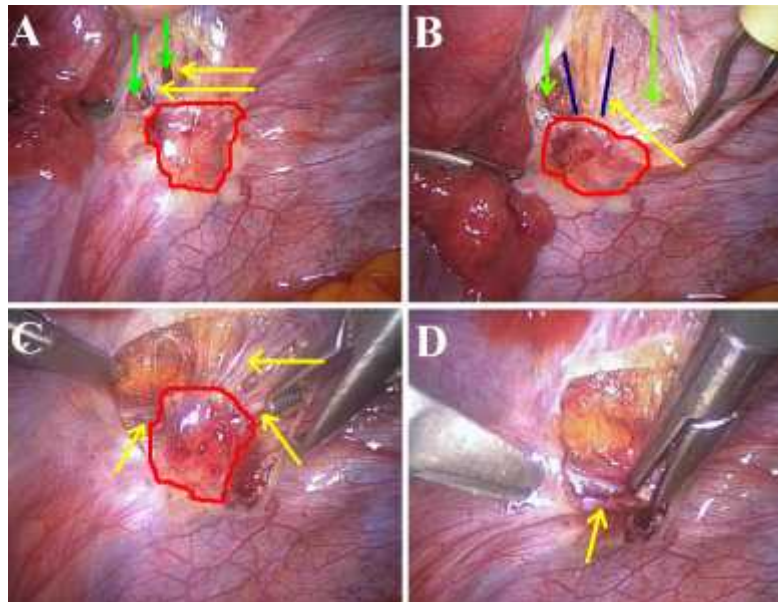


Figure 3. (A) After beginning the incision, the normal peritoneum retracts away from the disease (in red). In the retroperitoneal space, two tissues are visible. Fibrosis (yellow arrows) immediately underneath the implant and loose cellular tissue deeper (green arrows). (B) The same areas are now more clearly visible. The blue lines indicate our "arrows". (C) Retroperitoneal fibrosis is clearly visible on this picture, before cutting it it is necessary to dissect retroperitoneal structures such as the ureter and the uterine artery. The "arrows" (yellow arrows) are visible around the lesion (in red). (D) Yellow fatty tissue is a normal tissue. The white structures are abnormal fibrosis (yellow arrow).

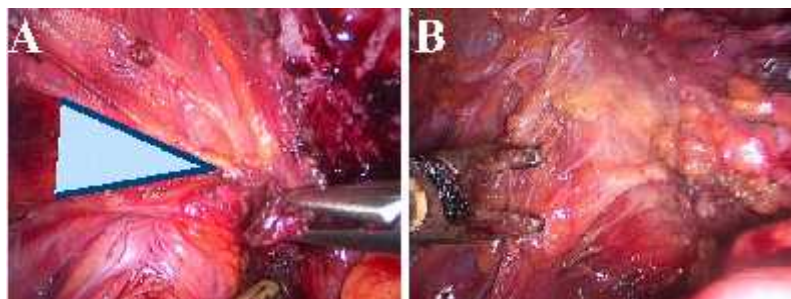


Figure 4. (A) The "arrows" are visible creating a "triangle". (B) When the top of the "triangle" is cut, it allows for the mobilization of the retracted tissue. This picture was taken immediately after the section of the top of the "arrow" indicated on Figure 3A. The nodule moved away and the normal tissue was found!

- Drainage and coagulation or laser/plasma vaporization, without resection of the pseudocapsule. Exclusive coagulation using bipolar energy seems to be no longer recommended (16). Plasma (16-18) or CO₂ laser (19,20) vaporization are acceptable.

Small endometriomas (less than 3cm) can be aspirated, irrigated and inspected internally to seek intracystic lesions. The lining of the cyst may be coagulated or vaporized to destroy the endometriotic lining. Endometriomas larger than 3 cm should be preferably completely removed (21). Saleh and Tulandi (22) retrospectively evaluated 231 women with endometriomas treated by laparoscopy and found that the cumulative rate of reoperation was higher after fenestration and destruction of the inner layer of the cyst compared with cystectomy.

The rates of reintervention at 18 and 49 months were respectively 6.1% and 23.6% after cystectomy and 21.9% and 57.8% after fenestration, aspiration and destruction of the inner wall of the cyst. These results were confirmed by the Cochrane's review (23).

5.3.3. Surgical steps of ovarian cystectomy

In the presence of ovarian endometriomas, they must be mobilized and drained before the treatment of posterior deep endometriosis. Thereafter the treatment of the ovarian cyst itself can be performed before or after the treatment of the deep nodule, depending on the local conditions and on the surgeon preference. We strongly recommend doing it early during the operation because this step is not as easy as some people think and requires a meticulous microsurgical technique to achieve maximal

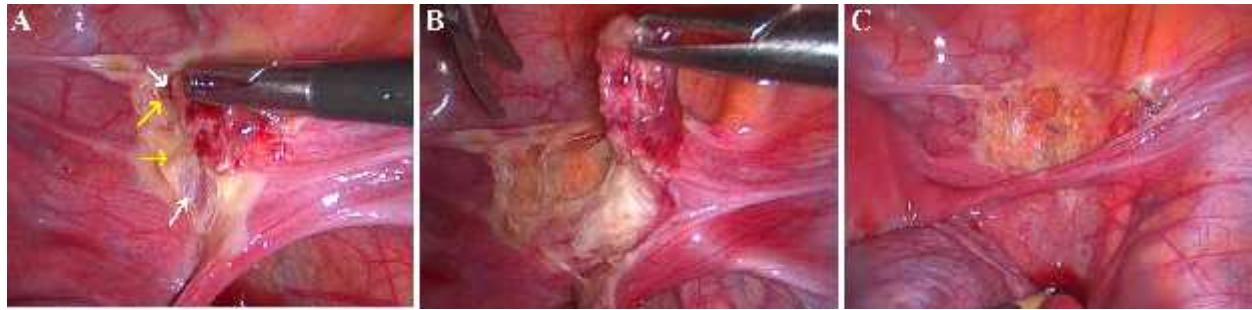


Figure 5. (A) The “bubbles” indicating the disease-free plane are indicated by the white arrows. The “arrows” connecting the endometriotic lesion to the normal tissue are indicated by the yellow arrows and they should be cut to finish the resection. (B) The lesion is released from the non-pathologic tissue. (C) Final aspect of the resection.

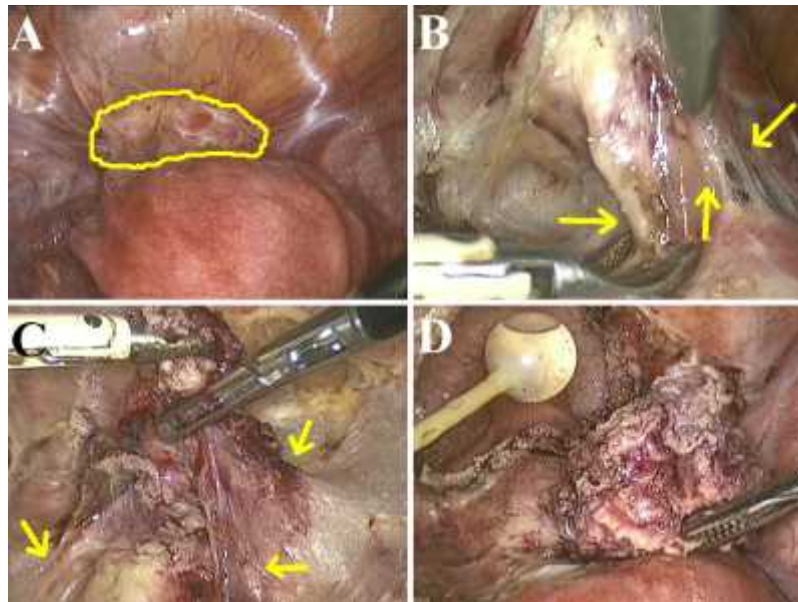


Figure 6. (A) Bladder endometriosis. (B and C) The “bubbles” are seen around the endometriotic lesion and the “arrows” (indicated by the yellow arrows) indicate the place to cut the tissue. (D) Final aspect of the bladder resection.

ovarian tissue preservation. Surgeons are more likely to be patient and meticulous at the beginning of the procedure than after 3 hours.

The ovary containing endometrioma is usually fixed to the peritoneum of the ovarian fossa or to the ipsilateral utero-sacral ligament. The ovarian cystectomy is performed as follows (Figures 8 and 9) (24):

- Adhesiolysis (Figure 8): the ovary is released from the peritoneum of the pelvic wall. In most of the cases, the cyst is ruptured and the typical “chocolate” fluid spills into the peritoneal cavity (Figure 7 – Area 1);
- The peritoneal cavity is washed and the cystic contents are aspirated;
- The cyst wall opening is then enlarged using scissors, starting from the ruptured area. Do not open the cyst in another place! The incision is enlarged enough to find the cleavage plane (Figure 9A);

- Divergent traction (Figure 9B): one grasper is placed in each edge of the cleavage plane between the endometrioma cyst wall and the ovarian parenchyma. Smooth divergent traction must be performed applying the strength enough to separate the cyst wall from the ovarian parenchyma without tearing it. The surface of the endometriotic cyst is whitish, the plane is avascular, and the bleeding is minimal. This step of the dissection corresponds to 10 to 90% of the cyst wall (Figure 7 – Area 2). It is essential to move the forceps slowly and to stop the procedure if this dissection induces any bleeding. It may be a sign that the third area of the endometrioma was reached;

- Indeed, in the deeper aspect of the endometrioma divergent traction becomes progressively less efficient. The endometrioma wall is not uniformly whitish anymore and some reddish fibers are visible on the cyst wall (Figure 9C). Simple divergent traction must stop! Fibrosis in this aspect of the lesion is stronger than the ovarian parenchyma (Figure 7 – Area 3). The reddish fibers should be coagulated at the outer surface of the cyst, at the

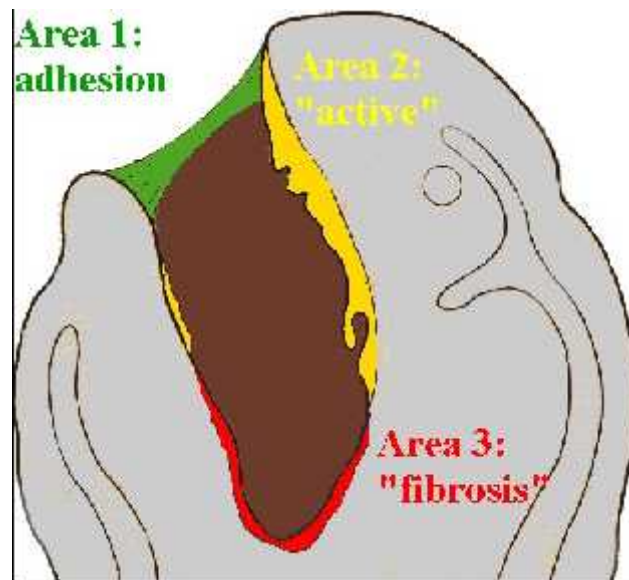


Figure 7. Schematic drawing of the ovarian endometrioma.

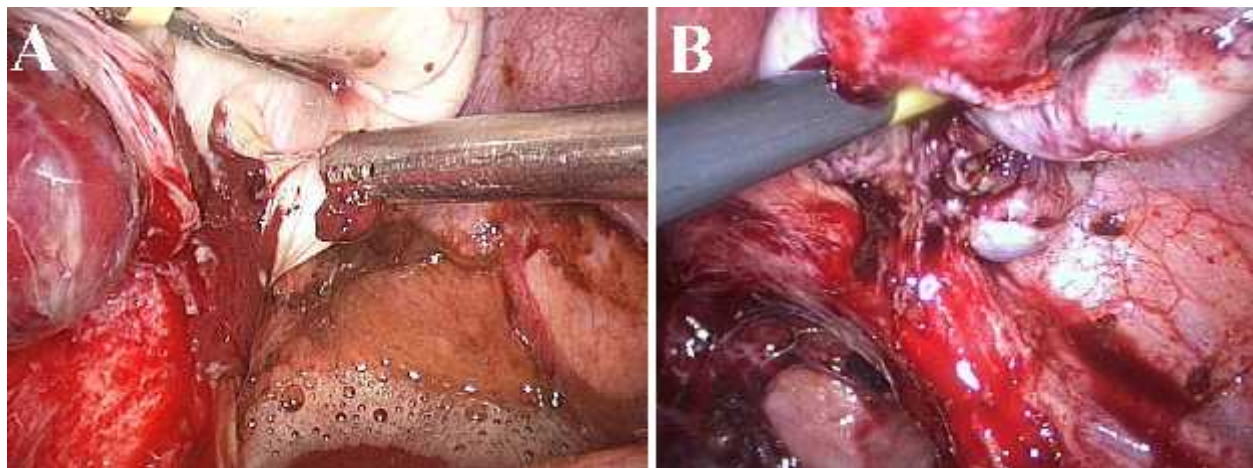


Figure 8. (A) The left ovary was released from the peritoneum of the pelvic wall. The chocolate fluid spills into the peritoneal cavity. (B) The right ovary is released from the utero-sacral ligament.

level of the top of the “triangle” (confluence of 2 “arrows”), and cut in order to find the correct cleavage plane (Figures 9D and 9E);

- Hemostasis of the inner surface of the ovary should be spontaneous or obtained with bipolar coagulation with parsimony (Figure 9F). Ovarian suture may be an alternative solution for hemostasis (16); however we rarely use it. Similarly, sutures are indicated to repair the ovary only when the shape of the ovary is not spontaneously approximated at the end of the procedure. When indicated, one or two sutures may be placed inside the ovary to minimize ischemic tissue on the ovarian surface;

- Extraction is performed using an endoscopic bag removed through the umbilical trocar.

5.4. Treatment of lesions in the posterior pelvic compartment

5.4.1. Dissection of the healthy tissue: mobilization of the sigmoid colon and identification of the ureter

The sigmoid colon is mobilized from the left pelvic sidewall and adnexa. This step facilitates the dissection and the treatment of the left adnexa and the identification of the left ureter, medial to the infundibulo-pelvic ligament on the pelvic brim. This step is also a good step to learn about “arrows”. Indeed, when the sigmoid colon is retracted medially by the first assistant, the “arrows” are visible and show the place to be cut to identify the best plane of dissection (Figure 10).

5.4.2. Ureteral dissection

The ureteral dissection guides the resection of the deep endometriotic lesion. However, this step should not be

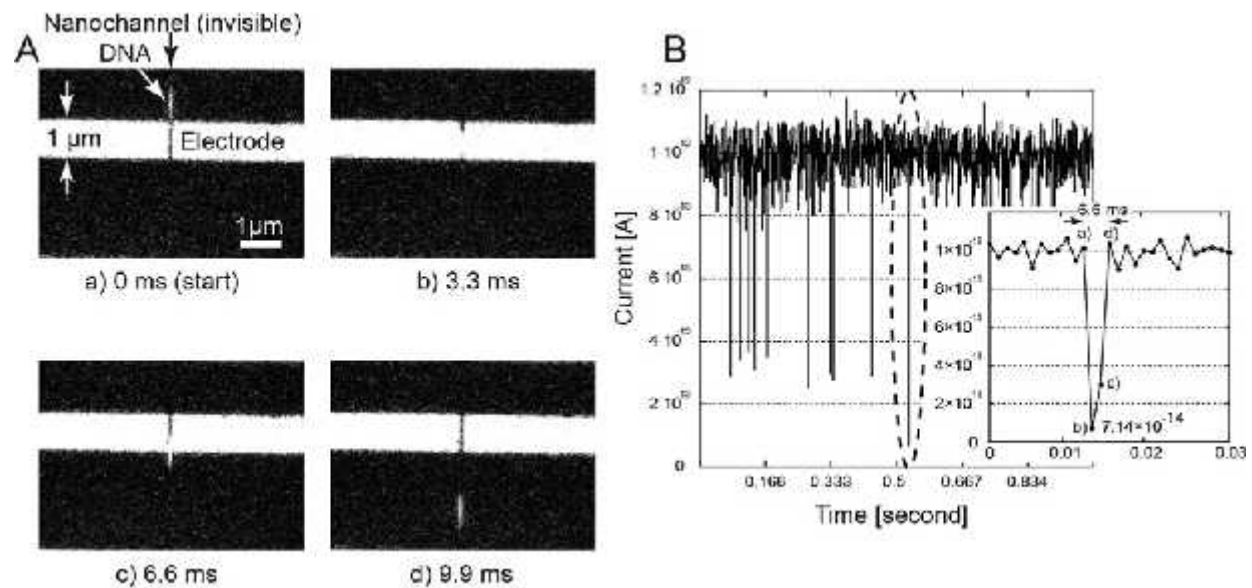


Figure 9. (A) After the ovariolysis, the ruptured zone should be enlarged to find a cleavage plane (yellow arrow). It should be enlarged up to an area where the ovarian tissue around the cyst is thicker. In the first area there is no ovarian tissue around the cyst, so that no plane can be found (blue arrow). (B) Second area: the dissection is easy and bloodless, and the surface of the endometrioma is white (yellow arrow). (C) The initial step of the dissection is easy, but red fibers are now visible on the cyst wall (yellow arrow). (D) Third area: red fibers are visible on the surface of the cyst and the dissection becomes more difficult. The technique must be changed; the plane is exposed with two grasping forceps and the plane is dissected using bipolar coagulation and scissors. By exposing the plane, you ask the patient where to go and she shows you! The “arrows” are represented by the yellow lines. (E) The plane identified is white and bloodless, and the “arrows” (yellow lines) are now visible on the remaining ovarian tissue. (F) Final view inside the ovary.

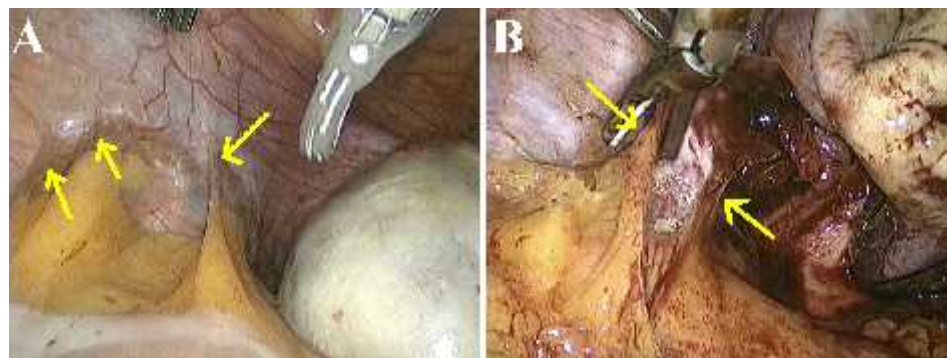


Figure 10. (A and B) The “arrows” are visible attaching the sigmoid colon to the pelvic sidewall. As soon as the surgeon cut the “arrows”, the correct plane is found and the “bubbles” appear in the retroperitoneal space.

systematic and depends on the characteristics of the endometriotic lesion to be treated, as follows:

- Lesions not including the broad ligament – the ureter should be left out of the dissection;
- Lesions involving the utero-sacral ligament and/or the retrocervical region – dissection of the medial aspect of the ureter is enough (Figure 11);
- Involvement of the entire broad ligament – all aspects of the ureter must be dissected.

In the case of large lesions (more than 3 cm) the ureter is completely released until their cross with uterine vessels to ensure that there is no risk of ureteral injury during the final resection.

During this phase of ureteral dissection, ovarian suspension is very useful because it liberates a surgical instrument for other maneuvers. After releasing the ovary from the broad ligament, the suspension can be accomplished by using a straight needle passing through the abdominal wall and through the ovary, attaching it to the anterior abdominal wall.

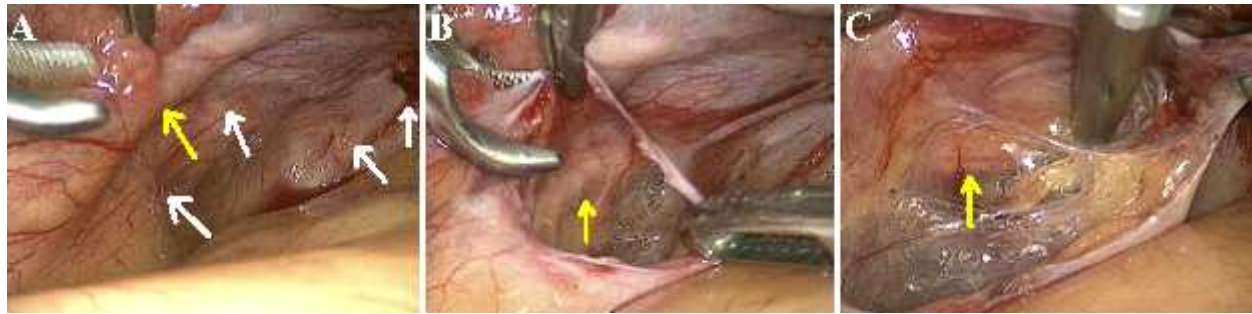


Figure 11. (A) The white arrows indicate endometriotic lesions in the broad ligament. The yellow arrow indicates the left ureter. (B and C) The medial aspect of the left ureter (yellow arrow) was dissected. It is possible to identify again the “bubbles” in the retroperitoneal space guiding the dissection and the resection.

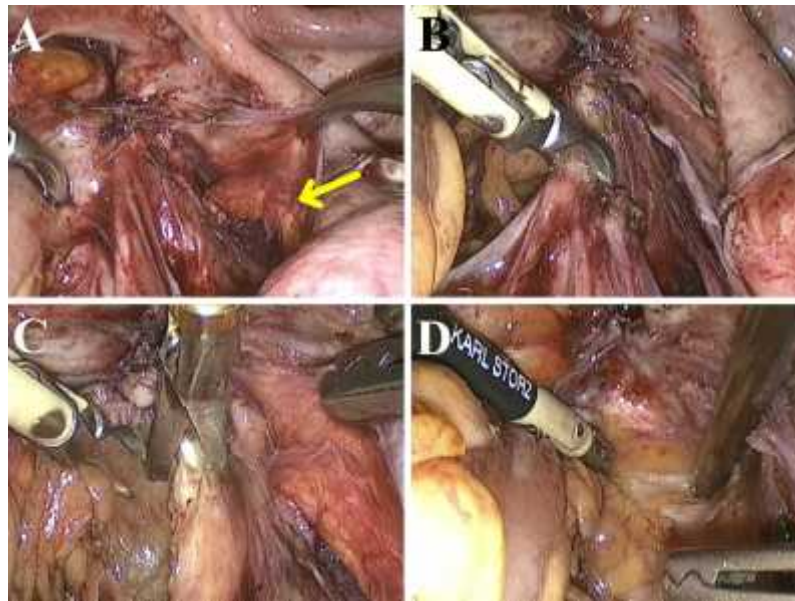


Figure 12. (A) The right ureter is indicated by the yellow arrow. (B) The right utero-sacral ligament is coagulated and cut. (C) The “bubbles” arise and they mean: here is the plane! (D) The pararectal fossa is identified by means of divergent traction.

5.4.3. Transection of the utero-sacral ligament and identification of the pararectal space

After separating the ureter posterior-lateral to the lesion, the utero-sacral ligament is pulled medially and transected. In this step of the procedure, the cleavage plane is easily identified by the presence of “bubbles” arising from the CO₂ gas entering into the loose connective tissue and the fatty tissue. Divergent traction facilitates penetration of CO₂ into the tissues (Figure 12). Dissection continues towards the para-rectal fossa. At this level, resection should not be systematic but guided by the extent of the lesion.

The rectum is displaced in the opposite direction and the scissors are opened in the space created by the CO₂ “bubbles” defining the course of dissection. The space is enlarged by using divergent traction with two instruments placed in the region where the “bubbles” are seen. This dissection should be bloodless. If the dissection is not progressing, it is usually because the lesion extends below

the utero-sacral ligament and the resection should be broader. If nerve fibers are identified, they should be preserved whenever possible. The surgeon must check, usually by vaginal and rectal examination, whether or not the lateral/lower limit of the nodule compromises the nerves that were just identified. These nerves can be dissected and preserved when they are not infiltrated by the disease (25,26). When the deep endometriotic lesion compromises the nerves, they have to be excised to ensure a complete treatment of the disease. The Figure 13 demonstrates a nerve-sparing procedure.

5.4.4. Identification of the lateral borders of the nodule and the posterior vaginal fornix

Once the pararectal fossa is identified, dissection continues anteriorly to define the lateral and distal limits of the nodule. The aim here is to find the disease-free vaginal fornix at the rectovaginal septum. It is important that the lateral limit of the resection is far away from the ureter, which should be located laterally. The risk of ureteral

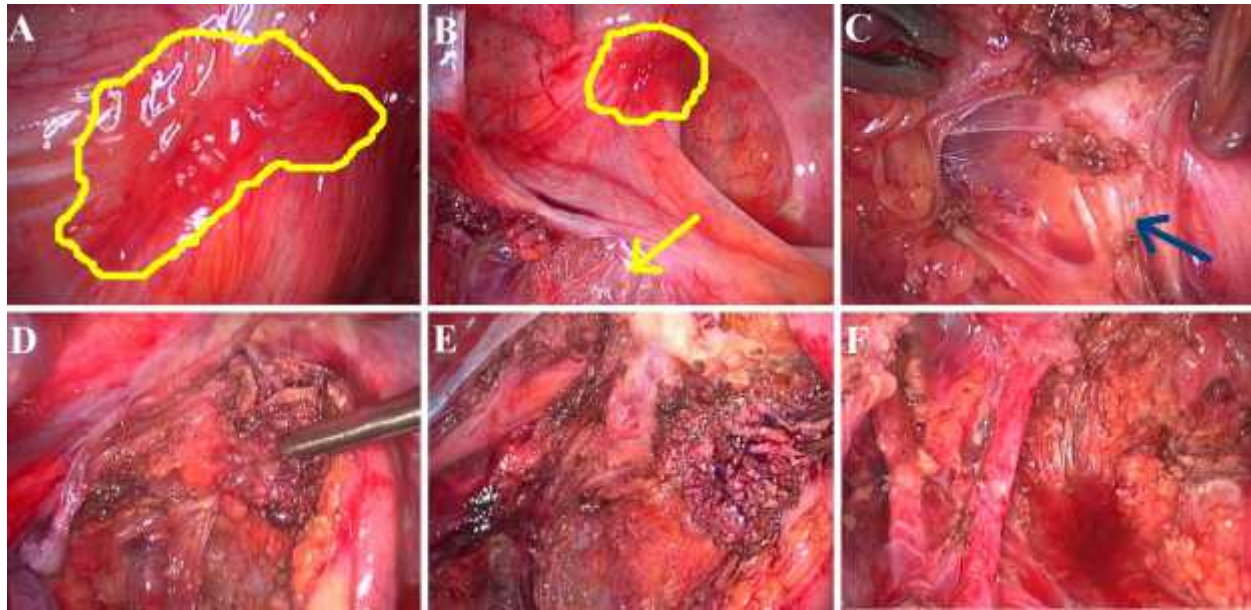


Figure 13. (A) Endometriotic lesion (in yellow) on the left utero-sacral ligament. (B) Dissection of the retroperitoneal space to identify the left ureter. The “bubbles” appear (yellow arrow) meaning that the disease-free plane is there. (C) As the disease does not affect the nerves (blue arrow), they can be preserved. (D to F) Nerve-sparing endometriotic nodule resection.

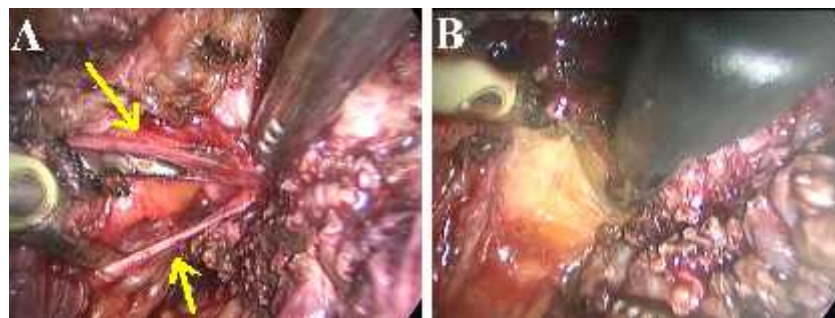


Figure 14. (A) “Arrows” mean: cut here! (B) The identification of fatty tissue means that the resection was enough.

injury must not exist during vaginal resection. There must also be a margin of safety to allow for bipolar hemostasis of any eventual bleeding vessel without risk of thermal injury to adjacent vital structures. To ensure that the dissection is sufficient, the surgeon performs a vaginal palpation with his left hand and manipulates a laparoscopic forceps with the right hand in contact with the vagina in an attempt to discern for a soft and clinically normal vagina, distal to the endometriotic nodule at the posterior vaginal fornix. The goal here is to identify the healthy vagina distal to and outside the nodule that will be resected.

During the dissection of the distal and lateral limits of the nodule, exposure is essential. Indeed, when traction of the nodule allows a satisfactory exposure, it is generally possible to identify “arrows” which help the surgeon to find the limit between the normal and the abnormal tissue (Figure 14A). This limit is further confirmed when the section of a specific area greatly improves the mobility of the nodule and/or when normal tissue is identified beyond the section of the abnormal area

(Figure 14B). In contrast, if the section does not improve the mobility of the nodule, the surgeon must check that the limit of his excision is really adequate. In this situation, the tissue identified after the section is usually fibrotic suggesting that the excision is not large enough.

However, one should always be careful when deciding to perform a larger excision. The risk of injury to vulnerable structures increases and it is necessary to identify and dissect them completely before carrying on this more aggressive management. One should be particularly cautious when deciding to extend the excision posterior and laterally, close to internal iliac bifurcation. In this area severe bleeding may occur and it is difficult to treat because whenever a large artery or vein is opened, the injured vessel tends to retract into the fibrotic tissue. To prevent this potentially dangerous complication, it is necessary to dissect the origin of the internal iliac vessels first. Whenever possible, this situation should be anticipated in the preoperative work-up. To the best of our knowledge, the lateral and posterior extension of the deep

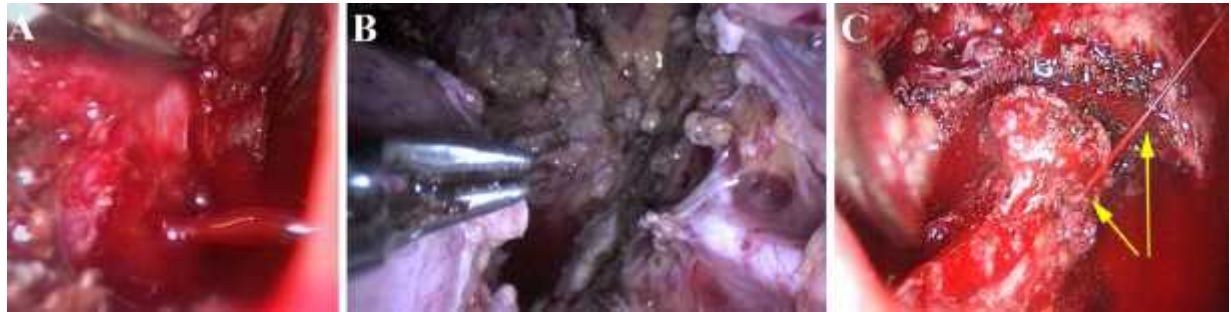

Figure 15. (A) A hemorrhage from a large pelvic vein injured during the dissection of the posterior aspect of the endometriotic nodule close to the internal iliac artery and vein. (B) The final picture after excision of a large endometriotic nodule. The anterior branch of the internal iliac artery, cut during the dissection, is visible in the lower right corner of the picture. (C) A hemorrhage from a rectal vessel.

lesion is best appreciated by rectal examination. When the posterior and lateral extension is severe, the iliac vessels should be identified and dissected before the resection of these aspects of the lesion. In this way, large vessels can be easily clamped if a severe bleeding occurs (Figure 15).

5.4.5. Separation of the nodule from the anterior rectal wall

Two surgical approaches can be used (27):

5.4.5.1. Traditional technique

Traditionally, gynecologists separate the posterior surface of the nodule from the anterior rectal wall before releasing the nodule from the posterior aspect of the uterus/vagina. It is important to remember that the lower this dissection, the more anterior must be the application of the scissors in order to avoid rectal injury. Retraction caused by the endometriotic nodule displaces the involved rectum; therefore the axis of dissection is not always the same. The axis of dissection is directed anteriorly in the lowest part of the dissection.

The surgeon should follow the contour of the rectum around the endometriotic nodule and should always identify what must be cut by an act of sharp dissection using the scissors. Even if the rectum initially seems distant, it is not uncommon for it to “move” closer as the dissection proceeds. When using this approach, the goal is to continue the release of the nodule from the anterior rectal wall to identify the healthy vagina distal to the nodule. This dissection can be aided by a digital vaginal and/or rectal palpation, by the placement of a sponge or a soft valve in the posterior vaginal fornix, or by the placement of a rectal probe. After the release of the posterior surface of the nodule from the rectal wall (lower and distal limits), it must be released from the posterior surface of the uterus, the base of the broad ligament and the vagina. The vaginal resection can be performed using scissors or a fine monopolar tip (1 mm in diameter) in pure cut mode, since this maneuver entails little risk for the vulnerable structures which have been previously identified and dissected. The minimal coagulation effect when the cautery is adjusted in pure cut mode allows for the precise identification of the limits of the lesion. Whenever a chocolate cyst is encountered or black spots are seen in the tissue at the

margins, resection is not enough and should be expanded. When vaginal opening is required, it is necessary to place a glove containing 2 or 3 gauzes inside the vagina in order to prevent loss of CO₂.

5.4.5.2. Reverse technique

The second approach is called reverse technique. The anterior surface of the nodule is first released from the posterior surface of the uterus and vagina (Figures 16A to 16D). The mobility obtained after the release of the anterior aspect of the nodule allows for better exposure of it during dissection of the most difficult area to be treated, which is in contact with or near the rectum. When the nodule infiltrates the vagina, it is opened at the superior aspect and then laterally, in each side of the rectum, towards the disease-free zones that have already been dissected at the distal portion and around the nodule. The distal section is performed in the disease-free rectovaginal plane, distal to the vaginal nodule (Figures 16C and 16D). Then, the vagina is sutured and the nodule is pulled with a grasper to expose its posterior surface adhered to the anterior rectal wall (Figures 16D to 16F). This approach though harder to conceive, seems to simplify and make the surgery more feasible. This bears out a basic surgical principle that says that exposure is the key to any surgery, which means that more difficult steps of the procedure must be executed with an even better exposure. However, to gynecologists this approach seems less logical because the more distressing step of the procedure (dissection of the nodule from the rectum) is the last to be performed.

Again, during the separation of the nodule from the rectum a good exposure allows for the identification of the “arrows” which must be followed. Moreover it is essential to remember that the nodule is retracting the anterior rectal surface in 3 dimensions. Therefore, it is important to free it gradually and to always choose the easier area first to be dissected. For instance, if the left surface is easier to do since fat tissue is still visible on the surface of the rectum, this side should be treated first because it will probably facilitate the treatment of the other rectal surface, which can be more deeply involved. This approach allows for preserving the normal tissue as much as possible while achieving a complete treatment of the disease. When shaving the nodule from the rectum, the

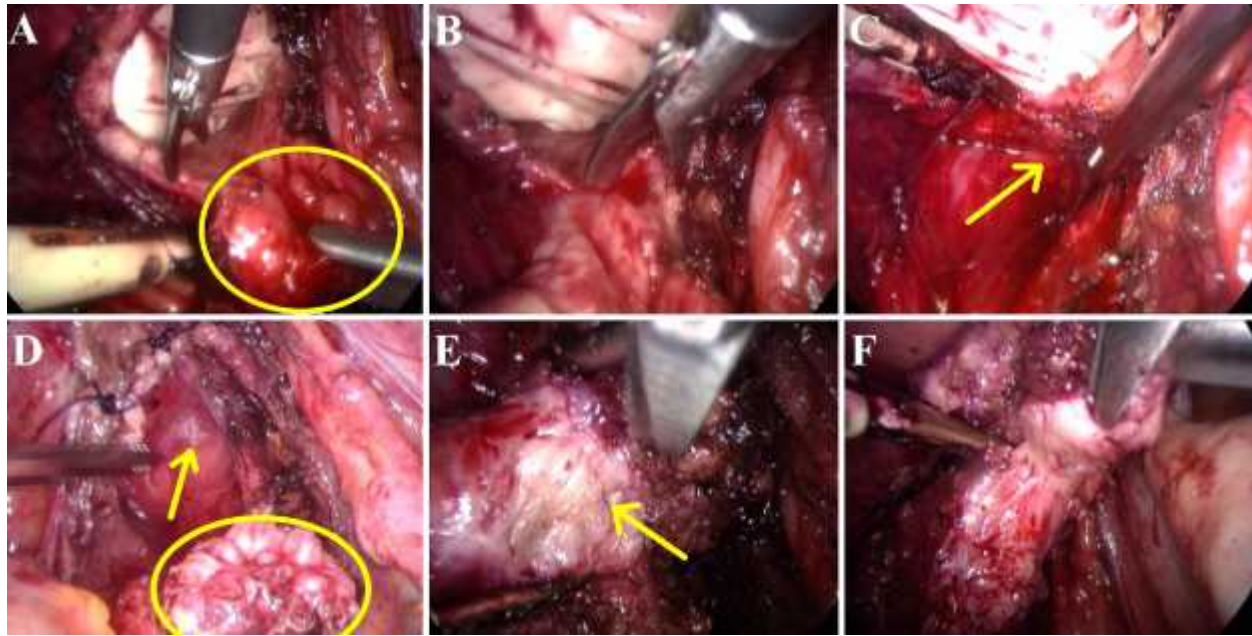


Figure 16. (A) The nodule (yellow circle) is separated from the posterior surface of the uterus and the posterior vaginal fornix is resected. (B and C) The distal limit of the vaginal resection is conducted in the disease-free recto-vaginal septum (yellow arrow). (D) The “bubbles” may be seen once the disease-free rectovaginal septum is identified (yellow arrow). The vagina is sutured and the nodule remains attached only to the anterior surface of the rectum (yellow circle). (E and F) The nodule is shaved off the anterior rectal wall and the muscle fibers of the rectum are seen during this step of the procedure (yellow arrow). Again, the “arrows” between the muscle layer of the rectum and the endometriotic nodule indicate the place to cut.

dissection is easy and not dangerous when fat tissue arises during the section of the limits of the disease. When the plane is closer to the rectal wall vessels are usually found, and the next structure to be seen is the rectal wall with longitudinal muscular fibers (Figures 16E and 16F). Again, during this step of the procedure adequate exposure may identify the “arrows”. When shaving is being done in the muscular layer of the rectum, preventive hemostasis should not be used because it may weaken the rectal wall. Scissors are used first and hemostasis is done only when necessary. We often use a new scissors during this step of the procedure in order to have a more precise excision without the use of much strength.

After this excision of the nodule, the rectum is carefully inspected and palpated looking for residual disease. If the residual disease is large and the patient has severe bowel symptoms, a segmental bowel resection is performed. This step is always achieved in collaboration with a digestive surgeon. Conservative rectal surgery (rectal shaving) and segmental bowel resection should be obviously compared in prospective randomized trials (11,28).

5.4.6. Vaginal suture repair

The vaginal suture can be performed vaginally or laparoscopically (Figure 16D). The vaginal access is not always easy in patients who have not had children and in those who received an anti-estrogen treatment. For this reason, a change in the position of the lower limbs (flexion

and abduction of the thighs, as in traditional vaginal surgery) is often necessary. To facilitate placement of this suture, Muzeux forceps are positioned on the posterior lip of the cervix, which is pulled up. The vaginal incision is exposed with two valves. Laterally, a simple vaginal suture must be performed. In the posterior aspect of the cervix, the technique for suturing is different. At this level, the vagina should be reattached to the posterior aspect of the cervix.

The vaginal closure performed vaginally limits the amount of suture material that remains in the peritoneal cavity, reducing the risk of postoperative adhesions. Laparoscopic intra- or extracorporeal suturing is performed only for small vaginal openings and for patients who have a very narrow vagina.

5.5. Final checklist

The intervention must end with a checklist that includes:

- Methylene blue test for assessment of tubal patency (when indicated; not systematically);
- Verification of hemostasis;
- Check the integrity of the rectum: 100ml of air injection into the rectum after placing 100ml of ringer lactate in the pelvis (Michelin test);
- Verification of peristalsis and color of the ureter (no blue or white zones);

Surgery for deep infiltrating endometriosis

- In the event of bleeding or visceral injury, it must be fixed immediately and completely; secondary treatment of complications is always infinitely more difficult and stressful than immediate treatment.

6. COMMENTS

Surgical treatment of deep infiltrating endometriosis should be better performed in referral centers with a multidisciplinary team. The surgery is often laborious and difficult, requiring skilled laparoscopic surgeons, integrated teams, and standardized procedures.

The application of the above-mentioned principles of surgery allows for a better quality of dissection, the identification of the exact limits of the disease, and a faster surgical procedure. The “bubbles” always indicate the disease-free plane and the path to be followed. The “arrows” show the surgeon where to cut because they represent the fibrous tissue between the disease and the normal tissue. Whenever the “arrows” are cut in the correct place, the mobility of the endometriotic nodule is improved and the disease-free tissue appears beyond the disease.

Thanks to the technological progresses and to the development of endoscopic techniques, the surgical management of severe endometriosis has been revolutionized; so that, the surgical technique may be described in details. However, we still have to answer to numerous questions about the indications of the surgical treatment, its effectiveness, and the functional consequences of the various surgical approaches currently available. For instance, the optimal management of ovarian endometriomas and deep disease with bowel infiltration are highly controversial.

Ovarian endometriomas should not be systematically operated. Care must be taken especially in reproductive-aged women desiring pregnancy, because the surgical treatment of ovarian endometrioma may lead to ovarian parenchyma loss (29,30). In some debates, the surgical treatment of ovarian endometrioma may even appear as a contraindication in patients younger than 40 years old. However, some ovarian endometriomas should be operated in order to exclude malignancy, reduce the endometriosis progression, avoid the risk of pelvic abscess (31), and alleviate pain symptoms related to the disease. The oxidative stress induced by the endometrioma may affect the normal ovarian cortex surrounding endometriotic tissues (32) and the rate of spontaneous ovulation is negatively affected by the presence of endometriotic ovarian cysts (33). Therefore, in addition to some clinical problems related to the endometrioma which are often not effectively solved with a medical treatment, we still have to assess the consequences of a non-surgical management of large ovarian endometriomas. To the best of our knowledge, these consequences have never been evaluated. A careful evaluation of this “cautious” approach would be necessary before we can propose it as a standard of care in young patients. Whenever laparoscopic cystectomy for ovarian endometrioma is indicated, it requires a microsurgical dissection instead of the classical stripping

technique. The cleavage plane is almost always difficult in the deep aspect (Area 3 on Figure 7) of the endometrioma because of the fibrosis induced by the disease (24). In this step of the procedure, the knowledge about the “arrows” helps the surgeon to find the correct cleavage plane, minimizing the bleeding and, consequently, the need for coagulation to ovarian hemostasis. The simple stripping technique seems not to be a tissue-sparing procedure and the use of an inadequate surgical technique may tear ovarian vessels and induce significant ovarian damage. In experienced hands, laparoscopic cystectomy for ovarian endometriomas using the principles of microsurgery does not reduce the number of oocytes and embryos obtained during IVF cycles after the procedure (24). Therefore, the level of expertise in endometriosis surgery is inversely correlated with the amount of ovarian tissue inadvertently removed with the endometrioma wall (34). Fortunately, young surgeons are able to learn how to perform the surgery for endometrioma. In a completed but unpublished study conducted in our department (Clermont-Ferrand), we observed that specimens obtained by second year fellows had significantly less normal ovarian tissue than those obtained by first year fellows. The surgical technique is essential, but it is useless without optimal intraoperative indications. After a large biopsy required for a reliable pathologic diagnosis, the surgeon should be able to decide:

- to do only a drainage and a biopsy of the cyst wall when the differential diagnosis between an endometrioma and a functional cyst is doubtful;
- to stop the cystectomy when the dissection is too difficult, when the plane cannot be found, or when the difficult step of the dissection represents more than 90% of the surface of the cyst wall;
- to accept the ablation with CO₂ laser, plasmajet, or short application of bipolar coagulation into the last part of the cyst wall (16,35) whenever the dissection close to the ovarian hilum appears too tedious to be safe for the ovarian vessels. One should obviously prefer a partial treatment of the cyst wall than a possible destruction of the ovary after a severe ovarian hemorrhage.

The current surgical alternatives for ovarian cystectomy are either expensive and not available everywhere (CO₂ laser, plasmajet) or not satisfactory. Indeed, ablation of the cyst wall with bipolar coagulation is difficult since it is not possible to control the depth of destruction from the appearance of the tissue during the procedure. Moreover, it has been previously shown in prospective trials that ablation is less effective than cystectomy (23). Therefore, this technique should be reserved to small cysts and/or to small parts of the cyst wall. Prospective trials comparing cystectomy with CO₂ laser and/or plasmajet management would be interesting. Intraoperative decision-making is essential. A skilled surgeon using the most sophisticated surgical technique in a wrong indication cannot achieve a good treatment! Intraoperative management should always be careful. A three-step procedure (surgery - medical treatment - reintervention) proposed by Donnez *et al* (36) should be

considered in cases of large endometriomas, even knowing that preoperative medical treatment may be a risk factor for removal of normal ovarian tissue during ovarian cystectomy (37). However, surgeons should remember from the results of Donnez *et al* (36) that drainage with or without medical treatment is not an effective treatment of large cysts, so that a second surgical procedure will be often necessary in the management of cysts larger than 6 cm, even when the patients will be subsequently included in an ART program.

Similarly, the treatment of rectal endometriosis is still a matter of numerous debates. Incomplete resection of the disease carries an increased risk of recurrence and generally does not achieve benefits in terms of long-term pain relief, whereas radical interventions carry the risk of major complications (ureteral and rectal injuries with associated sequelae) (5). Some authors advocate a more radical approach involving routine segmental rectal resection (7,15,38-40) whereas others (10,11,28,41), us included (13,27), prefer a more conservative management, with partial or complete excision of the endometriotic lesion without rectal resection, when feasible. In a retrospective study conducted in our department (27), we compared both the standard and the reverse techniques for the treatment of rectovaginal endometriosis and the latter was associated with a decreased rate of major postoperative complications. In our experience, the mobilization of the endometriotic nodule from the uterus and the posterior vaginal fornix before the treatment of the rectal involvement allows for better exposure of the nodule during the most difficult and dangerous step of the surgery. The improved exposure allows a more reliable excision. Again, the “arrows” appear between the endometriotic nodule and the normal tissue, showing the place to be cut, and allowing to decide between shaving and rectal resection with the best anatomical data. Thereafter, the choice of which type of surgery (radical or conservative, standard or reverse technique) is going to be performed will depend on the age of the patients, degree of symptoms, and wishes of the patient². However, the decision is not only between a radical approach for skilled surgeons and a more conservative management for timid and/or less trained surgeons. Indeed, a complete treatment is not necessarily achieved whenever a rectal resection is performed. Meuleman *et al* (42) reported that the prevalence of resection specimens with margins that were histologically positive for endometriosis was only reported in 33% (6/18) of the studies. After bowel resection anastomosis, margins positive for endometriosis were observed in 25/127 patients (19.7%). Moreover, when bowel resection margins are negative it does not mean that excision of the disease on the uterus, the vagina or in the cardinal ligament was complete. Recently, we have demonstrated that vaginectomy is required in more than 80% of the cases of posterior cul-de-sac nodules larger than 2 cm to achieve a complete treatment of the disease (43). Surprisingly, the rate of full thickness vaginal excision is often not reported in series of colorectal resection. In some series the rate is very low, probably demonstrating that surgeons tried to avoid the vaginal incision in order to try to decrease the risk of postoperative complications. As most patients mainly

complain about gynecological symptoms, a more radical management of bowel implants is not obviously the best approach. In this way it is interesting to know that Fauconnier *et al* (44) reported that painful defecation during menstruation was higher when DIE involved the vagina. Similarly, a complete treatment of the vagina is more likely to improve deep dyspareunia. In contrast, two studies demonstrated that rectal shaving is not always a complete treatment. Remorgida *et al* (45) found endometriosis in the bowel wall adjacent to the site of the nodule shaving in 7 out of 16 cases (43.8%). However, these patients were selected as the authors anticipated that a bowel resection was necessary and probably represent a group in which the risk of bowel resection was very high. In this way, most groups who are using the shaving technique for deep rectal disease also treat about 10% of their patients with a rectal resection. The technique of nodulectomy is very likely biased when it is performed immediately before a bowel resection. Several techniques of shaving may be used: some are looking for normal tissue accepting a higher risk of full thickness bowel excision, whereas Donnez *et al* (41) do not excise the fibrotic tissue found around the nodule. Interestingly, as hypothesized by Donnez *et al* (41), the abnormal tissue found by Remorgida *et al* (45) in the bowel wall around the nodule was fibrotic in most cases. In contrast, Roman *et al* (46) found that among 27 women with deep rectal endometriosis managed by segmental resection, in 89% of cases active glandular endometrial foci were responsible for a deeper infiltration of rectal layers than that of fibrosis and smooth fibers by 5 mm on average. This interesting result has to be confirmed. It is somewhat difficult to understand when accounting for most hypothesis about the natural history of the disease. Indeed, active glandular tissue is almost always surrounded by fibrosis or muscular tissue and such lesions should be often visible at colonoscopy whereas this evaluation is normal in most cases. Finally, the recurrence rate observed by those who use a shaving approach is not more than 80%, as it would be if all these submucosal epithelial implants were active and progressive. Currently, we propose a management based mainly on clinical symptoms (28). We use a “conservative” shaving accepting to leave some fibrotic tissue in the rectal wall of patients who mainly complain of gynecological symptoms. Whereas we use an aggressive shaving looking for normal tissue around the nodule in patients with severe digestive symptoms, thus accepting a high risk (up to 30%) of rectal resection. Even with this approach most patients are treated by shaving only. The main argument against a routine rectal resection in these patients comes from general surgeons who reported an anterior resection syndrome to describe the functional symptoms that may be observed after a low rectal resection. Recently, Roman *et al* (11) reported similar findings after rectal resection for bowel endometriosis, strongly suggesting that rectal resection may have its own postoperative morbidity which should be taken into account when choosing a radical approach. Obviously this postoperative syndrome depends on the length of the resected bowel segment and on the distance between the anastomosis and the coloanal junction. This debate will end with the publication of prospective randomized studies comparing shaving and rectal resection for the treatment of

rectal endometriotic nodules larger than 2 cm. Both early and long-term postoperative results will have to be evaluated.

A nerve sparing procedure was recently developed and promoted following the pioneer work of Possover *et al* (47). This approach is actually important as many patients may develop postoperative bladder dysfunction following rectal resection for deep endometriosis. Similar complications are encountered by general surgeons when treating rectal cancer. However, they demonstrated that it is possible to accomplish a total mesorectal excision while preserving autonomic nerves. Careful studies of the rectal anatomy demonstrated that a plane can be identified in between the fascia propria which surrounds the rectum and the parietal fascia in which the autonomic nerves of the pelvic organs are embedded (48,49). The plane between these two fascia was described as the “holy” plane by Heald in 1988 (50).

Obviously, when treating a benign disease like rectal endometriosis, a total mesorectal excision is not mandatory for all patients. Therefore, the surgeons should stay as close to the rectal as possible to minimize the consequences of this surgery. As a matter of fact the situation is often more complex when the disease involves the pararectal area and the utero-sacral ligaments. Indeed, lateral extensions of the nodules may involve the hypogastric and even the splanchnic nerves. In such cases a nerve sparing technique is also a disease sparing technique. Fortunately, the lateral extension of the disease is often asymmetric allowing the surgeon to preserve the nerves on one side of the pelvis. The retractions and anatomical distortions often induced by the disease obviously explain why unnecessary damages may be induced to autonomic nerves. To avoid it two approaches may be used. First, identification of the nerves can be achieved in a normal anatomical area posterior and lateral to the rectum. The nerves are then dissected up to the nodule and preserved whenever possible. This “anatomical” approach involves a complete dissection of the pelvis and of the nerves, great care should be taken to avoid damage of these tiny structures when using bipolar or monopolar coagulation. Second, the limits of the disease are identified and followed as precisely as possible using surgical signs described above. The surgeon should stay close to the disease, not excise the normal tissue around the nodule, and proceed the dissection as close to the rectum as possible, in order to preserve the nerves whenever possible. In this approach, great care should be taken to stay close to the disease. Often the initial steps of the excision require a posterior and lateral approaches. During this step, the identified planes are far from the rectal wall even beyond the fascia propria. If all the procedure is performed in these planes, autonomic nerves are damaged. In contrast, after identifying the posterior and lateral limits of the disease it is often possible, while following the limits of the disease and achieving a complete excision of it, to work closer to the rectal wall even inside the fascia propria. Therefore it is essential when dissecting the rectum below the nodule to be close to the rectal wall in the plane used by rectal surgeons when they are treating benign diseases. We generally use

the second approach. Indeed, as some of these patients will have to be reoperated because of recurrent pain, and as identification of the limits of the disease and of normal anatomical structures including autonomic nerves is much more difficult in the postoperative fibrosis, we do think that unnecessary dissections should be avoided whenever possible.

In the same way, the ureters should be routinely identified but not systematically dissected. The ureteral dissection should be performed whenever the disease is located in the broad ligament and/or infiltrating the utero-sacral ligament. This avoids the risk of ureteral injury during the resection of the deep infiltrating nodules. During the step of ureteral dissection, the “bubbles” show the disease-free tissue to be followed and the “arrows” indicate the fibrotic connections between the pathological and the normal tissue, and they should be cut.

Anyway, no matter the type of surgery to be performed, the surgical principles should be followed to decrease the risk of complications. The surgeon must learn how to perform the laparoscopic treatment of deep infiltrating endometriosis and the patient guides the surgeon indicating the correct planes and boundaries by means of “arrows” and “bubbles”.

7. REFERENCES

1. Olive DL, LB Schwartz. Endometriosis. *N Engl J Med*, 328: 1759-1769 (1993)
2. Koninckx PR, C Meuleman, S Demeyere, E Lesaffre, FJ Cornillie. Suggestive evidence that pelvic endometriosis is a progressive disease, whereas deeply infiltrating endometriosis is associated with pelvic pain. *Fertil Steril* 55: 759-765 (1991)
3. Kwok A, A Lam, R Ford. Deeply infiltrating endometriosis: implications, diagnosis, and management. *Obstet Gynecol Surv* 56: 168-177 (2001)
4. Martin D, G Hubert, B Levy. Depth of infiltration of endometriosis. *J Gynecol Surg* 5: 55-60 (1989)
5. Vercellini P, PG Crosignani, E Somigliana, N Berlanda, G Barbara, L Fedele. Medical treatment for rectovaginal endometriosis: what is the evidence? *Hum Reprod* 24: 2504-2514 (2009)
6. Vercellini P, L Carmignani, T Rubino, G Barbara, A Abbiati, L Fedele. Surgery for deep endometriosis: a pathogenesis-oriented approach. *Gynecol Obstet Invest* 68: 88-103 (2009)
7. Ruffo G, F Scopelliti, M Scioscia, M Ceccaroni, P Mainardi, L Minelli. Laparoscopic colorectal resection for deep infiltrating endometriosis: analysis of 436 cases. *Surg Endosc* 24: 63-67 (2010)
8. Seracchioli R, L Manuzzi, M Mabrouk, S Solfrini, C Frascà, F Manferrari, F Pierangeli, R Paradisi, S Venturoli.

Surgery for deep infiltrating endometriosis

A multidisciplinary, minimally invasive approach for complicated deep infiltrating endometriosis. *Fertil Steril* 93: 1007.e1-3 (2010)

9. Benbara A, A Fortin, B Martin, L Palazzo, A Le Tohic, P Madelenat, C Yazbeck. Surgical and functional results of rectosigmoidal resection for severe endometriosis. *Gynecol Obstet Fertil* 36: 1191-1201 (2008)

10. Maytham GD, HM Dowson, B Levy, A Kent, TA Rockall. Laparoscopic excision of rectovaginal endometriosis: report of a prospective study and review of the literature. *Colorectal Dis* 12: 1105-1112 (2010)

11. Roman H, C Loisel, B Resch, JJ Tuech, P Hochain, AM Leroi, L Marpeau. Delayed functional outcomes associated with surgical management of deep rectovaginal endometriosis with rectal involvement: giving patients an informed choice. *Hum Reprod* 25: 890-899 (2010)

12. Kovoov E, J Nassif, I Miranda-Mendoza, G Lang-Avérous, A Wattiez. Long-term urinary retention after laparoscopic surgery for deep endometriosis. *Fertil Steril* 95: 803.e9-12 (2011)

13. Kondo W, N Bourdel, S Tamburro, D Cavoli, K Jardon, B Rabischong, R Botchorishvili, J Pouly, G Mage, M Canis. Complications after surgery for deeply infiltrating pelvic endometriosis. *BJOG* 118: 292-298 (2011)

14. Kondo W, MT Zomer, L Charles, M Canis. Surgical treatment of deep endometriosis by laparoscopy. In: *Laparoscopy: New Developments, Procedures and Risks*. Eds: Terzic H, Nova Publishers, New York (2011)

15. Dousset B, M Leconte, B Borghese, AE Millischer, G Roseau, S Arkwright, C Chapron. Complete surgery for low rectal endometriosis: long-term results of a 100-case prospective study. *Ann Surg* 251: 887-895 (2010)

16. Bourdel N, Roman H, Mage G, Canis M. Surgery for the management of ovarian endometriomas: From the physiopathology to the pre-, peri- and postoperative treatment. *Gynecol Obstet Fertil* 39: 709-721 (2011)

17. Roman H, I Pura, O Tarta, C Mokdad, M Auber, N Bourdel, L Marpeau, JC Sabourin. Vaporization of ovarian endometrioma using plasma energy: histologic findings of a pilot study. *Fertil Steril* 95: 1853-1856 (2011)

18. Roman H, M Auber, C Mokdad, C Martin, A Diguët, L Marpeau, N Bourdel. Ovarian endometrioma ablation using plasma energy versus cystectomy: a step toward better preservation of the ovarian parenchyma in women wishing to conceive. *Fertil Steril* 96: 1396-1400 (2011)

19. Carmona F, MA Martínez-Zamora, A Rabanal, S Martínez-Román, J Balasch. Ovarian cystectomy versus

laser vaporization in the treatment of ovarian endometriomas: a randomized clinical trial with a five-year follow-up. *Fertil Steril* 96: 251-254 (2011)

20. Shimizu Y, A Takashima, K Takahashi, N Kita, M Fujiwara, T Murakami. Long-term outcome, including pregnancy rate, recurrence rate and ovarian reserve, after laparoscopic laser ablation surgery in infertile women with endometrioma. *Obstet Gynaecol Res* 36: 115-118 (2010)

21. Chapron C, P Vercellini, H Barakat, M Vieira, JB Dubuisson. Management of ovarian endometriomas. *Hum Reprod Update* 8: 591-597 (2002)

22. Saleh A, T Tulandi. Reoperation after laparoscopic treatment of ovarian endometriomas by excision and by fenestration. *Fertil Steril* 72: 322-324 (1999)

23. Hart RJ, M Hickey, P Maouris, W Buckett. Excisional surgery versus ablative surgery for ovarian endometriomata. *Cochrane Database Syst Rev* 16: CD004992 (2008)

24. Canis M, JL Pouly, S Tamburro, G Mage, A Wattiez, MA Bruhat. Ovarian response during IVF-embryo transfer cycles after laparoscopic ovarian cystectomy for endometriotic cysts of >3 cm in diameter. *Hum Reprod* 16: 2583-2586 (2001)

25. Ceccaroni M, R Clarizia, C Alboni, G Ruffo, F Bruni, G Roviglione, M Scioscia, I Peters, G De Placido, L Minelli. Laparoscopic nerve-sparing transperitoneal approach for endometriosis infiltrating the pelvic wall and somatic nerves: anatomical considerations and surgical technique. *Surg Radiol Anat* 32: 601-604 (2010)

26. Kavallaris A, C Banz, N Chalvatzas, A Hornemann, D Luedders, K Diedrich, M Bohlmann. Laparoscopic nerve-sparing surgery of deep infiltrating endometriosis: description of the technique and patients' outcome. *Arch Gynecol Obstet* 284: 131-135 (2011)

27. Kondo W, N Bourdel, K Jardon, S Tamburro, D Cavoli, S Matsuzaki, R Botchorishvili, B Rabischong, JL Pouly, G Mage, M Canis. Comparison between standard and reverse laparoscopic techniques for rectovaginal endometriosis. *Surg Endosc* 25: 2711-2717 (2011)

28. Roman H, M Vassiliev, G Gourcerol, G Savoye, AM Leroi, L Marpeau, F Michot, JJ Tuech. Surgical management of deep infiltrating endometriosis of the rectum: pleading for a symptom-guided approach. *Hum Reprod* 26: 274-281 (2011)

29. Roman H, O Tarta, I Pura, I Opris, N Bourdel, L Marpeau, JC Sabourin. Direct proportional relationship between endometrioma size and ovarian parenchyma inadvertently removed during cystectomy, and its implication on the management of enlarged endometriomas. *Hum Reprod* 25: 1428-1432 (2010)

30. Hirokawa W, A Iwase, M Goto, S Takikawa, Y Nagatomo, T Nakahara, B Bayasula, T Nakamura, S

Surgery for deep infiltrating endometriosis

Manabe, F Kikkawa. The post-operative decline in serum anti-Mullerian hormone correlates with the bilaterality and severity of endometriosis. *Hum Reprod* 26: 904-910 (2011)

31. Somigliana E, P Vercellini, P Viganó, G Ragni, PG Crosignani. Should endometriomas be treated before IVF-ICSI cycles? *Hum Reprod Update* 12: 57-64 (2006)

32. Matsuzaki S, B Schubert. Oxidative stress status in normal ovarian cortex surrounding ovarian endometriosis. *Fertil Steril* 93: 2431-2432 (2010)

33. Benaglia L, E Somigliana, P Vercellini, A Abbiati, G Ragni, L Fedele. Endometriotic ovarian cysts negatively affect the rate of spontaneous ovulation. *Hum Reprod* 24: 2183-2186 (2009)

34. Muzii L, R Marana, R Angioli, A Bianchi, G Cucinella, M Vignali, P Benedetti Panici, M Busacca. Histologic analysis of specimens from laparoscopic endometrioma excision performed by different surgeons: does the surgeon matter? *Fertil Steril* 95: 2116-2119 (2011)

35. Donnez J, JC Lousse, P Jadoul, O Donnez, J Squifflet. Laparoscopic management of endometriomas using a combined technique of excisional (cystectomy) and ablative surgery. *Fertil Steril* 94:28-32 (2010)

36. Donnez J, M Nisolle, N Gillet, M Smets, S Bassil, F Casanas-Roux. Large ovarian endometriomas. *Hum Reprod* 11: 641-646 (1996)

37. Matsuzaki S, C Houle, C Darcha, JL Pouly, G Mage, M Canis. Analysis of risk factors for the removal of normal ovarian tissue during laparoscopic cystectomy for ovarian endometriosis. *Hum Reprod* 24: 1402-1406 (2009)

38. Slack A, T Child, I Lindsey, S Kennedy, C Cunningham, N Mortensen, P Koninckx, E McVeigh. Urological and colorectal complications following surgery for rectovaginal endometriosis. *BJOG* 114: 1278-1282 (2007)

39. Ford J, J English, WA Miles, T Giannopoulos. Pain, quality of life and complications following the radical resection of rectovaginal endometriosis. *BJOG* 111: 353-356 (2004)

40. Bassi MA, S Podgaec, JA Dias Jr, N D'Amico Filho, CA Petta, MS Abrao. Quality of life after segmental resection of the rectosigmoid by laparoscopy in patients with deep infiltrating endometriosis with bowel involvement. *J Minim Invasive Gynecol* 18: 730-733 (2011)

41. Donnez J, J Squifflet. Complications, pregnancy and recurrence in a prospective series of 500 patients operated on by the shaving technique for deep rectovaginal endometriotic nodules. *Hum Reprod* 25: 1949-1958 (2010)

42. Meuleman C, C Tomassetti, A D'Hoore, B Van Cleynenbreugel, F Penninckx, I Vergote, T D'Hooghe. Surgical treatment of deeply infiltrating endometriosis with

colorectal involvement. *Hum Reprod Update* 17: 311-326 (2011)

43. Matsuzaki S, C Houle, R Botchorishvili, JL Pouly, G Mage, M Canis. Excision of the posterior vaginal fornix is necessary to ensure complete resection of rectovaginal endometriotic nodules of more than 2 cm in size. *Fertil Steril* 91: 1314-1315 (2009)

44. Fauconnier A, C Chapron, JB Dubuisson, M Vieira, B Dousset, G Bréart. Relation between pain symptoms and the anatomic location of deep infiltrating endometriosis. *Fertil Steril* 78: 719-726 (2002)

45. Remorgida V, N Ragni, S Ferrero, P Anserini, P Torelli, E Fulcheri. How complete is full thickness disc resection of bowel endometriotic lesions? A prospective surgical and histological study. *Hum Reprod* 20: 2317-2320 (2005)

46. Roman H, I Opris, B Resch, JJ Tuech, JC Sabourin, L Marpeau. Histopathologic features of endometriotic rectal nodules and the implications for management by rectal nodule excision. *Fertil Steril* 92: 1250-1252 (2009)

47. Possover M, J Baekelandt, C Flaskamp, D Li, V Chiantera. Laparoscopic neurolysis of the sacral plexus and the sciatic nerve for extensive endometriosis of the pelvic wall. *Minim Invasive Neurosurg* 50: 33-36 (2007)

48. Enker WE, NJ Kafka, J Martz. Planes of sharp pelvic dissection for primary, locally advanced, or recurrent rectal cancer. *Semin Surg Oncol* 18: 199-206 (2000)

49. Kinugasa Y, G Murakami, D Suzuki, K Sugihara. Histological identification of fascial structures posterolateral to the rectum. *Br J Surg* 94: 620-626 (2007)

50. Heald RJ. The 'Holy Plane' of rectal surgery. *J R Soc Med* 81: 503-508 (1988)

Abbreviations: CO₂: carbon dioxide.

Key Words: Endometriosis, Laparoscopy, Surgery, Deep Infiltrating Endometriosis, Review

Send correspondence to: William Kondo, Department of Gynecologic Surgery, CHU Estaing, 1 Place Lucie Aubrac, 63003 Clermont-Ferrand, Cedex 1, France, Tel: 33-0473750750, Fax: 33-0473931706, E-mail: williamkondo@yahoo.com