

Original Research

Intrapartum Ultrasound in Maternal Lateral Position. A Prospective Observational Study

Marcos Javier Cuerva^{1,*†}, Elena Rodriguez^{1,†}, Francisco Lopez¹, José Luis Bartha¹¹Obstetric Department, Hospital Universitario La Paz, 28046 Madrid, Spain*Correspondence: marxichos@hotmail.com (Marcos Javier Cuerva)

†These authors contributed equally.

Academic Editor: José Antonio Sainz Bueno

Submitted: 19 March 2022 Revised: 2 June 2022 Accepted: 13 June 2022 Published: 26 August 2022

Abstract

Background: Intrapartum ultrasound (ITU) techniques have been described only in maternal semi-recumbent position. However, other birthing positions, such as side-lying, are more comfortable for many mothers. The present study aimed to test the hypothesis that ITU measurements can be obtained in maternal lateral positions during the second stage of labor. **Methods:** A single-center, prospective observational study was conducted. Women who preferred a side-lying position during the second stage of labor participated in the study. The women were asked to grasp their upper knee and flex it to perform the ultrasound scan. The transducer was first placed in the frontal plane and then rotated to the midsagittal plane (the probe was placed at the level of the fourchette). **Results:** 34 women participated in the study. Position of the fetal head, angle of progression, and head-perineum distance with and without contraction were obtained in all women. There was a moderate correlation between the head-perineum distance with contraction and the ITU to birth time ($r = 0.466$; $p = 0.009$). **Conclusions:** ITU in maternal lateral position (side-lying) is a simple technique that avoids unnecessary changing of position during the second stage of labor.

Keywords: intrapartum ultrasound; childbirth; labor; lateral position

1. Introduction

Obstetrics has developed from the digital examination of the birth canal and fetal presentation [1]. However, digital vaginal examination is neither a highly reproducible nor reliable technique to determine the fetal head station or position [2,3]. In addition, digital vaginal examinations are poorly tolerated [4,5].

Given the poor reliability and pain of digital vaginal examination, the alternative of using intrapartum ultrasound (ITU) for measuring fetal head station, fetal head position, caput, and molding in a sonopartogram has been suggested [6]. The most used ultrasound measurements for the fetal head station are the angle of progression (AOP) and the head-perineum distance (HPD). The AOP is the angle between the long axis of the pubic bone and a line from the anterior edge of the pubis drawn tangential to the deepest bony part of the fetal skull in the birth canal [7]. The HPD is the shortest distance from the outer bony limit of the fetal skull to the perineum [8]. Both measurements are performed transperineally [9].

The position of the fetal head can be determined by both transperineal and transabdominal ultrasound. The fetal head position is classified based on the position of the fetal occiput. In transperineal ultrasound, the observation of the choroid plexuses reveals where the occiput is located. In transabdominal ultrasound, the position of the fetal head will be evaluated based on the observation of the orbits, the cerebellum, or the interhemispheric line [9].

So far, ITU techniques have been described only in semi-recumbent position [9]. However, in women with epidurals, flexible sacrum birthing positions, compared to semi-recumbent position, have resulted in a shorter second stage of labor and may be more comfortable for many mothers [10,11]. Additionally, lateral birthing positions have been associated with a higher rate of intact postpartum perineum and a lower rate of episiotomies [12].

No study so far has evaluated a maternal position other than semi-recumbent when performing ITU. The aim of the present study was to test the hypothesis that ITU measurements can be obtained in maternal lateral positions during the second stage of labor.

2. Materials and Methods

2.1 Study Design

A single-center, prospective observational study was conducted. Eligible pregnant women were monitored in the birthing unit. They all gave informed consent. The eligible women met the following inclusion criteria: (1) women who preferred a side-lying position in the second stage of labor; (2) low-risk singleton pregnancies at term; (3) ruptured membranes; (4) older than 18 years; (5) adequate epidural anesthesia with a standardized continuous-infusion technique; (6) no previous cesarean birth.



The study was performed in the birthing unit. The managing midwives reported when the women were in the second stage of labor. The ultrasound was performed with the women in a side-lying position with an empty bladder.

Clinical characteristics, including maternal age, height, body mass index (BMI), gestational age, obstetric history, time to birth, method of birth, neonatal weight, Apgar score at 1 and 5 minutes, and umbilical artery pH value, were recorded.

2.2 Intrapartum Ultrasound

To perform the ITU, the women were asked to grasp their upper knee and flex it (Fig. 1). The transducer was first placed in the frontal plane and then rotated to the midsagittal plane (the probe was placed at the level of the fourchette).

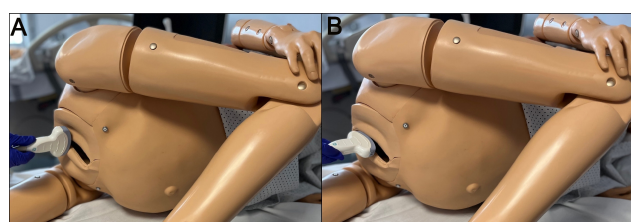


Fig. 1. Maternal lateral position and placement of the probe. (A) Transducer placed in the frontal plane. (B) Transducer placed in the midsagittal plane.

First, the fetal head position was determined by observing the choroid plexus, which diverges toward the occiput. Classification of the position of the fetal head was made based on the position of the occiput as if it were the hour hand on a clock face. Positions $\geq 02:30$ and $\leq 03:30$ were recorded as left occiput transverse (LOT) and positions $\geq 08:30$ and $\leq 09:30$ as right occiput transverse (ROT). Positions $> 03:30$ and $< 08:30$ were recorded as occiput posterior (OP) and positions $> 09:30$ and $< 02:30$ were recorded as occiput anterior (OA). The OA and OP positions were subdivided into left, right, or direct.

Secondly, the measurement of the AOP in the midsagittal plane was performed. Small lateral and anteroposterior movements of the probe were required for obtaining a clear sagittal view with clear maternal pelvic (pubic symphysis) and fetal (fetal skull) landmarks. The AOP was measured as the angle between the long axis of the pubic bone and a line from the anterior border of the pubis drawn tangentially to the deepest bony part of the fetal skull (Fig. 2).

Thirdly, back to the frontal plane, the HPD was measured. The HPD was measured as the shortest distance from the outer bony limit of the fetal skull to the perineum (Fig. 2).

ITU measurements were performed between contractions (AOP1 and HPD1) and with contraction (AOP2 and HPD2). The difference between AOP1 and AOP2 (dAOP), and HPD1 and HPD2 (dHPD) were calculated. A

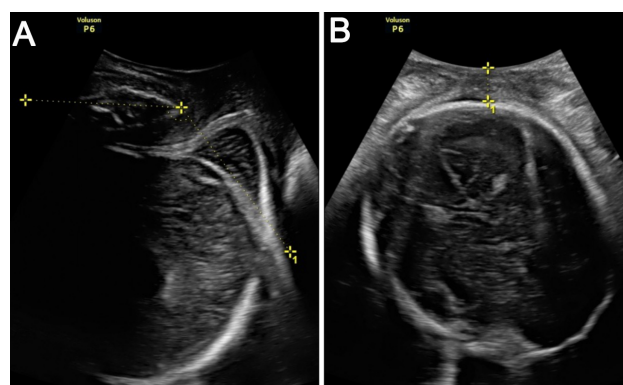


Fig. 2. ITU measurements in maternal lateral position. (A) Measurement of the AOP in the midsagittal plane (the AOP is the angle between the long axis of the pubic bone and a line from the anterior edge of the pubis drawn tangential to the deepest bony part of the fetal skull). (B) Measurement of the HPD in the frontal plane (the HPD is the shortest distance from the outer bony limit of the fetal skull to the perineum).

curved array transducer (GE Voluson P6, General Electric, Chicago, IL, USA) was used. The ITU images followed the previously published recommendations except for the maternal position [9].

2.3 Statistical Analysis

The sample size calculation was performed to show that in at least 80% of women, it is possible to acquire ITU measurements in a maternal lateral position. Using an alpha value of 0.05 and a power ($1 - \beta$) of 80% and considering that digital vaginal examination can be performed in 100% of women, 34 examinations were needed.

The distribution of the variables was verified by the Kolmogorov-Smirnov test and by visual assessment of histograms. Numerical variables were expressed as mean (standard deviation) or median (interquartile range, IQR) as appropriate and qualitative variables were expressed as proportions (absolute and relative frequencies).

Correlations between AOP and HPD in maternal lateral positions and between ITU parameters and time to birth were analyzed using the Pearson correlation coefficient (r).

The level of significance was set at 95% ($p < 0.05$). All analyses were performed in SPSS version 22.0 (SPSS Inc., Chicago, IL, USA).

3. Results

A total of 34 women participated in the study. None refused to participate in the study. ITU was performed, and position of the fetal head, AOP, and HPD in maternal lateral position with and without contraction were obtained in all women (100%) (Table 1).

Table 1. ITU Data.

	N = 34
AOP1 (°)	142.2 (±12.2)
AOP2 (°)	151.8 (±12.8)
dAOP (°)	9.6 (±4.8)
HPD1 (mm)	19.4 (±7.3)
HPD2 (mm)	13.8 (±6.2)
dHPD (mm)	5.6 (±4.3)
dOA	11 (32.4%)
LOA	6 (17.6%)
ROA	2 (5.9%)
LOT	8 (23.5%)
ROT	3 (8.8%)
LOP	2 (5.9%)
ROP	2 (5.9%)

Data are presented as means ± (standard deviations) for normally distributed continuous variables and as absolute and relative frequencies for qualitative variables. dOA, direct occiput anterior; LOA, left occiput anterior; ROA, right occiput anterior; LOT, left occiput transverse; ROT, right occiput transverse; LOP, left occiput posterior; ROP, right occiput posterior.

Maternal age was 34.00 (31.75 to 36) years, and BMI was 23.95 (±3.58) kg/m². There were 23 (67.6%) nulliparous and 11 (32.4%) parous women. The ITU to birth time was 90.91 (±43.47) minutes. No baby was admitted to the NICU (Table 2).

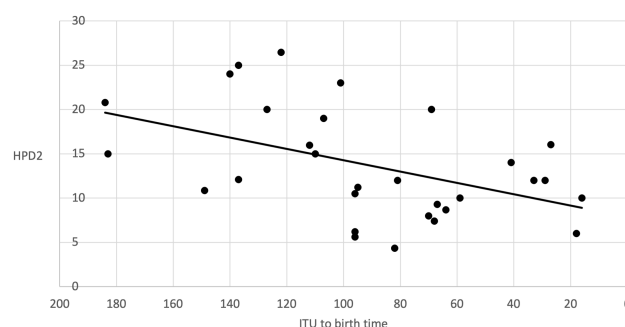
Table 2. Demographic and birth data.

	N = 34
Maternal age	34.00 (31.75 to 36)
GA	39.97 (±1.2)
BMI (kg/m ²)	23.95 (±3.58)
Height (m)	1.65 (±0.06)
European/American/Asian	30 (88.2%)/3 (8.8%)/1 (2.9%)
Nulliparous	23 (67.6%)
ITU to Birth time (min.)	90.91 (±43.47)
Weight (g)	3203 (±363)
Apgar 0'	9 (9 to 9)
Apgar 5'	10 (9 to 10)
Umb. Art. pH	7.29 (±0.07)
Instrumental	9 (26.5%)
Cesarean	1 (2.9%)

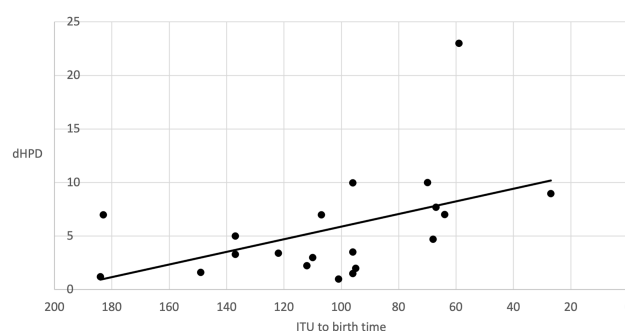
Data are presented as means ± (standard deviations) for normally distributed continuous variables, medians (interquartile range) for not normally distributed continuous variables, and absolute and relative frequencies for qualitative variables. BMI, Body Mass Index; GA, Gestational age; Umb. Art. pH, Umbilical artery pH.

There were 9 instrumental births and 1 cesarean birth. The cesarean and 3 instrumental births were indicated due to non-reassuring CTG. The other 6 instrumental births were due to prolonged second stage of labor.

To analyze the time from ITU to birth in correlation with ultrasound measurements, only births with reassuring CTG were used. ITU to birth time was shorter in parous women (61.56 ± 46.30 versus 104.43 ± 39.38 minutes; $p = 0.030$). There was a moderate correlation between HPD2 and ITU to birth time ($r = 0.466$; $p = 0.009$) (Fig. 3). This correlation remained significant after adjusting for confounders using an analysis of covariance.

**Fig. 3. HPD2 and ITU to birth time.** Correlation between HPD2 and ITU to birth time ($r = 0.466$; $p = 0.009$).

There was also a moderate correlation between dHPD and ITU to birth time in nulliparous women ($r = -0.473$; $p = 0.035$) (Fig. 4). The rest of correlations between sonographic measurements and ITU to birth time were not statistically significant.

**Fig. 4. dHPD and ITU to birth time in nulliparous women.** Correlation between dHPD and ITU to birth time in nulliparous women ($r = -0.473$; $p = 0.035$).

There was a very high correlation between AOP and HPD with and without contraction ($r = -0.816$; $p < 0.001$) (Fig. 5).

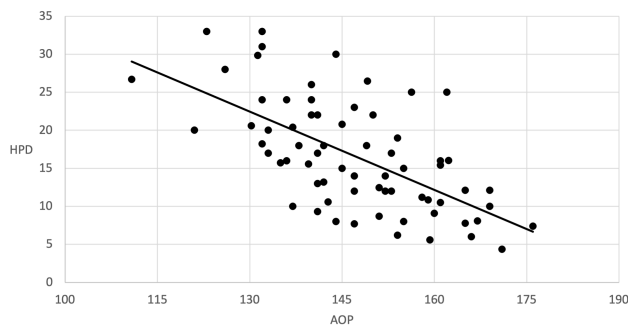


Fig. 5. AOP and HPD in maternal lateral position. Correlation between AOP and HPD ($r = -0.816$; $p < 0.001$).

4. Discussion

Our results show that performing ITU in maternal side-lying positions is possible in women during the second stage of labor. This practice can lead to greater comfort for women by avoiding unnecessary changes in their position to perform labor progress examinations during the second stage of labor.

In the second stage of labor, multiple digital vaginal examinations are often performed to assess the descent and rotation of the fetal head [13]. It is known that a high number of vaginal exams can increase adverse events such as chorioamnionitis or febrile morbidity [14,15]. ITU makes it possible to observe labor progression in a less invasive and better-tolerated way [4]. In our study, it was possible to obtain ultrasound measurements to assess the progression and position of the fetal head in 100% of the women. None refused to participate in the study, which showed not only the high capacity to obtain information, but the high acceptability by women of intrapartum ultrasound.

Regarding maternal lateral positions in childbirth, multiple benefits have been reported, especially in terms of a lower rate of perineal tears [10,12]. Although it is widely accepted that women have to be free to decide in which position they feel most comfortable during childbirth, obstetricians and midwives are not trained to perform vaginal examinations in positions other than semi-recumbent [11,16,17]. Currently, many women must modify their position to perform examinations during childbirth, which could be avoided using ITU techniques. In our study, we were able to assess AOP, HPD, and fetal head position in all women. But in the event that it is not possible to determine the AOP or HPD in a woman, given the high correlation between both measurements, obtaining one of them would be sufficient to have reproducible and reliable information.

It is known that the AOP and HPD measured in semi-recumbent position by ITU at the beginning of the second stage of labor can predict spontaneous vaginal birth, although no cut-off values have been established for these predictors [18]. Our study was not designed to show whether the values of the ITU measurements in lateral po-

sitions were a predictor of vaginal birth. Still, we found a moderate correlation between HPD2 and ITU to birth time in women with a reassuring CTG and between dHPD and ITU to birth time in nulliparous women. This correlation between ITU measurements and time to birth leads us to believe that through determinations of ITU measurements in maternal lateral positions, the progress of labor can be monitored in the same way that can be performed in semi-recumbent position [9].

With regard to maternal positions, not only during the second stage of labor but also during the first stage, women should be encouraged to adopt the positions in which they are most comfortable [19]. Position changes can favor labor progression and be helpful in non-reassuring cardiotocographic monitoring [20]. Using ITU, it might be possible to monitor labor progress regardless of the maternal position. Therefore, we believe that it would be appropriate to study intrapartum ultrasound in other maternal positions and the relationship between ultrasound measurements in various positions and at different stages of labor.

In case that ITU became the standard clinical practice, it is possible that the rate of vaginal examinations, failed instruments, and even the rate of cesarean births could be reduced by studying the progression of labor with greater accuracy. So far, studies have failed to show these benefits, but no harm has been found either [18,21–23]. In addition, it is an examination that is well accepted, harmless, and without contraindications [9].

Our study is the first to describe the ITU technique in maternal side-lying position. The main strength of our study is that it was conducted on women during the second stage of labor and that it evaluated consecutive women regardless of height and weight. Another strength of the study is having studied the time until birth since it allows showing the relation between the ITU measurements and the birth progress.

The main weakness of our study is the lack of inter-observer verification of ITU measurements. Even knowing that sonographic measures are highly reproducible and reliable [24], it would have been convenient if two independent operators had performed them. Another weakness is the small sample size; since it was calculated only to show if obtaining ITU measurements in maternal lateral position was possible, it does not allow reaching other conclusions regarding perinatal outcomes.

5. Conclusions

ITU in maternal lateral position (side-lying) is a simple technique that avoids unnecessary changing of position during the second stage of labor. Our study shows that this technique obtains results for measurements of the AOP and HPD in addition to fetal head position in more than 80% of cases. In fact, we obtained these results in all the women who participated in the study. We believe that more studies are necessary and that ITU could probably end up being a

valuable tool in any maternal position.

Author Contributions

MJC designed the research study. MJC and ER performed the research. FL and JLB provided assistance and advice on methodology. MJC and JLB analyzed the data. MJC and FL wrote the manuscript. JLB supervised all the research. All authors contributed to editorial changes in the manuscript. All authors read and approved the final manuscript.

Ethics Approval and Consent to Participate

Ethical clearance was obtained from the institutional Ethics Committee (PI-4853). Informed consent was obtained from all participants in the study.

Acknowledgment

Thanks to the women who participated in the study.

Thanks to S Franke and M Cruset for English proof-reading.

Funding

This research received no external funding.

Conflict of Interest

The authors declare no conflict of interest.

References

- [1] Feltovich H. Cervical Evaluation: From Ancient Medicine to Precision Medicine. *Obstetrics and Gynecology*. 2017; 130: 51–63.
- [2] Dupuis O, Silveira R, Zentner A, Dittmar A, Gaucherand P, Cucherat M, *et al.* Birth simulator: reliability of transvaginal assessment of fetal head station as defined by the American College of Obstetricians and Gynecologists classification. *American Journal of Obstetrics and Gynecology*. 2005; 192: 868–874.
- [3] Sherer DM, Miodovnik M, Bradley KS, Langer O. Intrapartum fetal head position II: comparison between transvaginal digital examination and transabdominal ultrasound assessment during the second stage of labor. *Ultrasound in Obstetrics and Gynecology*. 2002; 19: 264–268.
- [4] Seval MM, Yuce T, Kalafat E, Duman B, Aker SS, Kumbasar H, *et al.* Comparison of effects of digital vaginal examination with transperineal ultrasound during labor on pain and anxiety levels: a randomized controlled trial. *Ultrasound in Obstetrics and Gynecology*. 2016; 48: 695–700.
- [5] Chan YT, Ng KS, Yung WK, Lo TK, Lau WL, Leung WC. Is intrapartum translabial ultrasound examination painless? *The Journal of Maternal-Fetal & Neonatal Medicine*. 2016; 29: 3276–3280.
- [6] Hassan WA, Eggebo T, Ferguson M, Gillett A, Studd J, Pasupathy D, *et al.* The sonopartogram: a novel method for recording progress of labor by ultrasound. *Ultrasound in Obstetrics and Gynecology*. 2014; 43: 189–194.
- [7] Barbera AF, Pombar X, Perugino G, Lezotte DC, Hobbins JC. A new method to assess fetal head descent in labor with transperineal ultrasound. *Ultrasound in Obstetrics and Gynecology*. 2009; 33: 313–319.
- [8] Eggebo TM, Gjessing LK, Heien C, Smedvig E, Økland I, Romundstad P, *et al.* Prediction of labor and delivery by transperineal ultrasound in pregnancies with prelabor rupture of membranes at term. *Ultrasound in Obstetrics and Gynecology*. 2006; 27: 387–391.
- [9] Ghi T, Eggebo T, Lees C, Kalache K, Rozenberg P, Youssef A, *et al.* ISUOG Practice Guidelines: intrapartum ultrasound. *Ultrasound in Obstetrics and Gynecology*. 2018; 52: 128–139.
- [10] Berta M, Lindgren H, Christensson K, Mekonnen S, Adefris M. Effect of maternal birth positions on duration of second stage of labor: systematic review and meta-analysis. *BMC Pregnancy and Childbirth*. 2019; 19: 466.
- [11] Walker KF, Kibuka M, Thornton JG, Jones NW. Maternal position in the second stage of labour for women with epidural anaesthesia. *The Cochrane Database of Systematic Reviews*. 2018; 11: CD008070.
- [12] Walker C, Rodríguez T, Herranz A, Espinosa JA, Sánchez E, Espuña-Pons M. Alternative model of birth to reduce the risk of assisted vaginal delivery and perineal trauma. *International Urogynecology Journal*. 2012; 23: 1249–1256.
- [13] Borders N, Lawton R, Martin SR. A Clinical Audit of the Number of Vaginal Examinations in Labor: a NOVEL Idea. *Journal of Midwifery and Women's Health*. 2012; 57: 139–144.
- [14] Gluck O, Mizrahi Y, Ganer Herman H, Bar J, Kovo M, Weiner E. The correlation between the number of vaginal examinations during active labor and febrile morbidity, a retrospective cohort study. *BMC Pregnancy and Childbirth*. 2020; 20: 246.
- [15] Cahill AG, Duffy CR, Odibo AO, Roehl KA, Zhao Q, Macones GA. Number of Cervical Examinations and Risk of Intrapartum Maternal Fever. *Obstetrics and Gynecology*. 2012; 119: 1096–1101.
- [16] Gupta JK, Sood A, Hofmeyr GJ, Vogel JP. Position in the second stage of labour for women without epidural anaesthesia. *The Cochrane Database of Systematic Reviews*. 2017; 5: CD002006.
- [17] Breitkopf DM. Lateral decubitus position to facilitate pelvic examination of the patient with severe obesity. *BMC Women's Health*. 2021; 21: 143.
- [18] Nassr AA, Berghella V, Hessami K, Bibbo C, Bellussi F, Robinson JN, *et al.* Intrapartum ultrasound measurement of angle of progression at the onset of the second stage of labor for prediction of spontaneous vaginal delivery in term singleton pregnancies: a systematic review and meta-analysis. *American Journal of Obstetrics and Gynecology*. 2022; 226: 205–214.e2.
- [19] Alhafez L, Berghella V. Evidence-based labor management: first stage of labor (part 3). *American Journal of Obstetrics and Gynecology MFM*. 2020; 2: 100185.
- [20] Kibuka M, Price A, Onakpoya I, Tierney S, Clarke M. Evaluating the effects of maternal positions in childbirth: an overview of Cochrane Systematic Reviews. *European Journal of Midwifery*. 2021; 5: 57.
- [21] Mappa I, Tartaglia S, Maqina P, Makatsariya A, Ghi T, Rizzo G, *et al.* Ultrasound vs routine care before instrumental vaginal delivery: a systematic review and meta-analysis. *Acta Obstetrica Et Gynecologica Scandinavica*. 2021; 100: 1941–1948.
- [22] Tao H, Wang R, Liu W, Zhao Y, Zou L. The value of intrapartum ultrasound in the prediction of persistent occiput posterior position: Systematic review and meta-analysis. *European Journal of Obstetrics and Gynecology and Reproductive Biology*. 2019; 238: 25–32.
- [23] Ramphul M, Ooi P, Burke G, Kennelly M, Said S, Montgomery A, *et al.* Instrumental delivery and ultrasound: a multicentre randomised controlled trial of ultrasound assessment of the fetal head position versus standard care as an approach to prevent morbidity at instrumental delivery. *BJOG: an International Journal of Obstetrics and Gynaecology*. 2014; 121: 1029–1038.
- [24] Molina FS, Terra R, Carrillo MP, Puertas A, Nicolaidis KH. What is the most reliable ultrasound parameter for assessment of fetal head descent? *Ultrasound in Obstetrics & Gynecology*. 2010; 36: 493–499.