

# Postpartum hemorrhage and prolonged hyperfibrinolysis as complications of uterine cavernous hemangioma: a case report and literature review

Xue-Li Bai<sup>1</sup>, Xia Cao<sup>1,\*</sup>

<sup>1</sup>Department of Gynecology, The Fourth Affiliated Hospital of China Medical University, 110004 Shenyang, Liaoning, China

\*Correspondence: [cmu4h\\_cx@126.com](mailto:cmu4h_cx@126.com) (Xia Cao)

DOI: [10.31083/j.ceog4804157](https://doi.org/10.31083/j.ceog4804157)

This is an open access article under the CC BY 4.0 license (<https://creativecommons.org/licenses/by/4.0/>).

Submitted: 13 December 2020 Revised: 7 January 2021 Accepted: 14 January 2021 Published: 15 August 2021

**Background:** Uterine cavernous hemangioma can cause persistent vaginal bleeding or massive hemorrhage and can lead to severe pregnancy complications. **Case:** A 23-year old woman with cutaneous hemangiomas presented for caesarean delivery of her second child nine days after successful delivery, she was admitted with severe postpartum hemorrhage and disseminated intravascular coagulation (DIC). A hysterectomy was performed as a result. The diagnosis of cavernous uterine hemangioma was made only on histopathological examination. In addition, an atypically extended period of refractory fibrinolytic hyperactivity developed after hysterectomy. Such extensive hyperfibrinolysis has not previously been reported in conjunction with hysterectomy. **Conclusion:** This case underscores the importance of cavernous uterine hemangioma as one of the causes of refractory uterine bleeding at the time of operation delivery. The definitive diagnosis can be made only on histological examination. Changes in the coagulation mechanism should be monitored closely during postpartum, and clinicians should be aware of the possibility of fibrinolytic hyperactivity.

## Keywords

Cavernous hemangioma; Postpartum hemorrhage; Hyperfibrinolysis

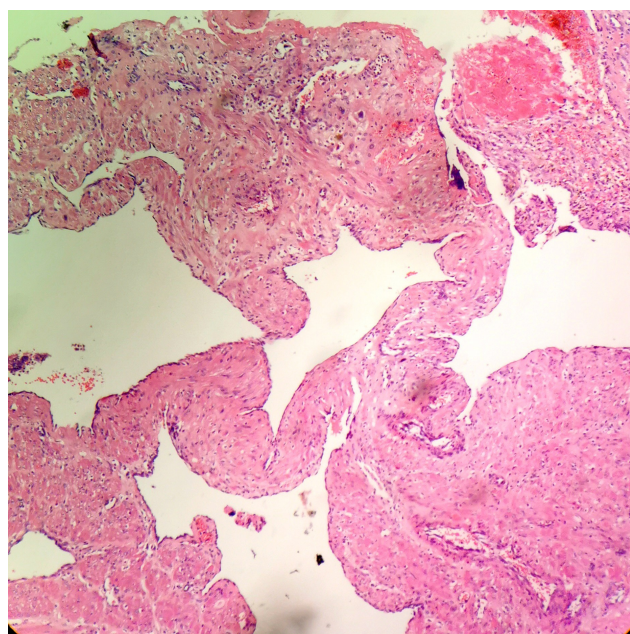
## 1. Introduction

Uterine cavernous hemangioma is a rare, benign tumor that may be due to a congenital vascular malformation or an acquired condition secondary to uterine surgery or other disease, and its exact incidence is unknown [1]. Clinical symptoms range from asymptomatic to excessive vaginal bleeding, anemia, abdominal pain and infertility to maternal pregnancy-associated complications such as massive hemorrhage, disseminated intravascular coagulation (DIC) [2–4]. The antenatal diagnosis may be difficult and requires a high index of suspicion by the radiologist as well as the obstetrician. The definitive diagnosis depends upon the histological examination of the uterus [1]. We report a case of severe postpartum hemorrhage due to a previously undiagnosed uterine cavernous hemangioma in a patient with cutaneous hemangiomas. The patient underwent hysterectomy and experienced prolonged hyperfibrinolysis, which has not previously been reported in conjunction with hysterectomy.

## 2. Case report

A 23 year old female, G2P1, had delivered her first child by caesarean section two years ago. She presented for caesarean delivery of her second child, and physical examination on admission revealed cutaneous hemangiomas in the left lower abdomen, left axilla, left back, and the waist area. All laboratory parameters were within normal limits, and a healthy infant was delivered by caesarean section without complications. On the ninth day after the surgery, the patient was re-hospitalized due to massive vaginal bleeding, estimated at 2000 mL. She presented in hypovolemic shock with blood pressure 80/50 mmHg, heart rate 100 beats per minute, hemoglobin 105 g/L, platelets  $157 \times 10^9/L$ , and fibrinogen 0.29 g/L. The patient was given intramuscular Methergine, IV oxytocin and intrauterine hemabate to promote uterine contraction. Intrauterine gauze packing and uterine artery ligation were taken to stop the bleeding. Disseminated intravascular coagulation (DIC) developed during exploratory laparotomy, the uterine wound continues to ooze blood, so subtotal hysterectomy was performed in order to save the patient's life in the context of the patient's continued blood loss. The cumulative blood loss was 4000 mL. She was given 1600 mL RBC's, 1400 mL Fresh Frozen plasma and 400 u prothrombin complex in total from preoperative to the operation process, and postoperative management. On gross examination, the uterus was about  $12 \times 10 \times 6.5$  cm in size, with numerous  $0.2 \times 0.2$  cm dark red papule-like protrusions at the placental attachment locations. The myometrium was 3 cm thick, with numerous honeycomb-like spaces halfway through the myometrial wall. The boundary was ill-defined, and dark red liquid was expressed. Microscopically, the lesion was composed of unequally sized blood sinuses with uneven thickness of the vascular channel walls. These were filled with blood and thrombosis was observed. The smooth muscle forming the tube wall was partly lined with a single layer of flattened endothelial cells. Neither chorionic villi nor decidual tissue were observed. Immunohistochemistry revealed that the endothelial cells were Factor VIII (+) and proliferating cell nuclear antigen (PCNA) (+). The pathological diag-

nosis was diffuse cavernous uterine hemangioma (Fig. 1). After DIC correction, fibrinogen gradually returned to normal level, we stopped heparin treatment, secondary long-term hyperfibrinolysis was evident. The 3P test was positive; fibrin degradation products (FDP) increased progressively to 27 ug/dL; fibrinogen decreased progressively to 0.78 g/L; and D-dimer values fluctuated between 2580–3900 ug/L. However, hemoglobin and platelet levels gradually returned to normal (Fig. 2). The patient improved with heparin 12.5 mg twice a day, fibrinogen, and epsilon aminocaproic acid for four days. However, stopping the drugs led to recurrent fibrinolysis, so the patient was treated with heparin and hemostatic aromatic acid for eight days, we tried to discontinue heparin on the 8th day after surgery, but failed. Fourteen days after completing this treatment the patient recovered and was discharged, and during the next two years of follow-up, she was completely healthy. The patient has given consent for the publication of the case.



**Fig. 1. Cavernous hemangioma (HE stain, original magnification ×200).** The lesion shows irregularly sized blood sinuses with uneven thickness of the vascular channel walls.

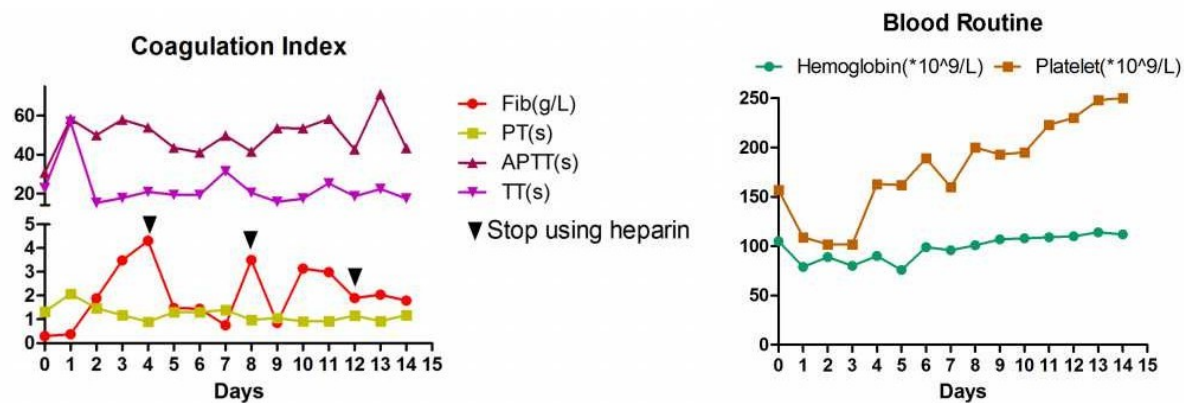
### 3. Discussion

This patient demonstrated a rare case of uterus cavernous hemangiomas. In pathological terms, a uterine hemangioma can be described as a cirroid aneurysm or cavernous hemangioma [5]. Cavernous hemangioma of the uterus can be either congenital or can develop over the course of a lifetime. Congenital cavernous hemangioma is caused by a malformation during the first stage of embryonic vascular development. It is a common vascular tumor lined by benign endothelial cells. It may be associated with hereditary syndromes such as Klippel-Trelawney-Weber or hereditary

hemorrhagic telangiectasia [6]. Sharma *et al.* [7] reported that postnatal development may occur secondarily to curettage, pelvic surgery, endometrial carcinoma, trophoblastic disease, or maternal ingestion of diethylstilbestrol. Some reports describe the affected uterus as having the presence of murmurs, pulsations, or bruits, or being enlarged, soft and “sponge-like” [8], whereas these pathological findings were not present in other cases [9]. Saeed-Vafa *et al.* [10] reported that the tumors present as blue or dark red globular masses with a soft texture. When pressed by hand, the shallow mass shrinks or disappears. When the compression is lifted, the mass returns quickly to its original state, as seen in this case. When stimulated, a cavernous hemangioma can cause inflammatory reactions, local redness, swelling and pain, and even ulceration and bleeding. It can also cause thrombogenesis. Microscopically, the cavernous hemangioma is mainly composed of honeycomb-like vascular cavities of different sizes, with endothelial cells lining the wall and blood inside the cavity.

Uterine cavernous hemangiomas can occur at any age but are most commonly seen in individuals around 30 years old. Irregular vaginal bleeding is a common symptom in clinical settings. Hemangioma of the submucosa or intramural hemangioma of the muscle wall protrudes into the uterine cavity and forms a polypoid shape. If a rupture occurs in either condition, it can cause persistent vaginal bleeding or massive hemorrhage, even shock. Severe pregnancy complications such as postpartum hemorrhage, advanced postpartum hemorrhage, DIC, and thrombosis, have been reported in less than 20 cases worldwide [9, 11–13]. Amniotic fluid embolization may occur due to increased blood vessel cross-sectional area [3], and spontaneous abortion, premature birth and fetal growth restriction have been reported in association with the condition [14, 15]. This patient underwent two cesarean operations. Although congenital factors cannot be excluded in the formation of her uterine hemangioma, secondary factors such as the history of cesarean section and pregnancies seem to be a more probable cause since no hemorrhage occurred during the first cesarean section.

Ultrasound plays a vital role in the diagnosis of cavernous hemangioma of the uterus. Ultrasound findings in this case revealed endometrial polyps or uterine masses similar to fibroids. Alternatively, it may reveal a diffuse mass and dilated vascular spaces replacing the normal myometrium of the uterine wall [16–18]. Enhanced CT and MRI can also aid in the diagnostic process, although their usefulness is limited during the pregnancy. The histopathological examination is the gold standard to confirm the diagnosis. For patients who are not pregnant, the final diagnosis can be confirmed by angiography [18, 19]. Diagnostic curettage should not be undertaken under any circumstance, lest it cause injury which can lead to severe hemorrhage and uterine rupture. Angioembolization has been applied successfully to treat cavernous uterine hemangioma and preserve the patient’s uterus [18], which is critical for women with fertility requirements.



**Fig. 2. Postoperative coagulation index and blood routine fluctuation.** Fib, Fibrinogen; PT, Prothrombin time; APTT, activated partial thromboplastin time; TT, thrombin time.

However, patients with successful cavernous uterine hemangioma treatment require strict monitoring for potential recurrence in subsequent pregnancy.

In this case, massive post-partum blood loss led to hysterectomy. Afterward, long-term secondary hyperfibrinolysis required treatment for ten days. Under normal conditions, postpartum hemorrhage may lead to transient hyperfibrinolysis, which is typically corrected in 2 to 3 days with heparin and fibrinogen therapy. Refractory hyperfibrinolysis that lasts for 10 days is very atypical. Hemangiomas have a genetic predisposition, and it is possible that congenital abnormal clotting factors such as protein C and protein S deficiency [14] or acquired alpha two plasmin inhibitor deficiency contributed to the severity of this case. Due to financial limits, no further testing was performed to assess the possibility of congenital abnormality.

It is also possible that postoperative trauma induces hyperfibrinolysis, leading to early detachment of the placental scab of the endometrium and the dissolution of the embolus, thus inducing a lack of plasminogen activation inhibitor-1 and increased fibrin clearance. For example, in the case of hypotension and shock caused by hemorrhage, substantial areas of blood stasis and tissue hypoxia can induce endothelial cells to release tissue plasminogen activator (tPA), which is also a possible cause of fibrinolysis. Davenport *et al.* [20] showed that in acute traumatic coagulopathy, both the level of activated protein C and fibrinolytic activity had increased, generating early depletion of fibrinogen. Moore *et al.* [21] found that 64% of trauma patients were in fibrinolytic shutdown and 18% showed hyperfibrinolysis. Truong and Browning [22] also reported a case of hyperfibrinolysis caused by a maternal allergy; mast cell degranulation was discovered to be the cause of activated tPA and urinary plasminogen activator, thereby increasing the production of plasmin.

This case underscores that an atypically long period of refractory fibrinolytic hyperactivity developed after hysterectomy. While there are no reports of fibrinolytic hyperactiv-

ity secondary to hysterectomy, we cannot rule out surgical stimulation as a causative factor. The patient's hemangiomas, the pregnancy itself, and the trauma from the second surgery may have triggered the abnormal fibrinolysis, resulting in advanced postpartum hemorrhage, DIC, and long-time postoperative hyperfibrinolysis. As noted, further testing for possible genetic abnormalities was not possible. Although here we proposed some mechanisms of the prolonged hyperfibrinolysis in this case, we cannot determine it. However, description of the clinical course of this case may be of some use for the practice. We believe that case-accumulation may solve the question why this prolonged hyperfibrinolysis occurred. This case underscores the importance of cavernous uterine hemangioma as one of the causes of refractory uterine bleeding at the time of operation delivery. The definitive diagnosis can be made only on histological examination. Changes in the coagulation mechanism should be monitored closely during postpartum, and clinicians should be aware of the possibility of fibrinolytic hyperactivity.

## Author contributions

XC and XB are solely responsible for the design and conduct of this study, the drafting and editing of the paper and its final contents.

## Ethics approval and consent to participate

This study has been approved by the ethics committee of the Fourth Affiliated Hospital of China Medical University (No. EC-2019-KS-073), and written informed consents have been obtained from all patients.

## Acknowledgment

Special thanks go to Professor F Shan for his valuable guidance.

## Funding

This research received no external funding.



## Conflict of interest

The authors declare no conflict of interest.

## References

- [1] Chou W, Chang H. Uterine hemangioma: a rare pathologic entity. *Archives of Pathology & Laboratory Medicine*. 2012; 136: 567–571.
- [2] Malhotra S, Sehgal A, Nijhawan R. Cavernous hemangioma of the uterus. *International Journal of Gynaecology and Obstetrics*. 1996; 51: 159–160.
- [3] Thanner F, Suetterlin M, Kenn W, Dinkel H, Gassel AM, Dietl J, *et al*. Pregnancy-associated diffuse cavernous hemangioma of the uterus. *Acta Obstetrica et Gynecologica Scandinavica*. 2001; 80: 1150–1151.
- [4] Johnson C, Reid-Nicholson M, Deligdisch L, Grinblat S, Nataraajan S. Capillary hemangioma of the endometrium: a case report and review of the literature. *Archives of Pathology & Laboratory Medicine*. 2005; 129: 1326–1329.
- [5] Malhotra S, Sehgal A, Nijhawan R. Cavernous hemangioma of the uterus. *International Journal of Gynecology & Obstetrics*. 1995; 51: 159–160.
- [6] Lee EJ, Kim SH, Kim YH. Uterine cavernous haemangioma in a post-menopausal woman: CT and MRI findings mimicking uterine myoma with degeneration. *British Journal of Radiology*. 2011; 84: e68–e71.
- [7] Sharma JB, Chanana C, Gupta SD, Kumar S, Roy K, Malhotra N. Cavernous hemangiomatous polyp: an unusual case of perimenopausal bleeding. *Archives of Gynecology and Obstetrics*. 2007; 274: 206–208.
- [8] Diwan RV, Brennan JN, Selim MA, McGrew TL, Rashad FA, Rustia MU, *et al*. Sonographic diagnosis of arteriovenous malformation of the uterus and pelvis. *Journal of Clinical Ultrasound*. 1983; 11: 295–298.
- [9] Weissman A, Talmon R, Jakobi P. Cavernous hemangioma of the uterus in a pregnant woman. *Obstetrics and Gynecology*. 1993; 81: 825–827.
- [10] Saeed-Vafa D, Manucha V, Myers E, Huang Y, Ferriss J. Localized cavernous hemangioma of the uterus involving adenomyotic foci. *Journal of Cancer Research and Therapeutics*. 2011; 7: 69.
- [11] Virk RK, Zhong J, Lu D. Diffuse cavernous hemangioma of the uterus in a pregnant woman: report of a rare case and review of literature. *Archives of Gynecology and Obstetrics*. 2009; 279: 603–605.
- [12] Djunic I, Elezovic I, Ljubic A, Markovic O, Tomin D, Tadic J. Diffuse cavernous hemangioma of the left leg, vulva, uterus, and placenta of a pregnant woman. *International Journal of Gynecology & Obstetrics*. 2009; 107: 250–251.
- [13] Aka KE, Apollinaire Horo G, Fomba M, Kouyate S, Koffi AK, Konan S, *et al*. A rare case of important and recurrent abnormal uterine bleeding in a post partum woman caused by cavernous hemangioma: a case report and review of literature. *Pan African Medical Journal*. 2017; 28: 130.
- [14] Sütterlin MW, Müller T, Rehn M, Rempen A, Dietl J. Successful abdominal delivery in a woman with sonographic diagnosis of diffuse cavernous hemangioma of the uterus. *American Journal of Perinatology*. 1998; 15: 423–425.
- [15] Lotgering FK, Pijpers L, van Eijck J, Wallenburg HCS. Pregnancy in a patient with diffuse cavernous hemangioma of the uterus. *American Journal of Obstetrics and Gynecology*. 1989; 160: 628–630.
- [16] Yan X, Zhao C, Tian C, Wen S, He X, Zhou Y. Ultrasound-guided high-intensity focused ultrasound ablation for treating uterine arteriovenous malformation. *BJOG*. 2017; 124: 93–96.
- [17] Tsuzuki MO. EP28.04: Diagnosis of uterine arteriovenous malformation by 3D colour Doppler and conservative management with a gonadotropin-releasing hormone agonist. *Ultrasound in Obstetrics and Gynecology*. 2017; 50: 388.
- [18] Sigue AJ, Dominguez AM. P14.14: Acquired uterine arteriovenous malformation (AVM): case series. *Ultrasound in Obstetrics and Gynecology*. 2017; 50: 201.
- [19] Lalitha N, Seetha P, Shanmugasundaram R, Rajendiran G. Uterine arteriovenous malformation: case series and literature review. *Journal of Obstetrics and Gynecology of India*. 2016; 66: 282–286.
- [20] Davenport RA, Guerreiro M, Frith D, Rourke C, Platten S, Cohen M, *et al*. Activated protein C drives the hyperfibrinolysis of acute traumatic coagulopathy. *Anesthesiology*. 2017; 126: 115–127.
- [21] Moore HB, Moore EE, Gonzalez E, Chapman MP, Chin TL, Silliman CC, *et al*. Hyperfibrinolysis, physiologic fibrinolysis, and fibrinolysis shutdown. *Journal of Trauma and Acute Care Surgery*. 2014; 77: 811–817.
- [22] Truong HT, Browning RM. Anaphylaxis-induced hyperfibrinolysis in pregnancy. *International Journal of Obstetric Anesthesia*. 2015; 24: 180–184.