

Removal of a migrated subdermal contraceptive implant: a case report and review of the literature

M. Capell-Morell^{1,*}, N. Rodriguez-Mias¹, M. Cubo-Abert¹, M. Bradbury¹, J.L. Poza-Barrasus¹,
A. Gil-Moreno^{1,2}

¹Department of Gynecology, Vall d'Hebron University Hospital, Barcelona (Spain)

²CIBERONC Investigation Center, Madrid (Spain)

Summary

The contraceptive implant Implanon-NXT[®] provides long-acting, highly effective, and reversible contraception. Migration and embolization of the implant are rare but can cause potentially serious complications. We describe the case of a migrated Implanon-NXT[®] implant in a 35-year-old woman who requested extraction due to abnormal uterine bleeding and pain in the arm carrying the implant. The device was neither palpable at the insertion site, nor was it localized by ultrasound. Radiographic examination and Computed Tomography (CT) scan revealed it had migrated to the axilla and was in close proximity to neurovascular structures. Extraction was performed under general anesthetic and radiographic guidance.

Key words: Contraceptive implant; Implanon-NXT[®]; Migration.

Introduction

Implanon-NXT[®] (Merck & Co., Inc.), marketed as Nexplanon[®] in the USA, is a single rod contraceptive device that provides long-acting, highly effective, and quickly reversible contraception. It contains 68 mg of etonogestrel, the active metabolite of desogestrel, and is surrounded by a non-biodegradable membrane of ethylene vinylacetate copolymer. Implanon-NXT[®] is 4 cm long and is inserted subdermally in the inner side of the non-dominant arm, using an applicator. This mode of contraception is very effective, with reported failure rates of 0.05% [1]. After insertion, contraception lasts for up to 3 years as approved by the manufacturer, although evidence suggests that it might remain effective for up to 5 years [2, 3]. After its removal, fertility is usually regained within 3 weeks. The most common side effects associated to Implanon-NXT[®] are intermenstrual bleeding, headache, weight gain, and oligomenorrhea. Complications associated with its insertion or removal are rare and can involve bleeding, deep implantation, fixation or breakage of the rod. Other complications such as vascular or nerve injury, migration or embolization of the device have also been described [4]. We report the successful removal, under radiographic guidance, of an Implanon-NXT[®] which had migrated into the axilla.

Case Report

A 35-year-old multipara using the subdermal contraceptive implant Implanon-NXT[®] was referred to our gynecological department by primary care for removal of the implant, as the physicians were unable to localize the device

using ultrasonography. The patient had no relevant medical history and had been using Implanon-NXT[®] as a contraceptive for 4 years prior to requesting its removal due to abnormal uterine bleeding and pain in the arm carrying the implant. The pain had originated at the implant insertion site a month after its insertion, and during the following year had gradually extended towards the axilla and caudally affected the medial aspect of the forearm and the palm of the hand. The pain was present for a year after the insertion until the date of referral to our unit. No difficulties in the insertion technique were reported by the clinician who had inserted the device.

Upon examination, the insertion scar was easily identified on the left arm. The implant, however, could not be localized either by palpation, or by ultrasound scan. Upper limb radiography revealed the device was located close to the humerus, approximately 5 cm away from the original site of insertion (Figure 1). A computed tomography (CT) scan was requested to ensure that the implant had not caused any injury to the adjacent nerves or vascular structures. The CT showed a foreign body deep in the periphery of the biceps muscle, identified as the Implanon-NXT[®], located 4 mm lateral to the humeral artery and 1 mm lateral to the humeral vein.

The Implanon-NXT[®] extraction was performed four weeks after the initial referral, under general anesthetic by two senior gynecologists and a vascular surgeon. As a previous ultrasound examination did not identify the localization of the implant, a new radiography was requested immediately before surgery. This showed the device had migrated further into the axilla and was now located 11 cm

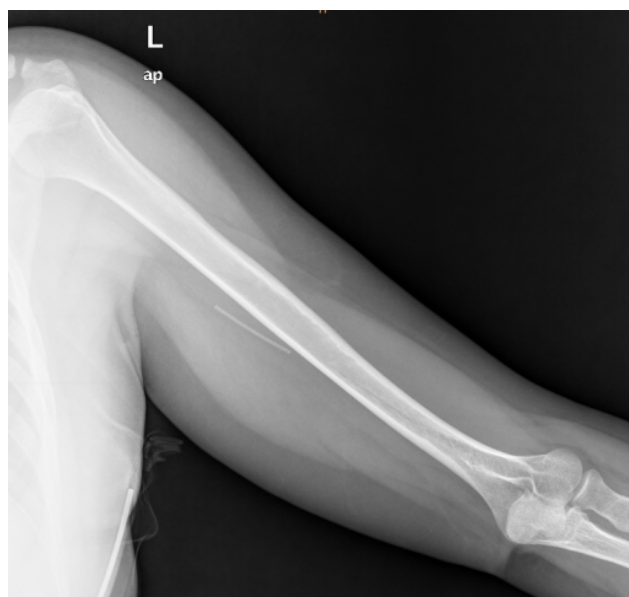

Figure 1. — The initial radiography performed to locate the implant shows the migrated device close to the humerus. A CT scan was subsequently performed to ensure no vascular or nervous structures were affected. Barium sulfate in Implanon-NXT® and Nexplanon® allows their identification using ultrasound, radiography, CT, and magnetic resonance imaging.

away from the insertion site. A 5 cm longitudinal incision was performed on the upper medial side of the left arm, 3 cm from the axillary fold, followed by dissection of the subcutaneous tissue and aperture of the fibrotic capsule. The implant was identified above the humeral artery and the cubital nerve, and was removed with forceps (Figure 2). The wound closure was performed in layers, and intradermal suture was used for closure of the skin. The patient did not develop any post-operative complications.

Discussion

Implanon-NXT® is a highly effective contraceptive method, which is inserted subdermally and lasts for up to three years. After its removal, the woman's fertility returns to normal within approximately 3 weeks. Implanon-NXT®'s removal may be requested due to expiration, due to the woman's desire to conceive, or due to adverse effects. One of the most common reasons why patients decide to switch to another contraceptive method is the development of abnormal uterine bleeding. The implant can be palpated under the skin and its removal is usually performed by trained physicians in primary care centres. This involves performing a 2 mm incision at the caudal end of the device, and using local anesthesia, in order to allow the rod to be extracted. Extraction can be difficult when the implant is fixed, damaged or the rods are broken.

A non-palpable device can be caused by failed or deep implantation, migration or embolism. Migration of Implanon-NXT®, defined as more than 2 cm of displace-

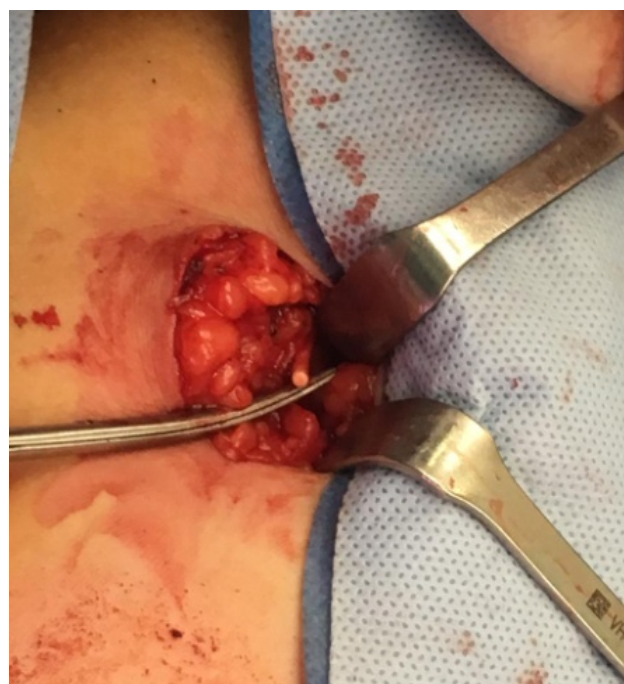


Figure 2. — Macroscopic view of the surgery. A 5 cm incision was performed on the upper medial side of the left arm, 3 cm distal to the axillary fold. The Implanon-NXT®'s rod was located after dissection of the subcutaneous tissue and aperture of the fibrotic capsule above the humeral artery and the cubital nerve, and was extracted with forceps. The device can be seen above the scissors on the image.

ment, is rare with the proper training in insertion technique [5]. Ismail *et al.* performed a prospective study of 100 patients who requested the insertion of an Implanon-NXT® device. They measured the distance between the insertion site and distal end of the rods at 3 and at 12 months' post-insertion. The authors concluded that up to 12 months after insertion, migration of the device was rare and this usually occurred caudally less than 2 cm from the insertion site [5]. Prosch *et al.* reported 21 cases of non-palpable Implanon-NXT® over a period of 4 years [6]. Only two of them involved substantial migration of 4 cm and 8 cm respectively, both in the cranial direction. A case review published in 2015 from the Food and Drug Administration (FDA) pharmacovigilance database identified 38 cases of Implanon-NXT® migration. They reported 9 cases of migration to the pulmonary artery, 14 to other vasculature locations, 1 to the chest wall, and 14 extravascular migrations to other body sites including axilla, clavicle, neck line, and shoulder. The majority of cases were asymptomatic and were only diagnosed at the time of removal, however, symptoms such as pain, discomfort or dyspnoea were reported in seven cases associated with the implant migration. Sixteen out of 38 patients required surgical removal of the device in the theatre, and only 3 were removed under local anesthesia [4].

The most important risk factor associated to Implanon-NXT® migration, is the technique used for its insertion. If

performed incorrectly, it can lead to insertion of the device into a vein, in the sulcus between the biceps and triceps muscles or intramuscularly [4]. It is particularly important to consider this complication in slim patients who are at greater risk of deep implantation of the device. When the device is not palpable and migration of the device is suspected, patients are usually referred to specialist evaluation and management. Ultrasound scan is the method of choice for the evaluation of a migrated device [6], nevertheless, in the rare occasions where this is not visualized, additional imaging techniques may be required. Both Implanon-NXT® and Nexplanon® contain barium sulfate, which allows for their identification using ultrasound, radiography, CT, and magnetic resonance imaging.

The retrieval of non-palpable implants may need to be performed in theatre and require regional or general anaesthesia, especially for devices located deeply and in close proximity to nerves and vessels. Extraction of the device is usually performed under ultrasound guidance, although other imaging techniques may be required when ultrasound fails to identify the localization of the implant. It is important that the insertion of Implanon-NXT® be performed by trained physicians in order to reduce the risk of device migration.

Conclusions

When an Implanon-NXT® device is not palpable and cannot be located by ultrasonography, clinicians should consider the possibility of deep implantation, distant migration or embolization. In these cases, referral to a specialist centre for evaluation is recommended as the localization of the device may compromise adjacent vascular structures or nerves, and may require a multidisciplinary approach.

Ethics Approval and Consent to Participate

The patient gave her informed consent for redaction and publication of the case report. The report was approved by Hospital Vall d'Hebron's Ethics Committee for publication.

Acknowledgments

We would like to acknowledge the multidisciplinary team involved in the management of the case. We would also like to thank the patient for the information provided and for consenting to publish the present case report.

Conflict of Interest

The authors declare no conflict of interest.

Submitted: January 20, 2020

Accepted: June 01, 2020

Published: December 15, 2020

References

- [1] Bensouda-Grimaldi L., Jonville-Béra P., Beau-Salinas F., Llabres S., Autret-Lecale E.: "Insertion problems, removal problems, and contraception failures with Implanon®". *Gynecol. Obstet. Fertil.*, 2005, 33, 986-990. [In French]
- [2] McNicholas C., Maddipati R., Zhao Q., Swor E., Peipert J.F.: "Use of the etonogestrel implant and levonorgestrel intrauterine device beyond the U.S. Food and Drug Administration-approved duration". *Obstet. Gynecol.*, 2015, 125, 599-604.
- [3] Ali M., Akin A., Bahamondes L., Brache V., Habib N., Landoulsi S., et al.: "Extended use up to 5 years of the etonogestrel-releasing subdermal contraceptive implant: comparison to levonorgestrel-releasing subdermal implant". *Hum Reprod.*, 2016, 31, 2491-2498.
- [4] Kang S., Niak A., Gada N., Brinker A., Jones S.C.: "Etonogestrel implant migration to the vasculature, chest wall, and distant body sites: cases from a pharmacovigilance database". *Contraception*, 2018, 96, 439-445.
- [5] Ismail H., Mansour D., Singh M.: "Migration of implanon". *J. Fam. Plann. Reprod. Health Care*, 2006, 32, 157-159.
- [6] Prosch H., Walter R.M., Westermayer V., Mostbeck G.H.: "Sonographic localization of non-palpable implanon hormone implants". *Ultraschall Med.*, 2008, 29, 239-244. [In German]

Corresponding Author:

MONTSERRAT CAPELL-MORELL, M.D.

Montserrat Capell-Morell, Gynecology Department,
Hospital Vall d'Hebron, Universitat Autònoma de
Barcelona (Spain)

e-mail: montse.capell92@gmail.com