

# Term pregnancy not requiring cerclage placement or tocolytic therapy in a patient with a unicornuate uterus and history of myomectomy

I. Rudic Biljic-Erski<sup>1</sup>, M. Vasiljevic<sup>1,2</sup>, S. Rakic<sup>1,2</sup>, O. Dzatic-Smiljkovic<sup>1,2</sup>, S. Mihajlovic<sup>1</sup>, D. Jovanovic<sup>1</sup>

<sup>1</sup>Clinic of Gynecology and Obstetrics "Narodni Front", Belgrade; <sup>2</sup>Faculty of Medicine, University of Belgrade, Belgrade (Serbia)

## Summary

The authors present the case of a 28-year-old nulliparous woman, who successfully carried a term pregnancy in a unicornuate uterus with a solid non-communicating rudimentary horn, and a history of myomectomy, without cerclage placement or tocolytic therapy. The patient was admitted to the present clinic for uterine fibroids and menorrhagia. The patient underwent laparotomy, during which a myomectomy was performed. Twelve months after the surgery, the patient conceived spontaneously. Routine obstetric ultrasounds revealed normal intrauterine fetal development. Cerclage and tocolytic therapy were not indicated at any stage of the pregnancy. A live female neonate was delivered via cesarean section at 39 weeks' gestation.

**Key words:** Unicornuate uterus; Fibroid; Pregnancy; Cesarean section.

## Introduction

A unicornuate uterus results when one Mullerian duct develops normally, while the other Mullerian duct remains undeveloped or rudimentary in development. The incidence of Müllerian duct anomalies in the general population is 0.1-3.8%. Unicornuate uterus composes 2.4-13% of all Müllerian anomalies, and is found in approximately 0.1% of the general population [1]. A unicornuate uterus may be isolated or may have a rudimentary horn. The rudimentary horn may fuse to the unicornuate uterus, resulting in a communicating uterine horn, or remain separate and result in a non-communicating horn [2]. Unicornuate uterus is associated with relatively poor reproductive outcome.

## Case Report

The authors present the case of a 28-year-old nulliparous woman, who successfully carried a term pregnancy in a unicornuate uterus with a solid non-communicating rudimentary horn, and a history of myomectomy, without cerclage placement or tocolytic therapy. The patient was admitted to the present clinic for uterine fibroids and menorrhagia. Menarche occurred at the age of 13 years. The patient's menstrual cycles were regular. The onset of heavy and prolonged bleeding was two years ago. The patient was attempting to conceive for one and a half years. The patient's hormone panel was normal, as well as her partner's semen analysis. The vagina and cervix were normal on bimanual examination, while the uterus was enlarged and dextrorotated. On transvaginal two-dimensional (2D) ultrasound, the authors found a dextrorotated uterus measuring 9.5×7.5 cm, containing submucous fibroid

measuring 5.0×4.0 cm. A normal right ovary was visualized, while the left ovary was not seen. The patient underwent a laparotomy during which a myomectomy was performed. The endometrial cavity was opened during the myomectomy, while the uterus was reconstructed and a triple layer of sutures was used to close the uterus. During laparotomy, a right unicornuate uterus with a solid non-communicating rudimentary horn, measuring 1.5×1.0 cm, was visualized. The right adnexa appeared normal, while left adnexa were hypoplastic. Endometriosis within the pelvic cavity was not visualized. Ultrasound examination of the urinary tract and karyotype were performed postoperatively. Urinary tract anomalies were not found on ultrasound, and the karyotype was 46XX. The final histopathology report confirmed the diagnosis of leiomyoma uteri. The patient was managed with estrogen-progestin combination treatment for three months postoperatively. Hysterosalpingography (HSG) was performed six months postoperatively. HSG demonstrated a deviated right unicornuate uterus with a patent right fallopian tube. Twelve months after the surgery, the patient conceived spontaneously. The pregnancy was supplemented with progesterone until 12 weeks' gestation. Bimanual pelvic exam was performed to assess the cervix at 13 weeks' gestation, and the cervix was found to be of normal length with a closed external os. Beginning from 15 weeks' gestation until term, serial cervical length measurements were performed biweekly using transvaginal ultrasound. The transvaginal ultrasound measured cervical length to be 3.7 cm at 15 weeks' gestation, followed by 3.4 cm at 24 weeks' gestation, and 2.6 cm at term. Considering bimanual pelvic exam findings and the serial cervical length measurements, there was no indication for cerclage placement. During serial cervical length measurements, the shape of the cervical canal and internal os were also assessed, but signs of tunnelling were not observed. In order to detect uterine activity, tocography was performed biweekly beginning at 18

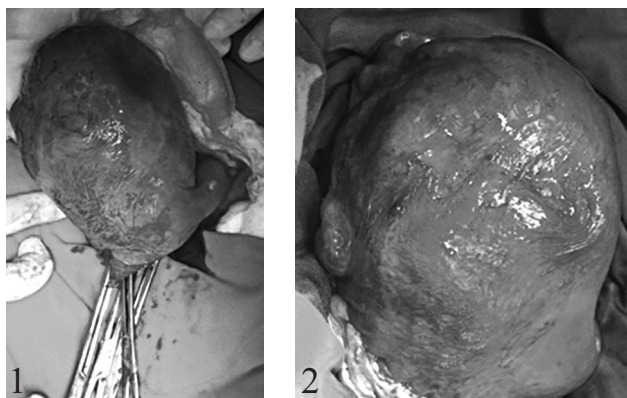


Figure 1. — A unicornuate uterus with rudimentary horn on the left side, the anterior uterine wall scar from a previous myomectomy, and low transverse isthmic uterine incision are visible.

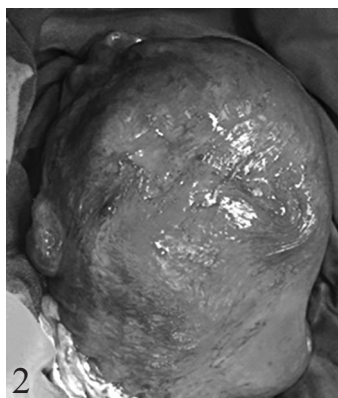


Figure 2. — The uterus is closed using one continuous suture that is placed from one to the other corners of the wound. The right fallopian tube is visible.

,weeks' gestation. In addition to uterine activity, the fetal heart rate was also monitored from 28 weeks' gestation (i.e. cardiotocography or electronic fetal monitoring), biweekly until 36 weeks, and once per week thereafter until delivery. Since cardiotocography did not register uterine activity, the patient did not receive tocolytic therapy. Obstetric ultrasounds revealed a normal intrauterine fetal development with a cephalic presentation, normal insertion of the placenta, and normal amniotic fluid volume. Colour Doppler ultrasound assessments of the feto-placental circulation were performed and were normal. The patient was delivered via a low transverse cesarean section at 39 weeks' gestation, as presented in Figures 1 and 2. A live female neonate was delivered, with an Apgar score of 9 at one minute and 10 at five minutes, weighing 3,150 grams, and 50 cm in length. The postoperative recovery was uneventful, and both the patient and the newborn were discharged on the third postoperative day.

## Discussion

Congenital malformations of the Müllerian duct system are very likely multifactorial in etiology, resulting from polygenic and familial factors. Mutations in the TP63 gene are potentially associated with Müllerian duct anomalies [3]. Unicornuate uterus composes 2.4-13% of all Müllerian anomalies, and is found in approximately 0.1% of the general population [1]. The prevalence of a unicornuate uterus is low, ranging from 0.2% in the fertile population, and is the highest in the infertile population at 0.6% [4]. There are four types of unicornuate uterus. The most common type is no horn and composes 35% of all unicornuate uterus cases. The second most common is a unicornuate uterus without a cavity, which occurs in 33% of cases, followed by the non-communicating type occurring in 22% of cases, and communicating type occurring in 10% of cases [5]. Due to the risk of hematometra, endometriosis and even ectopic pregnancy, surgical removal of a functional

non-communicating rudimentary horn is indicated [6]. Pregnancies have occurred in the communicating rudimentary horn of the uterus. In a review of studies by Reichman *et al.*, only 2.7% had an ectopic pregnancy in the rudimentary horn [7]. Rudimentary horn pregnancy is at high risk for uterine rupture. Upon diagnosis of a rudimentary horn pregnancy, the rudimentary horn and the ipsilateral fallopian tube should be excised. A unicornuate uterine pregnancy is associated with a high frequency of obstetric complications including spontaneous abortion, preterm birth, intrauterine growth restriction (IUGR), placenta previa, placental abruption, intrauterine fetal demise, breech presentation, and cesarean section [8]. Transcervical uterine incision appeared to improve the pregnancy outcome in women with unicornuate uterus presenting with infertility or miscarriage. In a research study by Xia *et al.*, 64.5% of patients with a unicornuate uterus conceived after a transcervical uterine incision [9]. First trimester spontaneous abortion occurred in 5% of these patients, while 25% and 55% had preterm and term pregnancies, respectively. In women with a unicornuate uterus, the live birth rate is 29.2%, the prematurity rate is 44.0%, and miscarriage rate is 29%, while the ectopic pregnancy rate is 4.0% [1,4]. In a study by Bakshi *et al.*, out of 13 pregnancies in unicornuate uterus, miscarriage, preterm delivery, and IUGR occurred in 23.1% each, while mal-presentation complicated 7.7% pregnancies, oligohydramnios 30.8% pregnancies, and intrauterine fetal demise 15.4% pregnancies. Rates of term delivery and live births were 53.8% and 61.5%, respectively [10]. The present patient successfully carried a term pregnancy in a unicornuate uterus with a solid non-communicating rudimentary horn, and a history of myomectomy, without cerclage placement or tocolytic therapy. On the other hand, a few cases of successful term pregnancies have been described in women with a unicornuate uterus. Mishra *et al.* reported a successful term pregnancy in a woman with a unicornuate uterus and without rudimentary horn, which was terminated by cesarean section at 38 weeks' gestation [11]. Hocaoglu *et al.* reported case of a gravida 4 para 3 woman with a unicornuate uterus and non-communicating rudimentary horn whose pregnancy at 38 weeks was terminated with a cesarean section. She had previously delivered three live births at term [12].

## Conclusion

Pregnancy in a patient with a unicornuate uterus and previous myomectomy, can be carried to term without the placement of cerclage when biweekly serial cervical measurements, beginning at 15 weeks' gestation, demonstrate normal cervical length without tunneling of the internal os. Furthermore, the pregnancy can also be carried to term without tocolytic therapy, when tocography, beginning at 18 weeks' gestation, and biweekly cardiotocography from 28 weeks, do not register uterine activity.

## References

- [1] Caserta D., Mallozzi M., Meldolesi C., Bianchi P., Moscarini M.: "Pregnancy in a unicornuate uterus: a case report". *J. Med. Case Rep.*, 2014, 8, 130.
- [2] Lai Z.J., Lin C.H., Hou W.C., Hwang K.S., Yu M.H., Su H.Y.: Pregnancy in a noncommunicating rudimentary horn of a unicornuate uterus: prerupture diagnosis and management. *Taiwan. J. Obstet. Gynecol.*, 2016, 55, 604.
- [3] Wang X., Zhang X., Liu S., Li G., Cui L., Qin Y., et al.: "Novel mutations in the TP63 gene are potentially associated with Mullerian duct anomalies". *Hum. Reprod.*, 2016, 31, 2865.
- [4] Narayan S., Kumari P., Yadav K., Narayan J.: "Obstetric outcome in a woman who had unicornuate uterus with ectopic ovary, absent kidney and ureter on right side". *Med. J. Obstet. Gynecol.*, 2015, 3, 1050.
- [5] Kumar N., Tayade S.: "Successful pregnancy outcome in an untreated case of concomitant transverse complete vaginal septum with unicornuate uterus". *J. Hum. Reprod. Sci.*, 2014, 7, 276.
- [6] Amrin S., Mukherjee S., Jain U.: A case of functional non-communicating rudimentary horn of unicornuate uterus presenting as persistent lump abdomen. *Int. J. Reprod. Contracept. Obstet. Gynecol.*, 2016, 5, 530.
- [7] Reichman D., Laufer M.R., Robinson B.K.: "Pregnancy outcomes in unicornuate uteri: a review". *Fertil. Steril.*, 2015, 103, 1615.
- [8] Kamble V., Shah S., Patil S., Bhatia T.: "A case report of successful pregnancy outcome in unicornuate uterus with rudimentary horn". *J. of Evolution of Med. and Dent. Sci.*, 2015, 4, 888.
- [9] Xia E.L., Li T.C., Choi S.N.S., Zhou Q.Y.: "Reproductive outcome of transcervical uterine incision in unicornuate uterus". *Chin. Med. J.*, 2017, 130, 256.
- [10] Bakshi K., Popuri P.K., Daruri S.V.C.: "Pregnancy outcome in unicornuate uterus with rudimentary horn". *Annals of Woman and Child. Health*, 2015, 1, A5.
- [11] Mishra V., Roy P., Vyas B., Aggarwa R., Hokabaj S., Gondhali R.: Unicornuate uterus and pregnancy outcome: a case report. *Int. J. Reprod. Contracept. Obstet. Gynecol.*, 2016, 5, 4522.
- [12] Hocaoglu M., Kanter M., Gocmen A.: A case of unicornuate uterus accidentally discovered during patients fourth delivery. *Eur. J. Basic. Med. Sci.*, 2015, 5, 67.

Corresponding Author:  
M. VASILJEVIC, M.D.  
Omladinskih brigada 7V  
11000 Belgrade (Serbia)  
e-mail: dmdnmvas@eunet.rs