

Successful management of primary splenic pregnancy: a case report and review of literature

B. Lv, S.T. Zhou, H.L. Peng, H.W. Ma, Y. Wu, X. Zhao

Department of Gynecology and Obstetrics, West China Second Hospital, Sichuan University, Chengdu (China)

Summary

Ectopic pregnancy is defined as dislocation of a fertilized ovum anywhere other than in the cavity of uterus. Generally, the common site for dislocation is within fallopian tube, accounting for 95.5% of all ectopic gestations. Abdominal pregnancy is rare with a potentially life-threatening variation that resides within peritoneal cavity and the primary splenic pregnancy is even rarer. This report describes a patient with primary splenic pregnancy, who was successfully managed after splenectomy.

Key words: Ectopic pregnancy; Splenic pregnancy; Case report.

Introduction

Ectopic pregnancy is defined as dislocation of a fertilized ovum anywhere other than in the cavity of uterus. Generally, the common site for dislocation is within fallopian tube, accounting for 95.5% of all ectopic gestations. Abdominal pregnancy is rare with a potentially life-threatening variation that resides within peritoneal cavity and the primary splenic pregnancy is even rarer.

Case Report

The authors report a case of a 36-year-old female presenting with mild colporrhagia after over 30 days' amenorrhea. On the 58th day after last menstrual period, she saw a doctor in the local hospital and she received blood test for beta human chorionic gonadotropin (β -hCG), which was 16,000 mIU/ml. Ultrasonography suggested "weak anechoic area posterior to left ovary, without pelvic or abdominal effusion". She was diagnosed with ectopic pregnancy in the left adnexal area and she received a laparoscopic exploration in that hospital. During the surgery, a normal size uterus with distorted left fallopian tube was observed. A 600-ml hematocele was observed in the pelvic and abdominal cavity with no other positive findings. There were no bleeding foci in the intestinal canal, omentum, or surface of spleen. Left fallopian tube was excised during the surgery. In the meanwhile, dilation and curettage (D&C) was performed and no visible villus was found. The pathological examination of tissues obtained by D&C suggested an A-S apocrine secretion of endometrium scraped from the uterine cavity, decidualized change of mesenchyme, villous cells, and trophoblast were not seen. The left fallopian tube demonstrated chronic inflammation and hemorrhage and only a few trophoblasts were found in the blood clot in the abdominal cavity. Two days after operation, blood hCG level reached 14,502 mIU/ml, and four days after operation, it

reached 37,901 mIU/ml. Re-examination of B ultrasound on the fourth day post-operation demonstrated that the middle-upper inside part of spleen exhibited a mixed anechoic area with a size of about 3.7 cm (Figure 1A). The patient was suspected with splenic pregnancy and transferred to the present hospital. On the seventh day in the present hospital, abdominal CT scan suggested occupation in the inner part of hilus lienis (Figure 1B). On the ninth day after last laparoscopy, the authors performed exploratory laparotomy and found no positive signs in the uterus as well as in bilateral annex. However, although the spleen was normal in shape, a blue six-cm mass could be seen in the upper pole of the spleen, partly protruding from the surface of spleen, with a complete envelope. Then the authors performed splenectomy and they could see that the blue mass was five cm deep in splenic parenchyma with visible villus inside (Figure 1C). Pathological examination reported chorionic villi in the splenic foci (Figure 1D). Blood hCG decreased to 21,471.6 mIU/ml one day post-operation and to 3,846.6 mIU/ml after three days postoperation. Her blood hCG returned to normal three weeks after splenectomy. Therefore, this patient was diagnosed with a splenic pregnancy.

Discussion

To the authors' knowledge, 15 case reports in the literature (the present included) of primary splenic pregnancies have been reported [1, 2] and most presented with sudden or short-lasting abdominal pain, radiating to the left shoulder. Most of the gestations were subcapsular in location and assumed the appearance of an irregular mass that exceeds the contour of the spleen. This case is interesting because transvaginal sonography, curettage, and laparoscopy were inconclusive. A continuously elevating blood level of β -hCG, suggesting the presence of ectopic

Revised manuscript accepted for publication February 1, 2016

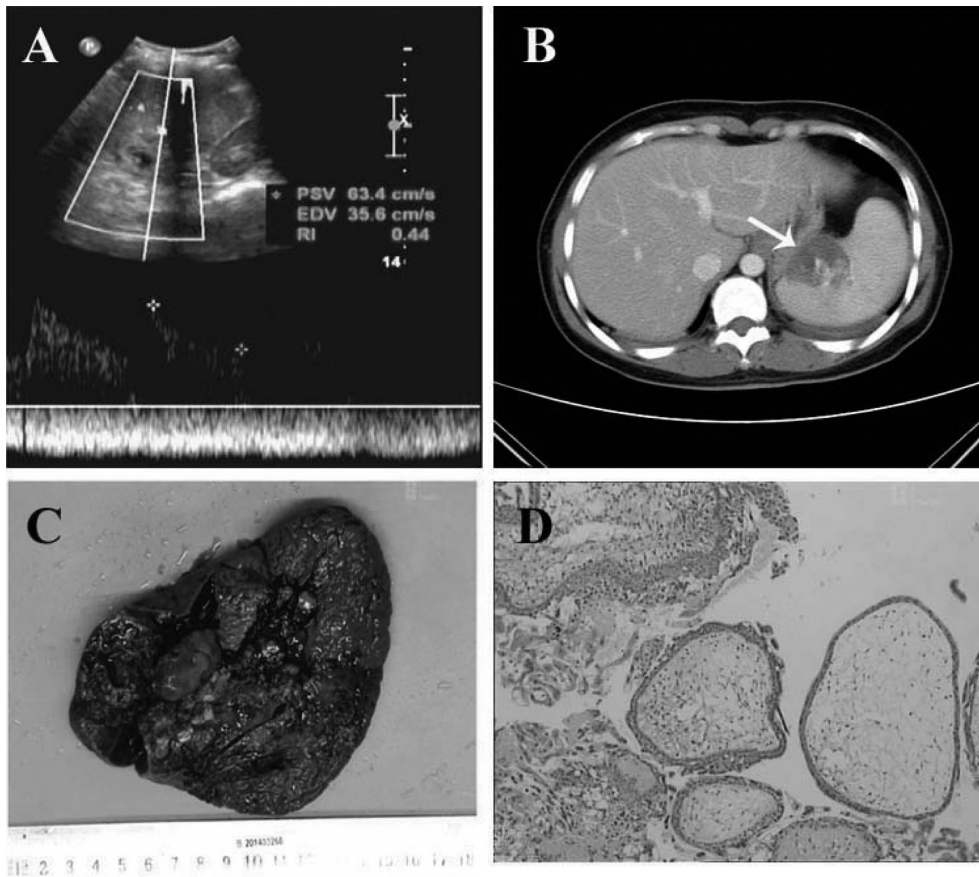


Figure 1. — Successful management of primary splenic pregnancy. (A) Ultrasonography reveals middle-upper inside part of spleen exhibiting a mixed anechoic area. (B) CT scan reveals occupation in the inner part of hilus lienis (white arrow). (C) Mass is deep in splenic parenchyma with visible villosity inside. (D) Pathological examination reveals chorionic villi in the splenic foci.

pregnancy, was confirmed afterwards by abdominal ultrasound and computerized tomography scan. Abdominal pregnancy is rare in clinical practice and primary splenic pregnancy is even rarer, with extremely high maternal mortality rates. Preventing splenic pregnancy-related deaths depend in part on increasing awareness of its clinical characteristics. Abdominal pregnancy should be considered in the differential diagnosis of acute abdomen in women of reproductive age.

Conclusion

This case report demonstrates that ectopic pregnancy removal must be attempted primarily in laparoscopy, even in case of extensive bleeding or haemoperitoneum; laparotomy, however, should be reserved to laparoscopic failure.

References

- [1] Biolchini F., Giunta A., Bigi L., Bertellini C., Pedrazzoli C.: "Emergency laparoscopic splenectomy for haemoperitoneum because of ruptured primary splenic pregnancy: a case report and review of literature". *ANZ. J. Surg.*, 2010, 80, 55.
- [2] Gang G., Yudong Y., Zhang G.: "Successful laparoscopic management of early splenic pregnancy: case report and review of literature". *J. Minim. Invasive Gynecol.*, 2010, 17, 794.

Corresponding Author:

X. ZHAO, M.D.

Department of Gynecology and Obstetrics

West China Second Hospital

Sichuan University

No. 20, Section 3, Renmin South Road

Chengdu, Sichuan Province 610041 (China)

e-mail: xia-zhao@126.com