

# Adenoid cystic carcinoma of Bartholin's gland: A case report

**E. Paraskevaidis, M.D.; C. Zioga, M.D.; S. Chouliara, M.D.; G. Koliopoulos, M.D.;  
S. Tzioras, M.D.; Z. Metafratzi, M.D.; D. Lolis, M.D.**

*Department of Obstetrics and Gynecology, Ioannina University Hospital, Ioannina (Greece)*

## Summary

Adenoid cystic carcinoma is an uncommon histological type of the already rare carcinoma of Bartholin's gland with 51 cases described in the literature. We present a case of a 66-year-old woman who was admitted with severe pelvic pain. In an examination under anesthesia a 10x5 cm apparently fixed mass at the left vaginal wall originating from the area of Bartholin's gland was found, and biopsy indicated carcinoma. The patient underwent wide local excision. Although clinically inoperable, the tumor did not infiltrate the bony pelvis and no evidence of metastasis was found.

Pathology examination revealed adenoid cystic carcinoma of Bartholin's gland. PCR did not detect human papillomavirus DNA in the specimen. The patient has been treated with adjuvant radiotherapy, and is alive with no evidence of disease after ten months.

**Key words:** Bartholin's gland; Adenoid cystic carcinoma.

## Introduction

Since 1675, when Bartholin first described the gland that bears his name, more than 200 cases of carcinoma of Bartholin's gland have been reported in the literature. Bartholin's gland carcinoma accounts for 0.1-7% of all vulval carcinomas [1, 2].

Various histological types have been reported: adenocarcinoma, squamous, adenosquamous and adenoid cystic carcinoma; the latter accounts for approximately 5-15% of all Bartholin's gland malignancies [1, 3, 4]. To date 51 cases of adenoid cystic carcinoma have been reported in the literature [1, 2, 5-8], and there is no consensus regarding the most optimal treatment. We report a new case of a 66-year-old white female patient with this rare tumor.

## Case Report

A 66-year-old, gravida 3, para 2, white female presented in February 2000 with severe perineal pain and was admitted to our department. The patient had no previous medical history, her last Pap test 17 months before was normal, and her last menstrual cycle was 13 years ago. Because of exquisite local tenderness bimanual gynecological examination, a Papanicolaou test and transvaginal ultrasound were impossible. Chest X-ray showed osteolytic areas at the hips. Pelvic MRI revealed a 7x7x5 cm mass arising from the left Bartholin gland, in close contact with the ipsilateral pubic ramus but without indications of infiltration of periostic reaction. Inguinal lymphadenopathy was not seen. Blood tests showed elevated  $\alpha$ -fetoprotein, while all other tumor markers were within normal limits.

An examination under general anesthesia was performed and revealed a hard diffuse mass approximately 10x5 cm at the left vaginal wall originating from the area of Bartholin's gland. It gave the impression of being fixed to the pelvic bones, and therefore was inoperable. Clinically there was no impression of inguinal lymphadenopathy. Colposcopy and biopsy of the suspicious area followed. Colposcopy results were normal except for a protuberance of the lower left vaginal wall. The pathological examination revealed carcinoma but was inconclusive for the histological type. The patient then underwent an operation in order for a larger specimen to be obtained for a

definite pathological examination. An incision lateral to the left of the labium majus was performed (Figure 1). Despite the discouraging clinical examination findings the tumor did not infiltrate the pelvic bones and was completely excised (Figure 2). Pathological examination revealed extensive infiltration from neoplastic cells arranged in adenoid cystic formations giving a cribriform pattern consistent with adenoid cystic carcinoma of Bartholin's gland (Figure 3). The amorphous material in the cystic formations stained weakly with PAS. Immunocytochemically the cells were strongly positive for cytokeratins, CEA and actin, and less positive for epithelial membrane

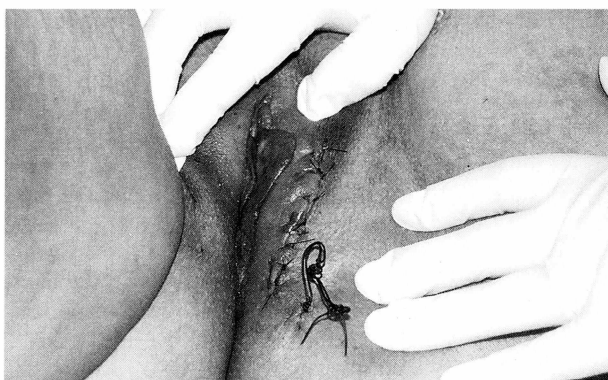

Figure 1. — The perineum of the patient at the end of the procedure. A wide local excision was done through an incision lateral to the labium majus.

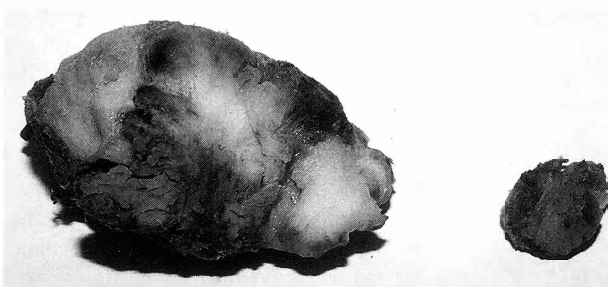


Figure 2. — The excised specimen measuring 8x5 cm. The excision was complete.

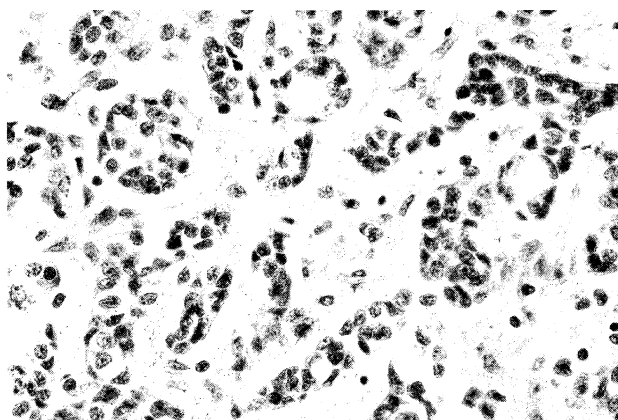


Figure 3. — Microscopic appearance of the tumor with extensive infiltration from neoplastic cells arranged in adenoid cystic formations giving a cribriform pattern consistent with adenoid cystic carcinoma of Bartholin's gland.

antigen and S-100 protein. Excision margins were free of tumor. The patient received adjuvant external beam radiotherapy, and there was no evidence of metastasis or local recurrence after nine months. We examined the excised specimen for the presence of human papillomavirus DNA using polymerase chain reaction (PCR) with negative results.

### Discussion

Adenoid cystic carcinoma is an uncommon histological type of the already rare Bartholin's gland carcinoma. Including the present case 52 cases have been reported in the literature. This type of carcinoma is more frequently encountered in the salivary gland. The mean age at presentation of adenoid cystic carcinoma of Bartholin's gland is 49 years [1]. A characteristic feature of this malignancy is that it frequently invades along the neural sheath [2]. Its physical history is relatively slow and blood-borne metastases to bones, liver and lungs are delayed, and are preceded by local recurrences [9]. Lymph node metastases in the absence of distant metastases are rare [5]. The etiology is unknown. Some HPV types, especially type 16, have been related to Bartholin's gland carcinoma, but not the adenoid cystic type [10]. Similarly in this case HPV DNA was not detected. At early stage carcinoma of Bartholin's gland presents with a variety of symptoms: pain, bleeding, dyspareunia, pruritus, and a palpable mass. Approximately 10% of patients have a history of Bartholinitis and many are initially mistreated as having an abscess or inflammation [1, 3]. Therefore gynecologists should always have in mind the possibility of carcinoma when dealing with an apparent abscess of Bartholin's gland, especially in older women.

Due to the lack of extensive studies treatment of adenoid cystic carcinoma of Bartholin's gland should be tailored to each patient. Most studies agree that the initial treatment should be surgical. No consensus exists on the adequate surgical management of this carcinoma, since some authors suggest radical vulvectomy with or without bilateral inguofemoral lymph node dissection [5, 11], while others suggest more conservative surgery such as

wide local excision [9]. There is an approximately 61% risk of recurrence after local excision according to the literature as it is harder to achieve negative excision margins, while patients who undergo radical vulvectomy have lower risk of recurrence, approximately 50% [1], but have more intra- or postoperative complications. In one review article inguinal lymphadenectomy was recommended only for those cases with suspicious nodes, since this tumor rarely affects the inguinal nodes without having already caused distant metastases [5]. Adjuvant radiotherapy is recommended in most studies, especially when the excision margins are positive [1, 2, 12].

It is noteworthy that in this case despite its large dimensions the tumor was not infiltrating the pelvic bones and could be totally excised. This suggests that surgeons should not be discouraged by the clinical findings from attempting to remove the tumor completely, when dealing with similar cases.

### References

- [1] DePasquale S. E., McGuinness T. B., Mangan C. E., Husson M., Woodland M. B.: "Adenoid cystic carcinoma of Bartholin's gland: A review of the literature and report of a patient". *Gynecol. Oncol.*, 1996, 61, 122.
- [2] Dunn S.: "Adenoid cystic carcinoma of Bartholin's gland: A review of the literature and report of a patient". *Acta Obstet. Gynecol. Scand.*, 1995, 74, 78.
- [3] Nycum L. R., Farley J. H., Reed M. E., Taylor R. R.: "Recurrent squamous cell carcinoma of the Bartholin's duct treated with en bloc resection". *Gynecol. Oncol.*, 1999, 75, 282.
- [4] Copeland L. J., Sneige N., Gershenson D. M., McGuffee V. B., Abdul-Karim F., Rutledge F. N.: "Bartholin gland carcinoma". *Obstet. Gynecol.*, 1986, 67, 794.
- [5] Anaf V., Buxant F., Rodesh F., Simon P., van de Stadt J., Noel J. C., van Geertruyden J.: "Adenoid cystic carcinoma of Bartholin's gland: what is the optimal approach?". *Eur. J. Surg. Oncol.*, 1999, 25, 406.
- [6] Tsukahara Y., Mori A., Fukuta T., Katsuyama T., Yamagami O.: "Adenoid cystic carcinoma of Bartholin's gland: a clinical, immunohistochemical and ultrastructural study of a case with regard to its histogenesis". *Gynecol. Obstet. Invest.*, 1991, 31, 110.
- [7] Amichetti M., Aldovini D.: "Primary adenoid cystic carcinoma of the Bartholin's gland: a clinical, histological and immunocytochemical study of a case". *Eur. J. Surg. Oncol.*, 1988, 14, 335.
- [8] Yamagiwa S., Niwa K., Yokoyama Y., Tanaka T., Murase T., Shimonaka E. *et al.*: "Primary adenoid cystic carcinoma of the Bartholin gland. A case report". *Acta Cytol.*, 1994, 38, 79.
- [9] Copeland L. J., Sneige N., Gershenson D. M., Saul P. B., Stringer C. A., Seski J. C.: "Adenoid cystic carcinoma of Bartholin gland". *Obstet. Gynecol.*, 1986, 67, 115.
- [10] Felix J. C., Cote R. J., Kramer E. E., Saigo P., Goldman G. H.: "Carcinomas of Bartholin's gland. Histogenesis and the etiological role of human papillomavirus". *Am. J. Pathol.*, 1993, 142, 925.
- [11] Bernstein S. G., Voet R. L., Lifshitz S., Buchsbaum H. J.: "Adenoid cystic carcinoma of Bartholin's gland: Case report and review of the literature". *Am. J. Obstet. Gynecol.*, 1983, 147, 385.
- [12] Rosenberg P., Simonsen E., Risberg B.: "Adenoid cystic carcinoma of Bartholin's gland: a report of five new cases treated with surgery and radiotherapy". *Gynecol. Oncol.*, 1989, 34, 145.

Address reprint requests to:  
EVANGELOS PARASKEVAIDIS, M.D.  
Associate Professor  
Department of Gynaecology  
Ioannina University Hospital  
45001 Ioannina (Greece)