

# Laparoscopic hysterectomy using ultrasonic instruments in at risk women with cardiovascular disease: 2 cases reports

**Z. Holub<sup>1</sup>, L. Kliment<sup>1</sup>, R. Ouhrabková<sup>2</sup>**

*Department of Obstetrics and Gynaecology, Endoscopic Training Center<sup>1</sup>, Department of Radiology<sup>2</sup>,  
Baby Friendly Hospital, Kladno (Czech Republic)*

## Introduction

The first case that used the harmonic scalpel for a total laparoscopic hysterectomy was reported by Schwartz in 1994 [1]. Robbins and Ferland in 1995 reported the first laparoscopic-assisted vaginal hysterectomy (LAVH) with the use of laparoscopic coagulating shears (LCS) in three women [2]. These are the first reported cases of laparoscopic hysterectomy (LH) using only LSC in patients at risk with a history of cardiovascular disease.

## Case reports

### *Patient no. 1*

On January 23, 1999 a 54-year-old woman was referred to the Department of Obstetrics and Gynecology, Baby Friendly Hospital, Kladno due to pelvic pain and fibromyoma. She had been admitted for a cardiostimulator for sick sinus syndrome 3 years before. After endometrial biopsy and hysterectomy the patient was scheduled for laparoscopic hysterectomy and bilateral salpingo-oophorectomy using an ultrasonic operative technique because electrosurgery was regarded as dangerous. The laparoscopic procedure was performed by the same technique described for patient no. 2.

### *Patient no. 2*

On March 10, 1999 a 67-year-old woman was admitted to the same hospital for postmenopausal uterine bleeding. She had had a salpingo-oophorectomy on the right side 34 years before. Pelvic examination, ultrasound and endometrial biopsy revealed early stage endometrial cancer (no myoinvasion, Grade 1).

Computerized tomography showed an aneurysm and thrombosis of the left iliac common artery (Fig. 1). Preoperative arteriography revealed that the aneurysm began at the aortal bifurcation and finished before the external iliac artery division. Total aneurysm length reached 80-90 mm with vessel lumen dilated to 75x65 and presence of parietal thrombus the size of 40x45.

Considering increased risk of thromboembolic disease, the patient was covered by mini-heparinization (Fraxiparine 0.6 mg s.c. daily) during hospitalization.

At surgery an aneurysm resection of the common iliac artery on the right side with reconstructive substitution by vessel synthetic endo-prosthesis (Prolen, 25 cm length, 9 mm lumen) was performed from retroperitoneal access.

After reconstructive surgery the patient was readmitted to the Department of Obstetrics and Gynecology and scheduled on April 6, 1999 for a laparoscopic hysterectomy and left salpingo-

oophorectomy with the use of a harmonic scalpel and LCS K 5-five mm instruments. Operative technique: the laparoscopy was performed in the lithotomy position using video-monitoring equipment. The telescope was inserted in the subumbilical position and one 10 mm port of entry was placed suprapubically and medially. Finally, two 5 mm ports were placed in the lower quadrant beside the lateral edge of the direct abdominal muscle. Five mm laparoscopic shears and hook (Ultracision, Ethicon Endo-Surgery, Johnson&Johnson s.r.o., Cincinnati, Ohio, USA) were used to perform the dissection of omental adhesions, located near the resected iliac aneurysm, and intestinal adhesions after the right salpingo-oophorectomy. Afterwards the laparoscopic hysterectomy and left salpingo-oophorectomy were performed. All steps, including severance of the uterine vessels, were performed laparoscopically using the LCS. The anterior and posterior vaginal dissection was carried out by ultrasonic hook after the cup of Koh was placed over the cervix. The cup is a part of a new system described by Koh in 1998 [3]. Other instruments included a suction-irrigator probe and grasping forceps. The vaginal cuff was sutured from bottom up. Finally a laparoscopic check was performed.

## Results

Duration of surgery was 90 and 70 minutes, respectively. No bleeding occurred and blood loss was less than 50 ml in both cases. In the first case fibromyoma (380 g) was confirmed. In the second case the specimen weighed only 80 g and the pathology department reported well-differentiated endometrial adenocarcinoma without myoinvasion. No complications were observed. Both patients had an uneventful postoperative course and have been doing well since discharge from the hospital.

## Discussion

Laparoscopic hysterectomy was introduced to clinical practice by Reich ten years ago [4]. Hysterectomy is currently the most frequent type of gynecologic surgery. Laparoscopic hysterectomy and lymph node dissection have lately been reported as an alternative to the open procedure for the treatment of uterine malignancy [5, 6].

The ultrasonically activated scalpel was originally developed to carry out surgical incisions and hemostasis at the same time [7, 8]. The system of harmonic scalpel consists of a generator, reusable handpiece and blade. The laparoscopic coagulating shears may offer much wider application since they occlude, coagulate and divide larger arterial vessels. The LCS provides effective coagulation and cutting [8]. Advantages include less

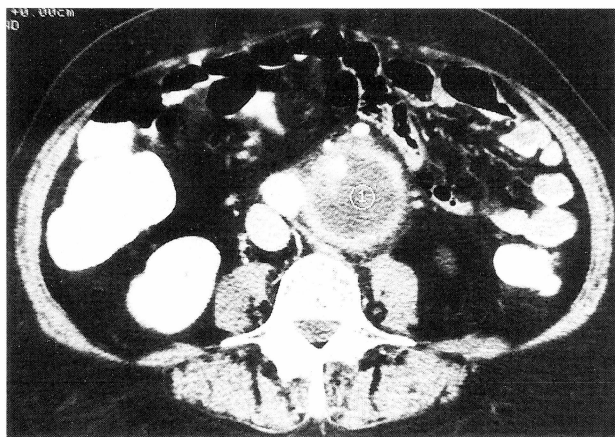


Figure 1. — Preoperative computed tomography showing an aneurysm of the left iliac common artery.

charring and pluming, better visualization and less thermal injury. An initially apparent disadvantage of the harmonic scalpel is that it seems to be slower than bipolar coagulation [2]. Some authors have used the harmonic scalpel or LCS in thoracic surgery, colorectal surgery, para-aortic lymphadenectomy and interstitial pregnancy [9-12]. These authors believe that the ultrasonic procedure is safe and effective and may also reduce the length of postoperative hospital stay. Stringer [13] first reported the use of ultrasonic energy for laparoscopic myomectomies in 1994. A further Stringer [14] report reviews the hemostatic and cutting capabilities of ultrasonic energy in a larger series of 100 patients: the postoperative incidence of adhesion and fistula formation, additional pregnancy results, and major, minor and energy-related complications.

Assessment of complications connected with using the harmonic scalpel come mostly out of chance observation. Awwad and Isaacson [15] described a case of a 35-year-old woman who sustained injury to the sigmoid colon from the use of the harmonic scalpel during the lysis of pelvic adhesions. In connection with a stapler and electro-surgical operative technique, a number of serious complications have occurred [16, 17]. Shileds *et al.* [17] reported unusual cases of cardiac failure due to internal iliac arterio-venous fistula after laparoscopically-assisted vaginal hysterectomy performed by Endo Gia staples and bipolar diathermy. They believe that while vascular injury had not been noted at the time of surgery, the fistula was caused by iatrogenic injury, possibly following diathermy. There is still discussion as to the appropriate use of relatively new endoscopic techniques in place of older more tested procedures. Until the results of large-scale randomized controlled trials comparing these procedures are published, serious complications should be taken into account when considering laparoscopic techniques [17].

We presume that thermic changes occurring near electro-surgical instrument tips can cause undesirable damage of imminent organs, especially in predilective and disposed locations. To these potentiating risk factors

belong pelvic fibrotic and adhesive processes due to endometriosis, inflammatory diseases and previous operations. Rupture of an aortal aneurysm or iliac vessels occur spontaneously or in connection with a number of rare diseases (Marfan's syndrome, Ehlers-Danlos' syndrome, Takayasu's disease), and in connection with trauma [18, 19]. We think that the use of the harmonic scalpel in patients of this risk group is safer than using electro-surgical techniques, especially mono-polar coagulation.

In a recent literature review (Medline, Embase) we found reference to application of the harmonic scalpel in laparoscopic hysterectomy in a few cases or small group of women with female benign conditions only [1, 2, 16]. In our previous experience we used LCS in the laparoscopically-assisted surgical staging of endometrial cancer [20]. Using the LCS, we performed a dissection of lymph nodes with minimum bleeding which was very close to the major pelvis vessels and the ureter. This experience was the reason for using LCS in a patient with endometrial cancer and a risk history of previous laparotomy and especially risk of extraperitoneal surgical treatment of an iliac artery aneurysm. The laparoscopic ultrasonic operative technique was easy to use and allowed a surgeon to perform laparoscopic hysterectomy and salpingo-oophorectomy after dissection of intraperitoneal adhesions close to iliac vessels and intestine. To provide hemostasis in the woman having surgery only the LCS were used including the coagulation and cutting of the uterine artery. The disadvantage of slower coagulation compared to electrosurgery was balanced by the necessity to change the instrument during the operation. The proof for this is that the duration of the procedure is 70 min, which is comparable to the duration of laparoscopic hysterectomies performed by electro-surgical techniques [21]. As the harmonic scalpel causes formation of aerosol from an ultrasonically activated device, a local exhaust system or smoke-evacuation method should be activated to reduce exposure to blood, blood products, and potentially infectious material [22]. We believe that in cases when the use of electrosurgery is dangerous or not applicable in women with cardiostimulators or risk history of pelvic vascular reconstructive surgery, the ultrasonic operative technique is safe and represents another possible application in the field of laparoscopic hysterectomy.

## References

- [1] Schwartz R. O.: "Total laparoscopic total hysterectomy with harmonic scalpel". *J. of Gynecol. Surgery*, 1994, 10, 33.
- [2] Robbins M. L., Ferland R. J.: "Laparoscopic-assisted vaginal hysterectomy use the laparoscopic coagulating shears". *J. of the Am. Assoc. of Gynec. Laparos.*, 1995, 3, 339.
- [3] Koh C.: "A new technique and system for simplifying total laparoscopy". *J. Am. Assoc. of Gynec. Laparos.*, 1998, 5, 187.
- [4] Reich H., DeCaprio J., McGlynn F.: "Laparoscopic hysterectomy". *J. of Gynecol. Surgery*, 1989, 5, 213.
- [5] Childers J. M., Brzechffa P., Hatch K. D., Surwit E. A.: "Laparoscopically assisted surgical staging (LASS) of endometrial cancer". *Gynaecology Oncology*, 1993, 47, 669.

- [6] Querleu D., Leblanc E., Castelain B.: "Laparoscopic pelvic lymphadenectomy in the staging of early carcinoma of the cervix". *Am. J. of Obstet. and Gynaecol.*, 1991, 164, 579.
- [7] Nezhat C. R., Nezhat F. R., Luciano A. A. *et al.*: "Operative gynecologic laparoscopy: principles and techniques". McGraw-Hill, Inc. 1st ed., 1995.
- [8] Amaral J. F.: "The experimental development of an ultrasonically activated scalpel for laparoscope use". *Surgery, Laparoscopy and Endoscopy*, 1994, 4, 92.
- [9] Watanabe S., Sato H., Tawaraya K. *et al.*: "Advantages and disadvantages of harmonic scalpel in thoracic surgery". *Kyobu-Geka*, 1998, 51, 374.
- [10] Lorenz E., Konradt J., Ehren G. *et al.*: "Laparoscopic rectum cancer resection with ligature of inferior mesenteric artery and mesorectal excision". *Zentralblatt für Chirurgie*, 1998, 123, 746.
- [11] Shen G. J., Mannel R. S., Walker J. L. *et al.*: "Laparoscopic para-aortic lymphadenectomy use laparoscopic coagulating shears". *J. of the Am. Assoc. of the Gynec. Laparos.*, 1998, 5, 47.
- [12] Dalkalitis A., Stefanidis K., Paschopoulos M. *et al.*: "Laparoscopic treatment of interstitial pregnancy use the harmonic scalpel". *Clin. and Exp. Obstetrics and Gynecology*, 1998, 25, 49.
- [13] Stringer N. H.: "Laparoscopic myomectomy with the harmonic scalpel: a review of 25 cases". *J. of Gynecol. Surgery*, 1994, 10, 241.
- [14] Stringer N. H.: "One hundred laparoscopic myomectomies with ultrasonic energy: survival evaluation of a new energy source". *Gynaec. Endoscopy*, 1998, 7, 85.
- [15] Awwad J. T., Isaacson K.: "The harmonic scalpel: an intraoperative complication". *Obstetrics and Gynecology*, 1996, 88, 718.
- [16] Cooper M. J., Cario G., Lam A. *et al.*: "Complications of 174 laparoscopic hysterectomies". *Australian and New Zealand J. of Obstet. and Gynaecol.*, 1996, 36, 36.
- [17] Shields P., Low-Beer T., Simms M. *et al.*: "Cardiac failure due to internal iliac arteriovenous fistula after laparoscopically assisted vaginal hysterectomy". *Gynaec. Endoscopy*, 1997, 6, 57.
- [18] Hardin C. D.: "Ruptured abdominal aneurysm occurring in Marfan's Syndrome". *New England J. of Med.*, 1958, 260, 821.
- [19] Auer A., Sauer D. C., Levin M.: "Iliac arteriovenous fistula following seat belt trauma". *Angiology*, 1974, 25, 21.
- [20] Holub Z., Voráček J., Kliment L. *et al.*: "Laparoscopic ultrasonic operative technique in surgery of women with endometrial cancer: a case report". *Clin. and Exp. Obstetrics and Gynecology*, 1999 (in press).
- [21] Holub Z., Jabor A., Fischlová D. *et al.*: "Assessment of tissue damage associated with laparoscopic and conventional hysterectomies". *Gynaec. Endoscopy*, 1998, 7, 243.
- [22] Ott D. E., Moss E., Martinez K.: "Aerosol exposure from an ultrasonically activated (Harmonic) device". *J. of the Am. Assoc. of Gynec. Laparos.*, 1998, 5, 29.

Address reprint requests to:  
Z. HOLUB, M.D.  
Department of Obstetrics and Gynaecology  
Baby Friendly Hospital  
Vančurova 1548  
27258 Kladno (Czech Republic)

## Endometriosis 2000 7th Biennial World Congress

LONDON 14-17 May, 2000

*at the QEII Conference Centre, under the auspices of the Royal College of Obstetricians & Gynaecologists*

### Local Organising Committee

David Barlow, D. Keith Edmonds, Robert W. Shaw (Co-Chairman), Stephen K. Smith, Christopher J. G. Sutton, Allan Templeton, Eric J. Thomas (Co-Chairman) and Angela Barnard (National Endometriosis Society).

### Provisional Scientific Programme

The scientific programme is expected to comprise three plenary sessions, four symposia or free paper sessions, two poster sessions and two video sessions. In addition it is envisaged that three will be two symposia sponsored by industry. Neither the plenary sessions nor the symposia will be run in parallel with any other session. The theme of the Congress is endometriosis. Pre- and post-Congress meetings are planned. The International Scientific Committee will be soliciting abstracts for the free paper, poster and video sessions – please do not send your abstract now as full details will be published in the Second Announcement.

### Topics will include

Pain; Evidence-based medicine; Infertility & endometriosis; Damage (including adhesion formation); Frontiers in research; Recurrent and distant endometriosis; Current controversies in endometriosis; New therapeutic agents.

The official language of the Congress will be English and simultaneous translation of the proceedings will not be provided.

Deadline for submission of abstracts: 21 January, 2000. Last date for early registration: 17 March, 2000

Congress days: 14-17 May, 2000

### Congress Secretariat:

CAROLINE RONEY MEDICAL CONFERENCE ORGANISERS  
Congress House, 65 West Drive, Cheam, Sutton, Surrey SM2 7NB, UK  
Tel. +44 (0) 181 661 0877 - Fax +44 (0) 181 661 9036 - E-mail: MedConfOrg@aol.com.