

# Recurrent pregnancy loss associated with endometrial hyperechoic areas (endometrial calcifications): a case report and review of the literature

V. Feyles<sup>1</sup>, M.D., Ph.D.; T. N. Moyana<sup>2</sup>, M.D.; R. A. Pierson<sup>1</sup>, Ph.D.

<sup>1</sup>Department of Obstetrics, Gynecology and Reproductive Sciences, College of Medicine, University of Saskatchewan, Saskatoon, SK;

<sup>2</sup>Department of Pathology, College of Medicine, University of Saskatchewan, Saskatoon, SK (Canada)

## Summary

Endometrial calcifications occur sporadically and are associated with infertility. Previous uterine trauma during instrumentation and/or uterine infection are likely involved in their pathogenesis. The association between endometrial calcifications and recurrent pregnancy loss has been very infrequently reported.

A 28-year-old woman with a history of two consecutive first trimester pregnancy losses presented with ultrasonographic hyperechoic endometrial areas associated with histologic endometrial calcification foci. A third pregnancy conceived before starting micronized oral progesterone supplementation also spontaneously aborted at eight weeks. During the fourth pregnancy, progesterone supplementation was taken for the initial 12 weeks. The endometrial lesions were no longer detectable and the pregnancy progressed to term without complications.

Endometrial calcifications, related to intrauterine bone tissue, have been previously treated with curettage or with endoscopic surgery, and to the best of our knowledge, have not been reported to disappear spontaneously. In this case, regression of the endometrial calcifications and a favorable pregnancy outcome occurred in concert with oral micronized progesterone supplementation. A combination of transvaginal ultrasonography and endometrial biopsy appears to be an effective method for diagnosing and monitoring of this rare condition.

**Key words:** Recurrent pregnancy loss; Endometrial hyperechoic areas; Endometrial calcifications.

## Introduction

Endometrial calcifications have been reported sporadically in relation to retained products of conception [1-9] or as osseous metaplasia, not caused by retention of fetal bones [10-14]. Non-osseous endometrial calcifications have been reported less frequently than uterine bone [15-17]. These lesions have been defined as "calcific endometritis" in association with Asherman's syndrome, a well-known condition predisposing to infertility and recurrent abortions [15, 16]. Microscopic diffuse calcific foci (psammoma bodies) not associated with intrauterine contraceptive devices (IUCD) or malignancy, have also been previously described in endometrial tissue [16, 17]. Their significance is unknown, but their association with infertility [16] suggests that they may compromise endometrial function. We report herein a case of non-osseous endometrial calcifications associated with recurrent miscarriage and their disappearance without surgical intervention, in concert with oral micronized progesterone supplementation during pregnancy.

## Case

A 28-year-old woman, gravida 2, para 0, abortus 2 presented with a history of two consecutive spontaneous abortions at six and eight weeks' estimated gestational age (EGA). Both pregnancy losses had been confirmed by ultrasonography and

managed with suction dilatation and curettage (D&C) in another hospital. There was no history of infertility or delay in conception. Menstrual cycles were regular and the medical history was otherwise unremarkable. Laboratory investigations: complete blood count (CBC), TSH, Prolactin, coagulation tests (APTT) were within normal limits. Karyotype was normal. Serologic tests for syphilis, anti-phospholipid (anticardiolipin G & M) and antinuclear antibodies were negative. Blood group and type were O Rh positive, with negative antibody screen. Previous cervical cultures had been positive for *Ureaplasma Urealyticum* and subsequently negative after oral antibiotic treatment. Cervical cultures for gonococcus and chlamydia were performed at presentation, based on the history of a previous presumed pelvic infection, treated with oral antibiotics. The cultures were negative. The uterine cavity appeared normal on hysterosalpingography.

The patient was referred to our institution for management of recurrent spontaneous abortions. At presentation, the physical examination showed no remarkable findings. Transvaginal ultrasonography (TVUS) was performed in order to complement the pelvic examination and previous investigations. The uterus was of normal size, anteverted and anteflexed, with no visible fibroids and unremarkable adnexae. The endometrium showed a uniform ultrasonographic pattern, desynchronized with the menstrual cycle and diffuse hyperechoic foci (Figures 1 & 2). Luteal phase endometrial biopsy (day 23 of natural menstrual cycle) showed a degenerate and necrotic decidua with diffuse foci of dystrophic calcifications (Figures 3 & 4).

A management plan was proposed, which consisted of oral luteal micronized progesterone supplementation 200 mg po three times daily (TID), with periodical reevaluation of the endometrium (by ultrasonography and repeat endometrial biopsy) prior to re-attempting conception. In spite of this plan,

Revised manuscript accepted for publication November 2, 1999

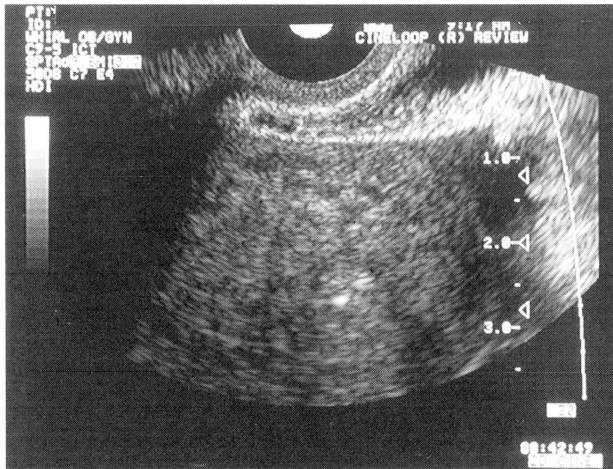


Fig. 1

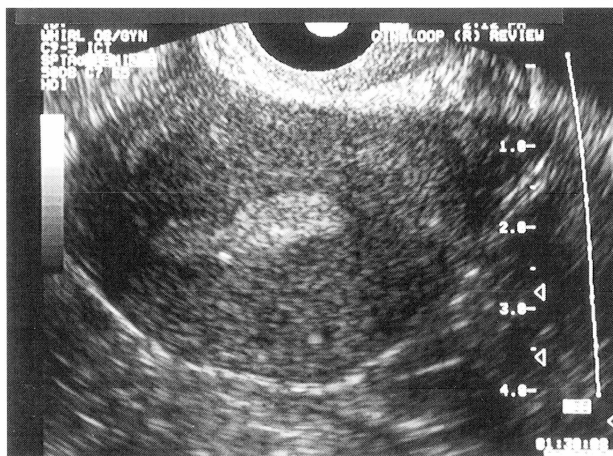

Fig. 2

Figure 1. — Transvaginal ultrasound image showing endometrium with hyperechoic foci and acoustic shadows, consistent with the presence of calcifications. Follicular phase.

Figure 2. — Transvaginal ultrasound image showing endometrium with hyperechoic foci and acoustic shadows, consistent with the presence of calcifications. Luteal phase.

the patient conceived immediately, before commencing progesterone. She started taking oral progesterone in the mid-luteal phase (day 24) of the conception cycle. TVUS showed a viable intrauterine pregnancy at six-weeks' gestation, which was spontaneously lost at eight weeks. Ultrasonographic examination done at six weeks of gestational age showed endometrial hyperechoic foci and acoustic shadows consistent with the presence of endometrial calcifications. The hyperechoic foci were consistent with those identified in the previous ultrasonography. The close proximity of some of the hyperechoic areas to the gestational sac was noted (Figure 5). The products of conception were expelled spontaneously. D&C was not performed.

In spite of further planning for a "preparation" period with luteal progesterone supplementation without conception, the patient conceived again the following cycle and started oral micronized progesterone 200 mg po three times daily in the early luteal phase (day 18) of the conception cycle. She elected to remain under the care of her family physician in her home town during the first trimester and declined monitoring at our center. She continued to take oral progesterone at the above dose and presented at our institute at approximately 12 weeks of gestation. TVUS showed a viable intrauterine pregnancy consistent with the estimated dates. The endometrial hypere-

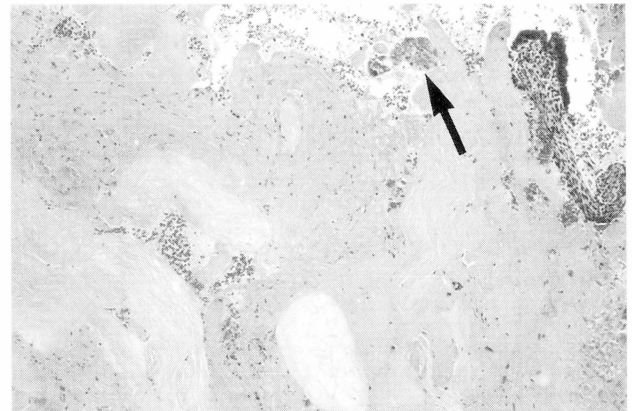


Fig. 3

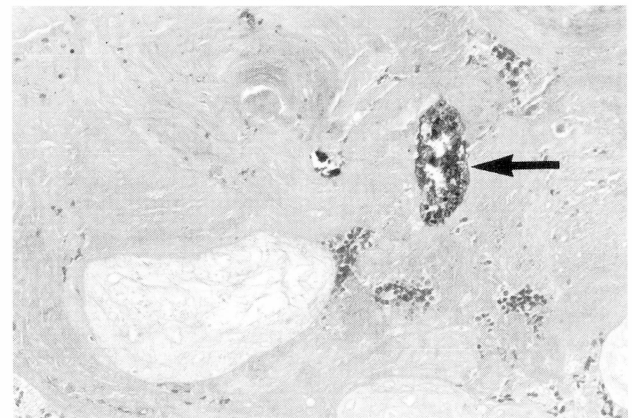


Fig. 4

Figure 3. — Photomicrograph of endometrial biopsy showing ghost-like outlines of necrotic decidua and/or degenerating chorionic villi. Note the foci of dystrophic calcification (arrows). Day 23 of cycle. Hematoxylin and eosin.

Figure 4. — High power view of another area showing degenerating decidua. There are also foci of dystrophic calcifications (arrow). Day 23 of cycle. Von Kassa stain.

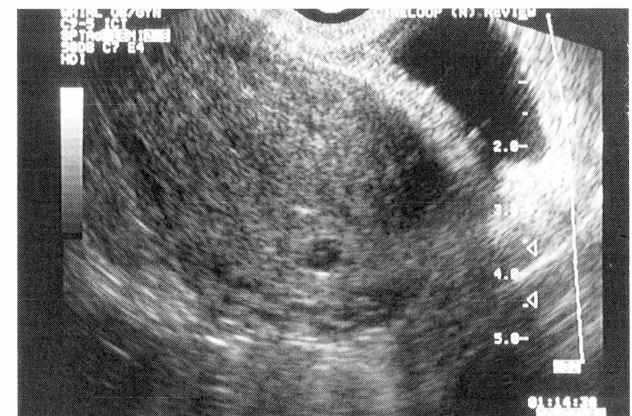

Figure 5. — Transvaginal ultrasound image showing an early intrauterine gestational sac and embryo (six week amenorrhea). The hyperechoic areas and acoustic shadows, consistent with the presence of calcifications, are still present.

choic areas were not visible and a decidual reaction appropriate for gestational age was seen by TVUS. Progesterone supplementation was stopped at this point since the pregnancy had presumably reached the point of luteo-placental shift in progesterone production [18]. The pregnancy progressed normally

and a healthy infant (3460 grams in weight, Apgar scores: 7 and 10) was delivered by C-section at term. The indication for C-section was a non-reassuring fetal heart rate during labor.

## Discussion

Endometrial calcifications and ectopic uterine bone tissue are infrequent findings; however, the presence of non-malignancy associated uterine bone tissue has been described in several case reports during the past 20 years [1-14, 19-28]. A frequently cited theory to explain endometrial ossification is the retention of fetal bones after miscarriage or elective termination of pregnancy [1-8]. Retention of fetal bone requires however a previous pregnancy of at least 12 weeks' gestation [1, 2, 12].

Endometrial calcifications and ectopic bone formations may also occur by metaplasia in association with chronic inflammation and tissue destruction, which are likely present after repeated spontaneous or therapeutic abortions [10-12]. Osseous metaplasia usually presents as diffuse, sporadic endometrial ossification without the tissue reaction frequently occurring around retained fetal tissue [1, 10]. Roth and Taylor postulated that the endometrial stroma is capable of cartilaginous metaplasia [29]. Another hypothesis is that heteroplasia may occur in the multipotential stromal cells present in the uterus thereby forming osseous tissue [1, 24].

A previous study described hyperechoic foci within the inner myometrium and immediately adjacent to the endometrium in women with a history of uterine instrumentation [30]. In a series of 240 women, these echoic foci were seen in 41% of patients with a history of D&C, 67% of patients with a history of endocervical biopsy, 2.5% of patients who had used an intrauterine contraceptive device and in only 1% of patients with no history of previous uterine instrumentation. It was speculated that the echoic foci could be the result of direct mechanical injury to the inner myometrium at the time of instrumentation, resulting in dystrophic calcifications or fibrosis [30].

In our case, the patient had a history of previous D&Cs, however, she did not recall any problems that would suggest endometritis following her D&Cs. We can only speculate that perhaps a clinically silent infection after the uterine instrumentation may have contributed to the endometrial abnormalities.

Progesterone supplementation has been utilized for treatment of luteal phase defects leading to implantation failure or to recurrent spontaneous first trimester abortion [18, 31]. The lack of large scale randomized trials confirming encouraging reports from other types of studies has raised some controversy about its use. A previous meta-analysis has shown promising results [31]. The attention of the medical community has been elicited and more clinical trials are in progress [32].

Previous reports have shown an association between endometrial ossification and infertility [2, 8, 11, 22, 24-26]. Only one previous case report described an association between endometrial ossification and repeated spontaneous abortions [21]. The patient carried a normal

pregnancy to term after repeat curettage of the uterus, which presumably led to removal of the ossified tissue [21]. This illustrates how ectopic endometrial bone (or other calcified tissue may sometimes allow implantation, only to cause failure of sustaining a pregnancy later on. More frequently, the ectopic tissue may act as an intrauterine contraceptive device [5] and this may possibly explain how intrauterine bone tissue (when present) appears to be more frequently associated with infertility than with recurrent miscarriage. In both cases however, the problem can sometimes be reversed by removal of the abnormal tissue, as suggested by the reported outcomes after treatment by hysteroscopy and/or D&C [10, 11, 24-26]. In our case, the disappearance of the ultrasonographic echoic areas associated with calcifications coincided with the concurrent normal course of the pregnancy to term, but the patient received no surgical treatment.

High resolution transvaginal ultrasonography (TVUS) may be used to identify and describe physiological changes of the endometrium which have been previously detected and monitored with relatively invasive methods [33-35].

There is currently limited information published on the incidence of echoic calcific foci in the endometrium and/or adjacent areas of the myometrium [30]. The incidence of endometrial calcified lesions in the general population, and in patients with recurrent miscarriage, is not known. However, the work of Burks *et al.* suggests that it may be significant in patients with previous uterine instrumentation [30].

Sampling errors and false negatives may occur, if endometrial biopsy alone is used as a screening method for this type of problem, especially when the lesions are small (as in our case) or when they are not uniformly distributed in the endometrium. Our case illustrates the advantages of associating TVUS to tissue diagnosis in the management of recurrent spontaneous abortion. To our knowledge all the previous publications on this rare condition address the issue of management by surgery, mostly endoscopic, to remove the abnormal tissue [1-5, 9-11, 13, 19, 22, 24-27, 29]. We report herein the resolution of recurrent spontaneous miscarriages associated with diffuse endometrial calcification foci in coincidence with oral progesterone supplementation. When calcified lesions are diffuse and located close to the myometrium, it may be difficult to remove large areas of the endometrium without predisposing the patient to uterine synechiae. One single case is clearly insufficient to show a beneficial effect of the progesterone; however, we speculate that progesterone supplementation may have a potentially favorable effect in patients with small diffuse endometrial calcifications, which would be difficult to treat surgically without extensive removal of endometrial tissue.

## References

- [1] Chan N. S. T.: "Intrauterine retention of fetal bone". *Aust. NZ J. Obstet. gynaecol.*, 1996, 36, 368.
- [2] Chanda M., Power S.: "Womb Stones". A case report and review of the literature. *Journal S.O.G.C.*, 1999, 21, 692.

- [3] Chervenak F., Hussein K. A., Neuwirth R. S.: "Symptomatic intrauterine retention of fetal bone". *Obstet. Gynecol.*, 1982, 59, 585.
- [4] Dawood M. Y., Jarret J. C.: "Prolonged intrauterine retention of fetal bones after abortion causing infertility". *Am. J. Obstet. Gynecol.*, 1982, 143, 715.
- [5] Dajani Y. F., Khalaf S. M.: "Intrauterine bone contraceptive device: an accident of nature". *Fertil. Steril.*, 1985, 43, 149.
- [6] Lewis V., Khan-Dawood F., King M., Beckmenn C., Dawood Y.: "Retention of intrauterine fetal bone increases menstrual prostaglandins". *Obstet. Gynecol.*, 1990, 75, 561.
- [7] Melius F. A., Julian T. M., Nagel T. C.: "Prolonged retention of intrauterine bones". *Obstet. Gynecol.*, 1991, 78, 919.
- [8] Moon H. S., Park Y. H., Kwon H. Y., Hong S. H., Kim S. K.: "Iatrogenic secondary infertility caused by residual intrauterine fetal bone after midtrimester abortion". *Am. J. Obstet. Gynecol.*, 1997, 176, 369.
- [9] Rodriguez B. D., Adamson G. D.: "Hysteroscopic treatment of ectopic intrauterine bone. A case report". *J. Reprod. Med.*, 1993, 38, 515.
- [10] Acharya U., Hamilton M. P. R.: "Osseous metaplasia of the endometrium treated by hysteroscopic resection". *Br. J. Obstet. Gynecol.*, 1993, 100, 391.
- [11] Bahceci M., Demirel L. C.: "Osseous metaplasia of the endometrium: a rare cause of infertility and its hysteroscopic management". *Hum. Reprod.*, 1996, 11, 2537.
- [12] Bathia N. N., Hoshiko M. G.: "Uterine osseous metaplasia". *Obstet. Gynecol.*, 1982, 60, 256.
- [13] Hsu C.: "Endometrial ossification". *British J. Obstet. Gynecol.*, 1975, 82, 836.
- [14] Shroff C. P., Kudterkar N. G., Badhwar V. R.: "Endometrial ossification - report of three cases with literature review". *Indian J. Pathol. Microbiol.*, 1985, 28, 71.
- [15] Herbold D. R., Magrane D. M.: "Calcifications of the benign endometrium". *Arch. Pathol. Lab. Med.*, 1986, 110, 666.
- [16] Untawale V. G., Gabriel J. B., Chauhan P. M.: "Calcific endometritis". *Am. J. Obstet. Gynecol.*, 1982, 144, 482.
- [17] Valicenti J. F., Priester S. K.: "Psammoma bodies of benign endometrial origin in cervicovaginal cytology". *Acta Cytol.*, 1967, 11, 199.
- [18] Gibson M.: "The endocrine factor". In: "Reproductive Endocrinology, Surgery and Technology". Adashi E. Y., Rock J. A., Rosenwaks Z. (eds). Lippincott Raven, Philadelphia, U.S.A., 1996, 2, 2275.
- [19] Bellingham F. R.: "Endometrial bone formation". *Aust. NZ. J. Obstet. Gynaecol.*, 1996, 36, 109.
- [20] Ceccacci L., Clancy G.: "Endometrial ossification: report of an additional case". *Am. J. Obstet. Gynecol.*, 1981, 141, 103.
- [21] Degani S., Gonen R., de Vries K., Shar M.: "Case report. Endometrial ossification associated with repeated abortions". *Acta Obstet. Gynecol. Scand.*, 1983, 62, 281.
- [22] Dutt S.: "Endometrial ossification associated with secondary infertility. Case report". *British. J. Obstet. Gynecol.*, 1978, 85, 787.
- [23] Ganem K. J., Parsons L., Friedell G. H.: "Endometrial ossification". *Am. J. Obstet. Gynecol.*, 1962, 83, 1592.
- [24] Marcus S. F., Bhattacharya J., Williams G. et al.: "Endometrial ossification: a cause of secondary infertility. Report of two cases". *Am. J. Obstet. Gynecol.*, 1994, 170, 1381.
- [25] Niccoli V., Carillo C., Caruso M. T., Lippa A., Serao L.: "Considerazioni clinico-diagnostiche su un caso di ossificazione endometriale quale causa di sterilità secondaria". *Minerva Ginecol.*, 1997, 49, 289.
- [26] Ombelet W.: "Endometrial ossification, an unusual finding in an infertility clinic. A case report". *J. Reprod. Med.*, 1989, 43, 303.
- [27] Taylor P. J., Hamou J., Mencaglia L.: "Hysteroscopic detection of heterotopic intrauterine bone formation". *J. Reprod. Med.*, 1988, 33, 337.
- [28] Waxman M., Moussouris H. F.: "Endometrial ossification following an abortion". *Am. J. Obstet. Gynecol.*, 1978, 130, 587.
- [29] Roth E., Taylor H. B.: "Heterotopic cartilage in the uterus". *Obstet. Gynecol.*, 1996, 27, 838.
- [30] Burks D. D., Stainken B. F., Burkhardt T., Balsara Z. N.: "Uterine inner myometrial echogenic foci. Relationship to prior dilatation and curettage and endocervical biopsy". *J. Ultrasound Med.*, 1991, 10, 487.
- [31] Daya S.: "Efficacy of progesterone support for pregnancy in women with recurrent miscarriage. A meta-analysis of controlled trials". *Br. J. Obstet. Gynecol.*, 1989, 96, 275.
- [32] Hill J. A.: "Immunotherapy for human implantation: standard of care or buyer beware". Presented at "Celebrating 20 years of ART: from cells and techniques to molecules and innovations". April 30-May 2, 1998, Chicago, USA.
- [33] Pierson R. A., Chizen D. R., Olatunbosun O. A.: "The role of ultrasonography in ovulation induction". In: "Imaging in infertility and reproductive endocrinology". Jaffe R., Pierson R. A., Abramowicz J. S., J. B. Lippincott Co., Philadelphia, U.S.A., 1994, 155.
- [34] Richards N. A., Pierson R. A.: "Transvaginal ultrasonography of the uterine decidual reaction in early pregnancy". *Ultrasound International*, 1996, 2, 174.
- [35] Wikland M., Hamberger L.: "The role of ultrasonography in oocyte retrieval for in vitro fertilization and other assisted reproductive technologies". In: "Imaging in infertility and reproductive endocrinology". Jaffe R., Pierson R. A., Abramowicz J. S., J. B. Lippincott Co., Philadelphia, U.S.A., 1994, 191.

Address reprint requests to:  
V. FEYLES, M.D., Ph.D.  
Department of Obstetrics,  
Gynecology & Reproductive Sciences  
103 Hospital Drive  
Saskatoon, SK, Canada, S7N 0W8