

Histopathological changes in the vagina of rats treated neonatally with clomiphene citrate

A. Önen¹, E. Deveci², M. Erdinç³

¹Dicle University Medical Faculty, Department of Pediatric Surgery

²Dicle University Medical Faculty, Department of Histology and Embryology

³Dicle University Medical Faculty, Department of Pharmacology (Turkey)

Summary

Clomiphene citrate is a nonsteroid antiestrogen which is widely used in the therapy of receptor-positive estrogen for the induction of ovulation. Clomiphene citrate was given subcutaneously to newly born rats with daily injections of 100 mg/kg for 5 days. Changes caused by the clomiphene citrate in vaginas of female rats were investigated at 28 and 35 days. Depending upon the effect of the clomiphene citrate, histopathological changes such as papillary development at keratinization, increase in vaginal epithelium, and observation of polygonal shaped nodular cells in stroma were considered as important findings. It should be emphasised that clomiphene citrate used for induction of ovulation caused these abnormalities in the vagina of rats.

Key words: Clomiphene citrate; Neonatal rat; Vagina; Histopathological changes.

Introduction

Antiestrogens inhibit the action of estrogen on its target organs by binding to the estrogen receptor [1, 2]. Therefore, antiestrogens are commonly used in the therapy of estrogen receptor-positive human breast cancer and for the induction of ovulation [3, 4].

Clomiphene citrate, a synthetic estrogen agonist-antagonist, has been extensively used in clinical medicine for the induction of ovulation in ovulatory women [5].

In the adult laboratory rat, clomiphene citrate causes cessation of the estrous cycle, suppresses gonadotropins and has antizygotic, antiimplantation and antiembryonic effects [5].

Although there are several reports demonstrating various effects of clomiphene citrate on the reproduction in laboratory rats, there are few studies on the effects of this drug in wild mammals [3].

Clomiphene citrate has estrogenic and teratogenic effects on the developing rat and human fetal genital tract [6, 7].

A set of abnormalities have been observed in the genital organs of the rats treated neonatally with antiestrogens; e.g. long lasting suppression of spermatogenesis, atrophy of testes and male accessory organs, adenosis-like lesions in the cervicovaginal epithelium, suppression of uterine glands and uterine hypoplasia and ovarian dysgenesis [8]. The present paper, therefore, deals with the histopathological changes in the vagina of rats treated neonatally with clomiphene citrate.

injections of 100 mg clomiphene citrate suspended in 0.02 ml of saline starting on the day of birth. The animals were killed by ketamine anesthesia at 28 and 35 days of age.

The dissected vagina tissue was fixed in 10% formaldehyde dehydrated and embedded in paraffin and then sectioned transversally at 4-6 µm. The resulting paraffin sections were stained with staining methods such as hematoxylin eosin, Masson trichrome and Van Gieson. The stained sections were observed under an illuminated microscope and photographed with a photomicroscope. The changes were histopathologically evaluated.

Results

The histopathological changes in rats treated neonatally with clomiphene citrate were examined in comparison to controls. Changes in the vagina of neonatally clomiphene citrate administered rats for 28 days included: i) epithelial hyperplasia; ii) distinct clear keratinization in the epithelium; iii) rare papillary formations in the vagina (Fig. 1). The accumulation of cells in free nature of basal membrane and polygonal cells were observed as nodular shapes beneath the epithelium (Fig. 2). In contrast the epithelium and under-lying connective tissue appeared to be normal in the corresponding controls (Fig. 3). Keratinization increased in multilayer squamous epithelium and an accumulation of cells in free nature of the basal membrane beneath the epithelium (Fig. 4), and gland-like formations beneath the basal layer were encountered in a rat given clomiphene citrate for 35 days (Fig. 5).

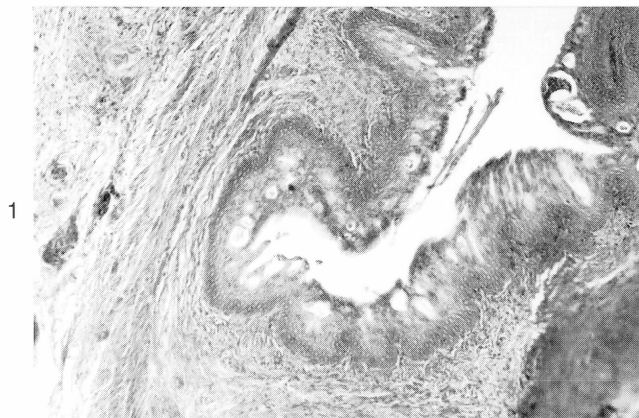
Whereas in another rat given clomiphene citrate for 35 days, there was keratinization in the epithelium and an increase in papillary development (Fig. 6). In addition, there was a slightly clear lumen in the middle of the connective tissue which seemed similar to a gland structure (Fig. 5). Cell accumulations were not found in the age-matched controls and similar changes were not observed in the age-matched control section (Fig. 7).

Materials and Methods

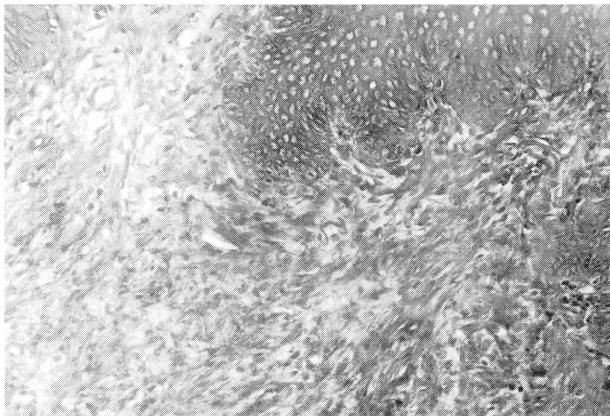
Rats were kept at room temperature in animal houses (four groups of female litters, 28 day and 35 days old). Treated rats and the corresponding controls were subcutaneously given daily

Received August 6, 1997

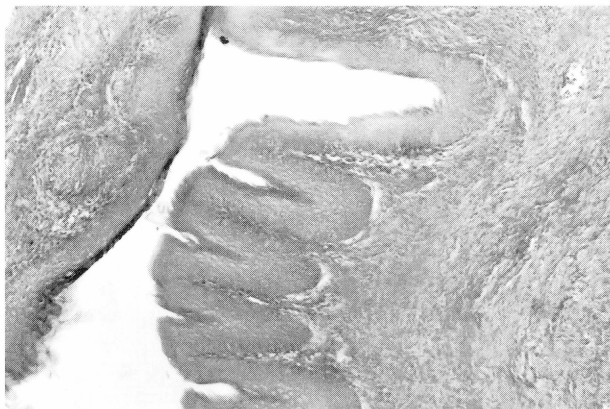revised manuscript accepted for publication September 15, 1997



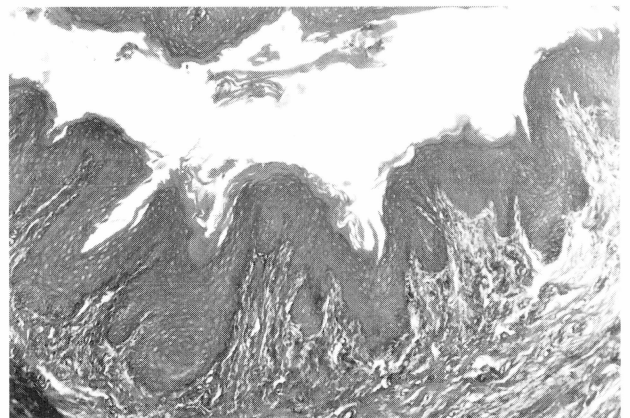
1



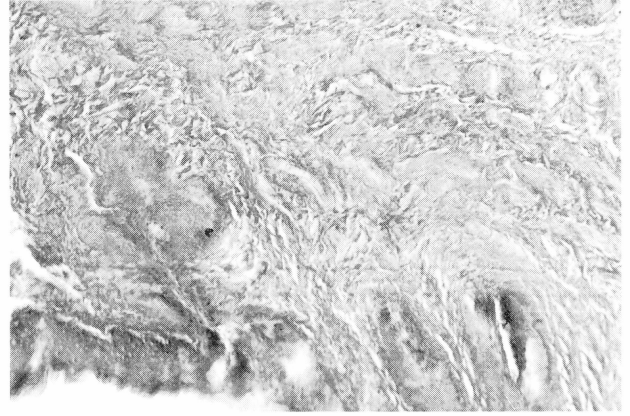
2



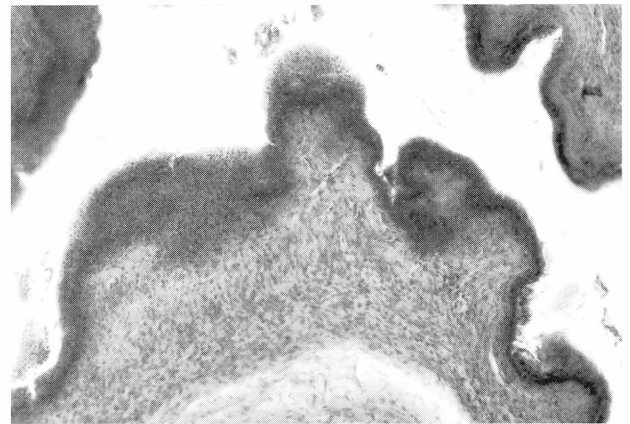
3



4



5



6

Figure 1. — Proliferation in epithelium, at given clear keratinization and papillary development in the vagina of 28-day-old clomiphene citrate (indicated by thin arrow): Hematoxylin-Van-gission original magnification x 41.

Figure 2. — Hypertrophy in cells and polygonal cells in nodular shapes (indicated by thick arrow). The accumulation of cells in free nature at basal membrane (indicated by thin arrow) in the vagina of 28 day-old at given clomiphene citrate: Masson 3 original magnification x 82.

Figure 3. — The epithelium and stroma of a vagina in a 28-day-old control rat: H-E original magnification x 41.

Figure 4. — The vagina of a 35-day-old rat given clomiphene citrate injections. Proliferation in epithelium and increased papillary development (indicated by thick arrow): H-E original magnification x 41.

Figure 5. — The vagina of a 35-day-old rat given clomiphene citrate injections. Hypertrophy in cells and polygonal cells in nodular shapes (indicated by thick arrow) and an increase in keratinization in epithelium (indicated by thin arrow): Masson 3 original magnification x 41.

Figure 6. — The vagina of a 35-day-old rat given clomiphene citrate injections. Gland-like formation beneath basal layer (indicated by thick arrow): Hematoxylin-Van-gission original magnification x 41.

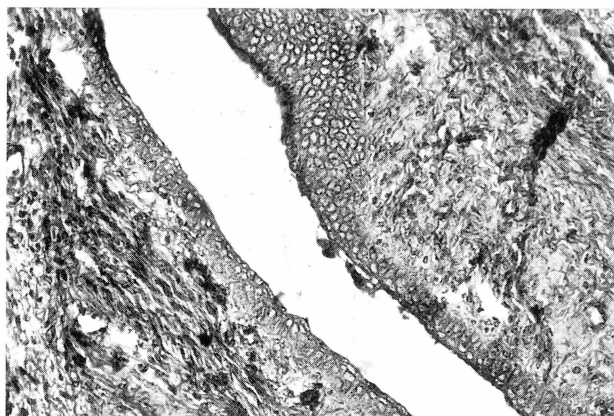


Figure 7. — The epithelium and stroma of a 55-day-old control: Masson 3 original magnification x 1641

Discussion

Female rats and mice exposed perinatally to sex hormones and antiestrogens were affected by an ovulatory syndrome after puberty, showing persistent vaginal cornification due to permanent alternations of the hypothalamo-hypophysis-ovarian system, as exogenous gonadotropins can induce ovulation in these animals [7, 8]. Clomiphene citrate has an estrogenic action on the reproductive tracts of various animals including mice [9]. Clomiphene and tamoxifen elicit changes in the human fetal vagina comparable to those of diethylstilbestrol (DES) [7]. The present study is in agreement with the study carried out by Iquchi *et al.* [8] indicating that nodular-like cell clusters near the basal membrane occur in rats given clomiphene citrate.

An important finding in the present study was the observation of papillary development at 28 days (Fig. 1) and also an increase in cells in free nature of the basal membrane between 28 and 35 days – depending upon the effects of clomiphene citrate. Vaginal adenosis is occasionally observed in DES treated specimens [10], but has not been observed in clomiphene or tamoxifen-treated specimens [7]. The results however may solely be a func-

tion of the small number of specimens treated with these drugs. Previous studies have demonstrated that adenosis-like formations depending upon the effects of the antiestrogen, occurred particularly in the vaginal fornix and cervico-vaginal regions [8, 11]. The formation of vaginal adenosis observed in our study, though to a smaller extent, is in agreement with previous studies.

We conclude that clomiphene citrate, which is one of the antiestrogens used for induction of ovulation, had positive effects on estrogen receptors and caused some histopathological changes in tissues.

References

- [1] Harper M. J. K., Walpole A. L.: "A new derivative of triphenylethylene: effect on implantation and mode of action in rats". *J. Reprod. Fertil.*, 1967, 13, 101.
- [2] Black L. J., Goode R. C.: "Uterine bioassay of tamoxifen, trioxifene and a new estrogen antagonist (LY117018) in rats and mice". *Life Sci.*, 1980, 26, 1453.
- [3] Hippert L. C.: "Induction of ovulation with clomiphene citrate". *Fertil. Steril.*, 1979, 31, 1.
- [4] Clark J. *et al.*: "The agonistic-antagonistic properties of clomiphene, a review". *Pharmacol. Ther.*, 1982, 15, 467.
- [5] Sahu A.: "Effect of clomiphene citrate on the ovary of a wild rat, *Bandicota bengalensis*". *Acta Anat.*, 1987, 129, 248.
- [6] Clark J. H., McCormack S. A.: "The effect of clomid and other triphenylethylene derivatives during pregnancy and the neonatal period". *J. Steroid. Biochem.*, 1980, 12, 47.
- [7] Cunha G. R. *et al.*: "Teratogenic effects of clomiphene tamoxifen, and diethylstil bestrol on the developing human female genital tract". *Human. Pathol.*, 1987, 18, 1132.
- [8] Iquchi T., Todoroki R., Yamaguchi S.: "Changes in the uterus and vagina of mice treated neonatally with antiestrogens". *Acta Anat.*, 1989, 136, 146.
- [9] Chou Y. C. *et al.*: "Effects of antiestrogens on adult and neonatal mouse reproductive organs". *Rep. Toxicol.*, 1992, 6, 439.
- [10] Robboy S. J., Taquchi D.: "Normal development of the human female reproductive tract and alterations resulting from experimental exposure to diethylstilbestrol". *Hum. Pathol.*, 1982, 13, 190.
- [11] Nguyen B. L. *et al.*: "Estrogen and progesterone receptors in the fetal and newborn vagina of a guinea pig. Biological morphological and ultrastructural response to tamoxifen and estradiol". *Endocrinologica*, 1987, 129, 901.