

Transvaginal Doppler ultrasound with color flow imaging in the diagnosis of luteal phase defect (LPD)

D. Kalogirou, G. Antoniou, D. Botsis, A. Kontoravdis, N. Vitoratos, L. Giannikos¹

²2nd Department of Obstetrics and Gynecology, "Areteion" Hospital, University, Athens

¹Department of Gynecology, "Laiko" General Hospital, Athens - Greece

Received November 12, 1996; revised manuscript accepted for publication February 25, 1997

Summary

Objective: Our purpose was to determine whether color flow pulsed Doppler could predict a luteal phase defect (LDP).

Method: Twenty-one women with regular menstrual cycles and at risk for luteal phase defect were examined by transvaginal color Doppler during the follicular and luteal phase of the menstrual cycle. Progesterone was measured on the day of the Doppler exam. Ovulation was determined from the luteinizing hormone (LH) surge. Endometrial biopsy during the late luteal phase was performed on each patient.

Result: Six patients (28.5%) were diagnosed with luteal phase defect. Mean resistance index in patients with luteal phase defect was significantly higher only throughout the luteal phases ($p=0.02$). Mean progesterone levels were significantly lower for patients with LPD than for normal women ($p<0.001$). Mean pulsatility index in luteal phase deficient cycles was significantly higher throughout the follicular and luteal phases ($p=0.03$).

Conclusion: Color Doppler may aid in assessing luteal phase adequacy. Doppler indices of corpus luteum blood flow in combination to plasma progesterone may be a useful index of luteal function.

Key words: Color Doppler; Luteal phase defect; Pregnancy loss.

Introduction

The clinical importance of the corpus luteum for successful establishment of pregnancy is strongly supported by many lines of investigation. Any breakdown or defect in the corpus luteum function can affect endometrial maturity and its ability to support an early pregnancy. The clinical manifestation of such a dysfunction is luteal phase insufficiency or deficiency presenting as infertility or early pregnancy wastage [1]. The mechanisms underlying the pathogenesis of corpus luteum defect include an imbalance between FSH and LH levels during the follicular phase [2], abnormal LH secretion during the luteal phase [3], thyroid dysfunction [4], hyperprolactinemia [5]. Other mechanisms are a possible role of corpus luteum LH/hCG [6], and progesterone receptors [7].

The advent of color Doppler imaging in combination with high-resolution transvaginal ultrasonography has extended the use of ultrasound imaging to the functional evaluation of the female reproductive tract. Transvaginal color Doppler imaging provides the ability to detect blood flow in vessels that cannot be visualized with conventional real-time gray-scale imaging [8]. Because of the ability to detect flow in very small vessels, the investigator can now perform velocity measurements accurately, and flow velocity waveforms of different regions within the ovaries can be analyzed and characterized [9]. The aim of this study was to determine whether color flow Doppler analysis of corpus luteum blood flow in normal cycles differs from cycles with a luteal phase defect.

during the period 1994-1995. All study patients gave a history of regular menstrual cycles, had no prior uterine or adnexal surgery and were not receiving any medications. All subjects were volunteers and enrolled in the study after informed consent was obtained. We tried to include women who would be at increased risk for luteal phase defect: eight patients with unexplained infertility, ten women with age >35 years and three with recurrent pregnancy loss. Color pulsed Doppler evaluation and blood sampling was carried out in two consecutive nonstimulated cycles.

Color Doppler imaging was performed by a single observer (A.K.) using a model machine Toshiba ECO CEE SAA-340A with a 3.5 MHz transvaginal transducer. The wall filter setting was optimized for low frequency signals from the small low velocity vessels being studied. The color gain was gradually increased until blood flow was detected. The sample volume of the pulsed Doppler was guided to the region of detected flow, and three to four measurements of flow velocity waveforms were performed from several sites. The resistance index (RI) and the pulsatility index (PI) were measured for each examined area. The RI was calculated as systolic peak minus diastolic peak divided by systolic peak. The pulsatility index (PI), defined as the difference between peak systolic and end-diastolic flow velocity divided by the mean flow velocity, was also measured. Both ovaries were examined in each patient and the lowest value from the highest amplitude signal was used in analysis.

Venous blood was obtained from each patient on the day of Doppler examination. Progesterone was measured by RIA kits (Diagnostics Products Corporation, Los Angeles, CA). All samples were assayed in duplicate. The interassay and intra-assay coefficients of variation (CVs) were 6.8% and 2.3%, respectively. The serum progesterone levels were determined in the midluteal phase. Ovulation was determined from the LH surge. Endometrial biopsy was performed in the late luteal phase with a Gynoscann sampling device [10] and evaluated according to the criteria of Noyes *et al.* [11]. The Noyes' criteria were based on an assumed hypothetical luteal phase of 14

Materials and Methods

Twenty-one patients were seen at the Department of Reproductive Endocrinology at the "Areteion" Hospital of Athens

days, with the next menstrual period used as a reference point against which dating is counted backwards. Biopsies were considered out of phase if they were dyssynchronous by ≥ 2 days in relation to the day of the LH surge. The definition of luteal phase defect required two consecutive cycles of out-of-phase endometrium.

The resistance and pulsatility index of both ovaries was recorded at five time points: early follicular (cycle days 4 to 7); late follicular (cycle days 9 to 12); early luteal (LH plus 2 to 4 days) + mid luteal (LH plus 5 to 8 days) and late luteal (LH plus 9 to 12 days). Statistical analysis was made using student t-tests and differences between dominant and nondominant ovaries were examined using repeated measures analysis of variance (ANOVA). Statistical analysis was determined using $p < 0.05$.

Results

All the women were ovulatory. The ovaries in the 21 women contained a sonographically visible dominant follicle and corpus luteum. There was no difference between age (34.1 ± 0.09 in women with luteal phase defect versus 31.5 ± 3.1 years in women with a normal cycle). Follicular phase length (14.7 ± 1.5 versus 13.9 ± 0.9 days) and luteal phase length (12.5 ± 0.7 versus 12.6 ± 0.6 days) between patients with luteal phase defect (LPD) and women with normal cycles did not show any difference. Of the 21 ovulatory women, six (28.5%) were diagnosed with corpus luteal insufficiency and 15 (71.5%) had a normal cycle. Biopsy dating of the cycle was out-of-phase in all the patients with luteal phase defect.

Resistance index of intraovarian blood flow in luteal phase deficient cycles and normal cycles is shown in Table 1. No statistically significant differences in the two groups were observed. The mean resistance index in the dominant ovary was significantly lower than the nondominant ovary in cycles of normal women (0.54 versus 0.66, $p = 0.001$). The same results of mean resistance index were found in cycles of women with LPD (0.50 versus 0.62, $p = 0.001$). Mean progesterone levels were significantly lower for patients with LPD than for normal women ($p < 0.001$).

Pulsatility index of intraovarian blood flow in luteal phase deficient cycles and normal cycles is shown in Table 2. Mean pulsatility index in women with luteal phase defect was significantly higher compared with normal women throughout the follicular and luteal phases ($p = 0.03$). High correlations were observed between progesterone and pulsatility index within each of the luteal time points, achieving its highest value during the midluteal phase ($r = -0.85$, $p < 0.01$).

Resistance index of intraovarian blood flow over the menstrual cycle is shown in Figure 1. Mean resistance index in patients with luteal phase defect was significantly higher compared with normal women throughout the luteal phases ($p = 0.02$) but not throughout the follicular phases ($p = 0.37$).

Discussion

A review of the literature indicates an increase of healthy skepticism about the prevalence rate of luteal phase deficiency, its contribution to infertility, and the reliability and precision of the two most widely employed

Table 1. — Resistance index results in the two groups

	Resistance index ^a	
	Luteal phase defect (n=6)	Normal (n=15)
Early follicular	0.65 ± 0.08	0.61 ± 0.04
Late follicular	0.62 ± 0.06	0.52 ± 0.04
Early luteal	0.63 ± 0.08	0.45 ± 0.03
Midluteal	0.63 ± 0.01	0.50 ± 0.04
Late luteal	0.60 ± 0.06	0.54 ± 0.04

^a $p = 0.02$, repeated measures ANOVA

Table 2. — Pulsatility index of intra-ovarian blood flow in the two groups*

	Pulsatility index ^a	
	Luteal phase defect (n=6)	Normal cycles (n=15)
Early follicular	1.15 ± 0.81 (1.04 to 1.92)	0.98 ± 0.05 (0.90 to 0.90)
Late follicular	1.07 ± 0.04 (1.02 to 1.06)	0.85 ± 0.08 (0.75 to 0.60)
Early luteal	1.10 ± 0.01 (1.02 to 1.10)	0.80 ± 0.03 (0.75 to 0.02)
Midluteal	1.05 ± 0.64 (1.00 to 1.12)	0.67 ± 0.02 (0.57 to 0.77)
Late luteal	1.02 ± 0.68 (0.99 to 1.17)	0.75 ± 0.05 (0.70 to 0.46)

Values are means \pm SEM with ranges in parentheses

^a $p = 0.03$, repeated measures ANOVA

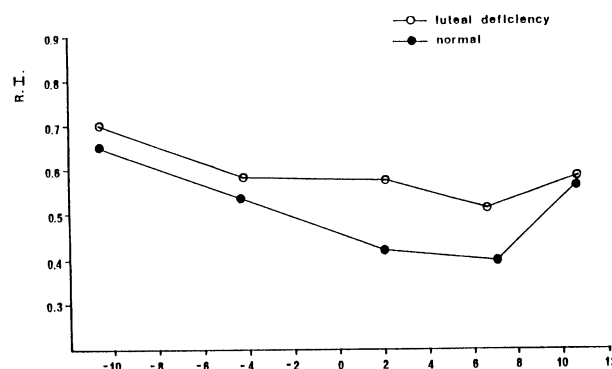


Figure 1. — Resistance index over the menstrual cycle shown for the normal (n=15) and luteal phase defect (n=6) groups. The normal group was significantly lower than the LPD group ($p = 0.02$, repeated measures ANOVA), only in the luteal phase.

methods of assessment, namely endometrial histological dating and single or random multiple serum progesterone measurements [12]. Therefore, overestimation and overdiagnosis of luteal phase deficiency are common. Integrated luteal progesterone remains the most reliable method of assessing corpus luteal function, even though largely confined to research.

The use of transvaginal ultrasonography has been evaluated as a noninvasive method of assessment of luteal phase endometrium. Although a trend toward a more echogenic image has been associated with normal histologic studies, the discriminatory power of ultrasonography as a diagnostic test for luteal phase deficiency is poor [13]. Therefore, at present, ultrasonographic appearance is a useful aid to confirm that secretory transformation has occurred, but it cannot replace endometrial biopsy as a

method of evaluating luteal phase adequacy.

A new method, color flow pulsed Doppler may serve as a new noninvasive diagnostic test of luteal function [14, 15]. Inadequate vascularization of the corpus luteum has been implicated as a possible cause of inadequate progesterone production and luteal phase deficiency. Using color Doppler, we were able to distinguish the ovary containing the active corpus luteum from the inactive ovary. Changes in intraovarian vascularity could usually be observed as a fluctuating area of color (typically as a 'ring of fire' image) and the resistance index or pulsatility index derived from the velocity waveform provided a quantitative estimation of blood flow impedance [15]. The results of this study have shown a significant difference in intraovarian blood flow impedance between luteal phase deficiency and normal cycles.

It has been suggested that the absence of luteal blood flow might be inconsistent with a normal pregnancy [16]. Since an increased impedance to blood flow reflects some reduction in the blood flow, one might speculate that this reflects a reduction in corpus luteum function that is incompatible with normal pregnancy. Is decreased corpus luteum blood flow potential cause or consequence of the disease? This remains unclear. Baber *et al.* showed that there was no pregnant patient after IVF-ET who had an RI from corpus luteum neovascularization greater than 0.50. They presumed normal corpus luteum activity with RI to blood flow below 0.50 [17].

Recently, some authors, reported finding only 10 of 141 (7.1%) infertility patients with luteal phase deficiency as determined by an out-of-phase endometrial biopsy of >2 days [18]. In another study, luteal phase deficiency was reported in 7 of 34 (21%) women who either were normal or were being evaluated for infertility or recurrent pregnancy loss. Their diagnosis was based on an integrated luteal progesterone of <80 ng/mL [19]. Our patient population resulted in the identification of six women with this disorder (28.5%). Our diagnosis was strengthened by finding significantly lower progesterone concentrations in the early and late luteal phases of these same patients compared with normal subjects.

Our results do show clear differences in resistance index and pulsatility index between LPD patients and patients with normal cycles and suggest a relative decrease in vascularization of the corpus luteum in LPD subjects compared with normal subjects. We believe that a discriminatory value for the resistance index, above LPD can be diagnosed as RI = 0.55, but our limited number of study subjects prevents us from providing a discriminatory value for the pulsatility and resistance index above which LPD can be diagnosed with certainty.

The findings of this study suggest the possibility of using the resistance and pulsatility index of corpus luteum blood flow as an adjunct to plasma progesterone assay as an index of luteal function. However, a precise role for color Doppler evaluation of corpus luteum vascularization has yet to be defined. The clinical assessment of luteal phase deficiency relies on either histologic dating of endometrial biopsies or measurement of serum progesterone levels. In time, it is hoped that color

Doppler analysis will offer a tool for predicting the outcome of luteal function.

References

- [1] Dawood M. Y.: "Corpus luteal insufficiency". *Current Opinion in Obstetrics and Gynecology*, 1994, 6, 121.
- [2] Mc Neely M. J., Soules M. R.: "The diagnosis of luteal phase deficiency: a critical review". *Fertil. Steril.*, 1988, 50, 1.
- [3] Soules M. R., Steiner R. A., Clifton D. K., Bremner W. J.: "Abnormal patterns of pulsatile luteinizing hormone in women with luteal phase deficiency". *Obstet. Gynecol.*, 1984, 63, 626.
- [4] Maruo T., Katayama K., Barnea E. R., Mochizuki M.: "A role for thyroid hormone in the induction of ovulation and corpus luteum function". *Horm. Res.*, 1992, 37, (suppl. 1), 12.
- [5] Del Pozo E., Wyss H., Tolis G., Alcaniz J., Campana A., Naf-tolin F.: "Prolactin and deficient luteal function". *Obstet. Gynecol.*, 1979, 53, 282.
- [6] Yeko T. R., Khan-Dawood F. S., Dawood M. Y.: "Luteinizing hormone and human chorionic gonadotropin receptors in human corporea lutea from clomiphene citrate-induced cycles". *Fertil. Steril.*, 1990, 54, 601.
- [7] Hecht B. R., Khan-Dawood F. S., Dawood M. Y.: "Periimplantation phase endometrial estrogen and progesterone receptors: effect of ovulation induction with clomiphene citrate". *Am. J. Obstet. Gynecol.*, 1989, 161, 1688.
- [8] Kurjak A., Kupesic S.: "Transvaginal color Doppler and pelvic tumor vascularity: lessons learned and future challenges". *Ultrasound Obstet. Gynecol.*, 1995, 6, 145.
- [9] Bourne T. H.: "Transvaginal color Doppler in gynecology". *Ultrasound Obstet. Gynecol.*, 1991, 1, 359.
- [10] Hansen P. K., Juge J., Roed H., Fisher-Rasmussen W., Hojgaard K.: "Endometrial cell sampling for cytological assessment of endometrial pathology". *Acta Obstet. Gynecol. Scand.*, 1986, 65, 397.
- [11] Noyes R. W., Hertig A. T., Rock J.: "Dating the endometrial biopsy". *Fertil. Steril.*, 1950, 1, 3.
- [12] Batista M. C., Cartledge T. P., Merinx M. J., Axiotis C., Plattia M. P., Merriam G. R. *et al.*: "Midluteal phase endometrial biopsy does not accurately predict luteal function". *Fertil. Steril.*, 1993, 59, 294.
- [13] Doherty C. M., Silver B., Binor Z., Molo M. W., Radwanska E.: "Transvaginal ultrasonography and the assessment of luteal phase endometrium". *Am. J. Obstet. Gynecol.*, 1993, 168, 1702.
- [14] Kawai M., Kano T., Kikkawa F., Maeda D., Oguchi H., Tomada Y.: "Transvaginal Doppler ultrasound with color flow imaging in the diagnosis of ovarian cancer". *Obstet. Gynecol.*, 1992, 79, 163.
- [15] Fleischer A. C., Rodgers W. H., Rao B.: "Assessment of ovarian tumor vascularity with transvaginal color doppler sonography". *J. Ultrasound Med.*, 1991, 10, 563.
- [16] Taylor K. J. W., Ramos I. M., Feyock A. N., Snower D. P., Carter D., Shapiro B. S.: "Ectopic pregnancy: Duplex Doppler evaluation". *Radiology*, 1989, 173, 93.
- [17] Baber R. J., McSweeney M. B., Gill R., Porter R., Picker R., Warren P. S.: "Transvaginal pulsed Doppler ultrasound assessment of blood flow to the corpus luteum in IVF patients following embryo transfer". *Br. J. Obstet. Gynecol.*, 1988, 95, 1226.
- [18] Nakajima S. T., Molloy M. H., Oi R. H., Ohlson K. A., Azevado R. A., Boyers S. P.: "Clinical evaluation of luteal function". *Obstet. Gynecol.*, 1994, 84, 219.
- [19] Jordan J., Craig K., Clifton D. K., Soules M. R.: "Luteal phase defect: the sensitivity and specificity of diagnostic methods in common clinical use". *Fertil. Steril.*, 1994, 62, 54.

Address reprint requests to:
ANTONIOU GEORGE
2, Diamantidou str.
P. Psychico 154 52
Athens (Greece)