

A rare case of IUD tubal migration

Case report

A. AZZENA - F. VASOIN - P. PELLIZZARI - F. QUINTIERI - R. ANGARANO

Summary: The Authors describe a rare case of IUD tubal migration. The uterine device had been inserted twelve years before. A hysteroscopic removal of the IUD was tried unsuccessfully, because it was impossible to locate it either in the uterine cavity or at the fallopian tube orifice level. The patient underwent a minilaparotomy and the IUD was found out at the peritubal level.

An ecographic control of all intrauterine devices insertions is recommended.

Key words: IUD; Contraception; IUD migration; Tubes.

INTRODUCTION

The use of mechanical contraceptive methods, such as the intrauterine device has become widely extended and nowadays about 60 million women worldwide are using the IUD because of its high efficiency, extremely easy use and the almost total lack of "systemic" side-effects (^{1, 2}). Intrauterine devices may, however, elicit "local" side-effects, sometimes as severe as: dysmenorrhea, abdominal pain, uterine bleeding, perforations, displacements and infections, which may preclude future fertility of the IUD users. Perforation occurs mostly during the insertion of the IUD; sometimes it is only partial and causes a further extension, with the aid of uterine muscular contractions. The incidence of perforation may vary from

1:350 to 1:2500 and is in relation to the shape, stiffness and size of the device, the uterine morphology, the technique of insertion and, not least, to the experience of the physician (^{3, 4}). According to the seat, three types of uterine perforations may be encountered: cervical, isthmic and fundal.

Cervical perforation has an incidence of 1:600 - 1:1000, generally occurs with long, vertical armed devices and is frequently clinically silent. The isthmic perforation is most frequently reported in women with uterine retroversion. Finally, the fundal perforation (1:1000 cases) mostly occurs in the puerperal period and is due to the "over penetration" of the device, during its insertion, through the uterine wall, soft and non resistant (⁵).

Expulsion of the IUD occurs in about 1 case in 5 (^{3, 4}). The incidence of this side-effect is high during the first menstruation and decreases proportionally with age and parity (⁵). It is still hypothetical that expulsion may either migrate through the cervical canal or the fallopian

Department of Obstetrics and Gynaecology
of Padua University

All rights reserved — No part of this publication may be reproduced or transmitted in any form or by any means, electronic or mechanical, including photocopy, recording, nor any information storage and retrieval system without written permission from the copyright owner.

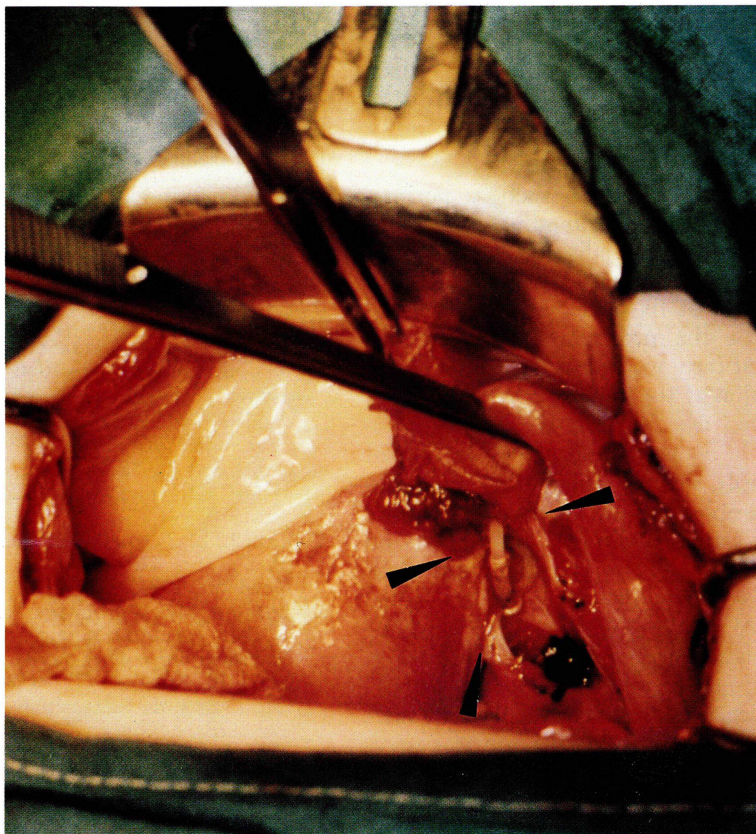


Fig. 1. — Right peritubal abscess with the horizontal arm of the device among tubal fimbrias.

tube, but this last possibility has only twice been described in medical literature (^{6, 7}).

CLINICAL CASE

B.E., 37 years old, with a surgical history of appendicectomy and an obstetrical gynaecological history including: menarche at 13 years old, para 2002, 2 normal deliveries (the last one in 1981), was admitted to our Institute for pelvic pains, being an IUD user. The uterine device was inserted 12 years ago and underwent myometrial displacement from the beginning, therefore the patient periodically took oral contraceptives. A hysteroscopic removal of the IUD was tried unsuccessfully, because it was impos-

sible to locate the device either in the uterine cavity or at the fallopian tube orifice level. A further echotomographic investigation was able to locate the device, in the parauterine right level. Therefore, we proceeded to minilaparotomy with a Pfannestiel incision. After the peritoneal incision, an abscess zone of about 3-4 cm was revealed at the right peritubal level; viscerolysis (adherent syndrome post appendicectomy), opening and drainage of the abscess were performed; the following purulent liquid was collected and sent for the microbiological analysis, which did not diagnose specific infections. The abscess also included some tubal fimbrias and the horizontal arm of the device (ML cu 250); the vertical arm proved to be still located inside the fallopian tube, at the ampullar level (Fig. 1). Observation of the nearby organs did not reveal any lesion or organic injury.

After an accurate pelvic cleansing, the fallopian tube, perfectly integral, was conserved. The patient was treated with antibiotics for 8 days and the postoperative period was without any complications.

DISCUSSION

Besides complications such as perforations and expulsion, sometimes intrauterine devices may be displaced inside the uterine cavity or may cause an "embedding", a fit of the IUD arm into the thickness of the myometrium⁽²⁾. In this particular case, we found a very rare tubal localisation of the device. Only two cases have been described in the entire literature^(6,7). It was hypothesised, in one of these cases, that a similar tubal migration was possible only in a single-horizontal smooth arm IUD (nova T type)⁽⁶⁾; on the contrary, in our case a double horizontal bent arm device with two extensions (ML cu type) was used, which shape should have made migration difficult. A perforation with displacement of the IUD at the tubal level could be excluded, since careful observation did not reveal any organic or pelvic lesion. Such migration through the tubal-uterine joint may be explained only by an earlier mistaken insertion of the device, near the uterine cornual zone.

In order to avoid such complications, it is therefore recommended that an echo-

graphic control of the insertion be performed with an adequate follow-up of these patients.

REFERENCES

- 1) FIGO manual of human reproduction: "Contraccezione intrauterina". Ed. Trustees New York, 1990, 67(4).
- 2) Pescetto G., De Cecco L., Pecorari D., Ragni N.: "Manuale di ginecologia e ostetricia". Il Controllo della fertilità. Ed. Universo Roma, 1989, 315(1).
- 3) Zakin D., Stern W., Rosenblatt R.: "Complete and partial uterine perforation and ambedding following insertion of intrauterine devices. Classification, complications, mechanism, incidence and missing strings". *Obst. Gyn. Surv.*, 1981, 36, 335.
- 4) Guilleband J.: "Scheme for the management of lost IUD threads". *IPPF Medical Bulletin*, 1980, 14, 5.
- 5) Zichella L., Perrone G.: "Controllo della fertilità". In: 'Ginecologia e Ostetricia' Ed. Monduzzi, 1987, 765(36).
- 6) Wikland M., Wilhelmson L.: "A rare case of IUD expulsion through the fallopian tube". *Acta Obst. Gyn. Scand.*, 1983, 62, 191.
- 7) Greci P., Menozzi G.: "Caso di lost IUD con risalita del dispositivo nella salpinge". *Riv. Ost. e Ginec. Prat. e Med. Perinat.*, 1993, 8(69), 4.

Address reprints requests to:

A. AZZENA
Clinica Ostetrica Ginecologica
Istituto G.B. Revoltella
Via Giustiniani, 3
Padova (Italy)