

Cystic adenomatoid malformation of fetal lung

Case report

J.C. VOIGT

INTRODUCTION

Cystic adenomatoid malformation of fetal lung is an interesting rare pathology. The aetiology is discussed; we report 2 cases.

CASE REPORT

Case 1

Our patient was a 34 year old woman who had previously had 3 normal pregnancies. Her presenting pregnancy was by another man, 33 years old with no of spring. Initially her pregnancy was uneventful and maternal serum alpha-fetoprotein normal.

At 29 weeks she presented with massive hydramnios, the uterus being of term size. Ultrasound showed hydramnios with fetal ascites and echo-dense lung. Labour began; but Caesarean section was undertaken on account of compound presentation.

Consultant Obstet. Gynecol.,
Stoke Mandeville Hospital
Aylesbury Vale Maternity Unit
Aylesbury, (U.K.)

All rights reserved — No part of this publication may be reproduced or transmitted in any form or by any means, electronic or mechanical, including photocopy, recording, nor any information storage and retrieval system without written permission from the copyright owner.

The baby was a male infant weighing 2.66 kg born in poor condition, who died at 4½ hours. At autopsy hydrops fetalis and gross ascites were confirmed. The ascites was caused by compression of the inferior vena cava by a grossly enlarged and abnormal right lung. The appearance of this lung showed congenital cystic adenomatoid malformation (probably type 3). No other abnormal features were present.

Serological testing of the mother showed no evidence of infection with toxoplasma, cytomegalovirus, rubella or parvovirus; and no blood group immune antibodies were present.

Case 2

A 27 year old rhesus positive negro primigravida presented at 17 weeks gestation with elevation of maternal serum alpha-fetoprotein. Amniocentesis showed amniotic fluid alpha-fetoprotein and acetyl cholinesterase gel test negative. Her sickle test and haemoglobin electrophoresis were normal.

Her pregnancy progressed up to the 27 weeks when she was admitted to hospital with very evident hydramnios and a hind-water leak of clear amniotic fluid. She was treated conservatively, and several ultrasound examinations confirmed hydram-

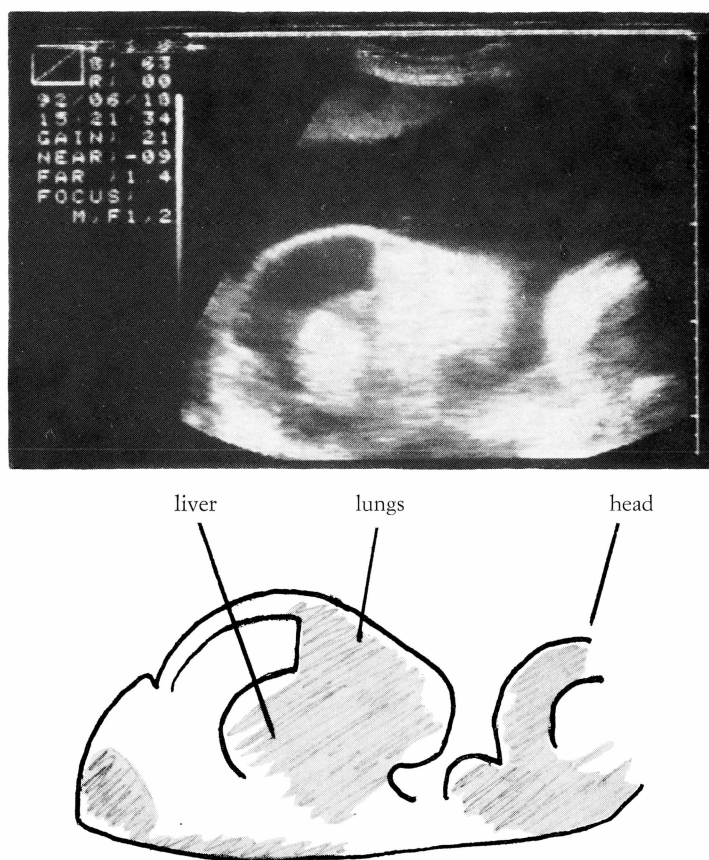


Fig. 1. — Case 1. Ultrasound showing hydramnios with fetus in longitudinal section.

nios with a single fetus showing ascites and very echo-dense lung with marked displacement of the heart. Diagnosis was of cystic adenomatoid malformation of the fetal right lung. Intermittent leakage of the amniotic fluid continued and soon after the 36th week Caesarean section was performed at another hospital, because of uncoordinated labour. The baby was a female weighing 2.64 kg who died a 1½ hours.

At autopsy the right lung was grossly enlarged and had displaced the heart to the left. The left lung was severely hypoplastic, no doubt due to compression by

the heart and also by previous pleural effusions.

The underlying cause of the enlarged right lung appeared to be an atresia of the right main bronchus, with consequent build-up of lung secretions unable to drain to the amniotic cavity. The size of the pulmonary malformation would account for compression of the vena cava causing foetal ascites. Histology gave a diagnosis of type 3 cystic adenomatoid malformation of the right lung.

Serological tests on the mother showed no IgM antibodies against toxoplasma, cytomegalovirus or parvovirus.

DISCUSSION

The obstetric presentation was one of hydramnios. Ultrasound showed hydrops with ascites and fetal lung malformation. As occasionally recorded, Morris *et al.*, 1991, one case had elevation of maternal serum alpha-fetoprotein at 17 weeks, but with normal amniocentesis. Screens for infection including parvovirus infection were negative.

Aetiology appears likely to relate to atresia of the bronchial channel connecting the developing lung tissue to the oropharynx. This disturbs fluid exchange so affecting organogenesis, Pinson *et al.* 1992. Risk of recurrence of cystic adenomatoid malformation of lung in future pregnancies appears minimal.

Surgery has been undertaken to correct such fetal malformation, and even on the fetus in utero, Clark *et al.*, 1989, Nicolaides and Azar 1990, Harrison *et al.*, 1990. However, if the abnormality appears major and ultrasound suggests associated problems such as hypoplasia of the remaining lung, then the poor prognosis should be noted in choosing mode of delivery.

ACKNOWLEDGEMENTS

I thank Dr S.J. Gould and Dr C. Baigrie for the Pathological examinations, and Dr P.

Chamberlain and Mrs I. Mills for ultrasound reports.

REFERENCES

- Clark S.L., Vitale D.J., Minton S.D., Stoddard R.A. & Sebey P.L.: "Successful fetal therapy for cystic adenomatoid malformation associated with second trimester hydrops". *Am. J. Obst. Gyn.*, 1989, 157, 294.
- Harrison M.R., Adzick N.S., Jennings R.W., Duncan B.W., Rosen M.A., Filly R.A., Goldberg J.D., de Lorimier A.A. & Golbus M.S.: "Antenatal intervention for congenital cystic adenomatoid malformation". *Lancet*, 1990, 336, 965.
- Morris E., Constantine G. & McHugo J.: "Cystic adenomatoid malformation of the lung: an obstetric and ultrasound perspective". *Eur. J. Obst. Gyn. Reprod. Biol.*, 1991, 40(1), 11.
- Nicolaides K.H. & Azar G.B.: "Thoraco-amniotic shunting foetal diagnosis". 1990, 5(3-4), 153.
- Pinson C.W., Harrison M.W., Thornburg K.L. & Campbell J.R.: "Importance of fetal fluid imbalance in congenital cystic adenomatoid malformation of the lung". *Am. J. Surg.*, 1992, 163(5), 510.

Address reprint requests to:

J.C. VOIGT
Stoke Mandeville Hospital
Aylesbury Vale Maternity Unit
Mandeville Road
Aylesbury-Bucks HP21 8AL
Great Britain