PRENATAL ECHOGRAPHIC DIAGNOSIS OF OVARIAN CYST IN A FEMALE FETUS *

A. TOLINO, A. CARDONE, P. GRANATA, L. ROMANO

Department of Obstetrics and Gynecology
IInd School of Medicine
University of Naples (Italy)

SUMMARY

The Authors have diagnosed in antenatal age, by echogram, an ovarian cyst in a female fetus.

After birth the newborn was operated.

After laparotomy the surgeons found a cyst of the left ovary with this size: cm 9 × cm 11, whose weight was g 400 and with a liquid content.

Therefore the Authors point out the validity of the echography in case of congenital fetal abnormalities.

* Supported by the grants of C.N.R., Rome (Italy): Preventive medicine. This work has been presented at the International Symposium "Prenatal diagnosis and surgical treatment of congenital malformations", Rome, 3-4 Dec. 1982.

The echography has been, since the beginning of its use in medicine, a substantial method in Obstetrics and Gynaecology ([7, 8]).

In Obstetrics, particularly, this method has been a very important support in the antenatal checks of the physiologic pregnancies.

The technological progress of the echographies in the ultrasonic diagnosis, particularly the echographies in Real Time, have consented to single out some fetal abnormalities which were unexpected before and these abnormalities were pointed out after the birth.

Today it's possible to study, carefully, the fetal anatomy and his conditions too. This method has opened out new horizons to study the antenatal diagnosis of the fetal abnormalities. By this way we can operate, early, those abnormalities which after the birth could be inconsistent with the life and, moreover, we can study, carefully, the anatomic region where there are the abnormalities which are corrigible by surgery. Therefore we can operate soon after the birth, avoiding to waste useless time which is dangerous to the newborn's life.

By this study we point out a case of fetal abnormality which we have diagnosed in antenatal age and it was corrected by surgical operation after the birth.

CLINICAL CASE

G. A., who was twenty two years old, in the first pregnancy (G.R. 2387/82).

There was nothing important in her personal, distant and near, anamnesis. After she was pregnant, she did the usual studies of laboratory which were regular always. She has suffered the sympathic phenomena of the first theree-months period of pregnancy.

In the 32nd week of amenorrhea the pregnant woman underwent a medical examination in our Clinic where she did an echogram too. The echogram was made by this echograph: "Aloka Mod. Real Time SSD 202". The echogram was: a single female fetus, living. In the fetal pelvis there is a transonic swelling of the left ovary whose max diameter is mm 80. By further scans

1

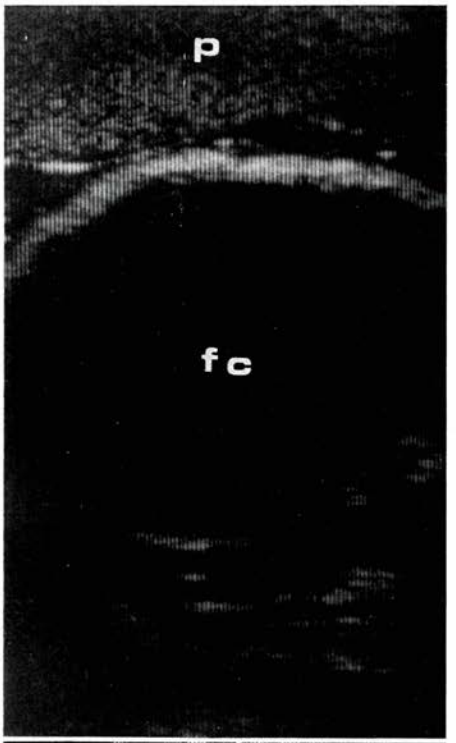

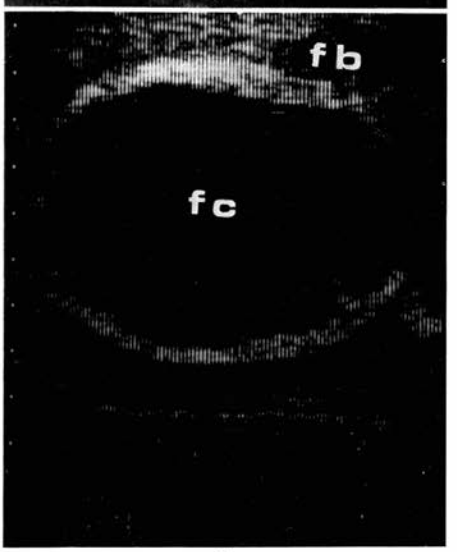

2

Fig. 1. — P = Placenta; FC = Fetal ovarian cyst. Fig. 2: FB = Fetal bladder; FC = Fetal ovarian cyst.

we have remarked a regular fetal increasing with a progressive increasing of the ovarian swelling.

The pregnant woman, who came back during the 40 week of amenorrhea, was hospitalized in our Clinic.

The echogram, which was made in this period, was: a single female fetus, living, in longitudinal situation with the head in lower part, B.P.D. = cm 9.8, A.D. = cm 10.2. The placenta was inserted on the fore uterine wall without abnormality. The amniotic liquid was regular, as to the quantity. The breathings were present.

The swelling in the fetal pelvis (figs. 1 and 2), which had been already delineated by the former scans, was transonic, whose max diameter was mm 110. This swelling was of the left ovary. There was a fetal urinary bladder with a regular size.

The pregnant woman has delivered by cesarean section.

The female newborn, with an expanded abdomen, whose weight was g 3900, had an Apgar-score of: 5/1′ and 10/5′, with a regular cardiac and respiratory activity. The emission of meconium was regular too.

The female newborn moved into a paediatric department where she was operated.

After laparotomy was found a cyst of the left ovary with this size: cm 9×11, whose weight was g 400 and with a liquid content (fig. 3). The uterus was normal. The right ovary had some little cysts. The left adnexa was taken away.

The macroscopic study of the operating piece pointed out a cyst whose weight was g 400, with a smooth and thin wall, whether externally or inside. After section, from the cyst, a yellowish and serous liquid came out. There was an ovarian remainder with some little knottinesses. The Fallopian tube was cm 3 in length.

The histological study (fig. 4) has pointed out a follicular ovarian cyst. In the remaining of the ovary there were some little cysts, of the follicular type. The Fallopian tube was normal.

COMMENT

We have studied a neonatal congenital pathology which is difficult to verify easily. Usually, in fact, we can meet little swellings which aren't above 1 cm-2 cm. Potter ([5]) have studied them in 30,000 fetal-neonatal autopsies. They can be follicular, like in our study, but luteinic too.

Gardner ([3]) has found, in 1957, in the fetal large ligament, a cyst grown from some mesonephric cells, probably. A similar cyst has been noticed, lately, by Santilli and Coll. ([6]). The ovary wasn't

3

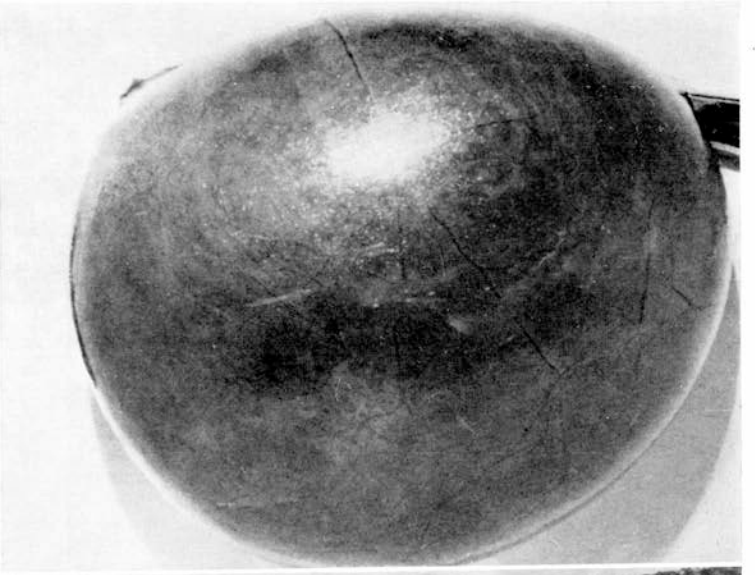

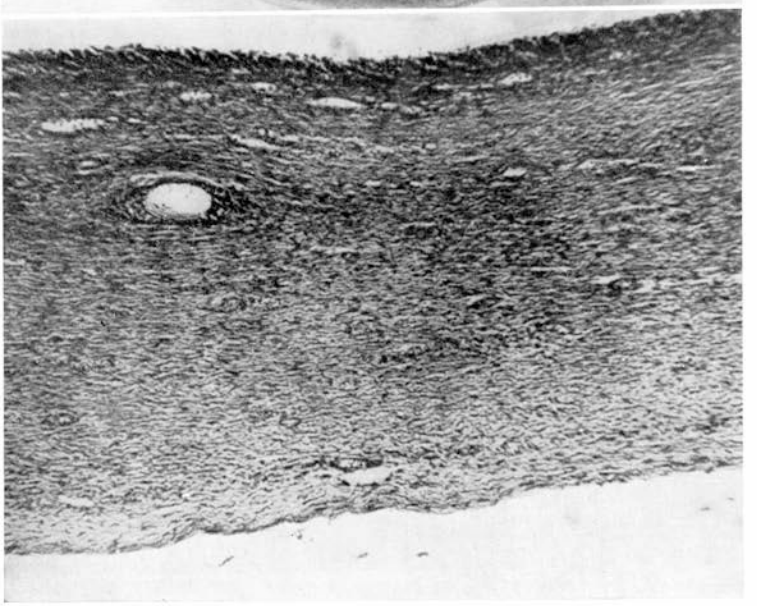

4

Fig. 3. — Laparotomic evidence = Left ovarian cyst. Fig. 4: Micro Picture of cystic capsula.

grown while the first tract of the paramesonephric duct gave rise to a regular Fallopian tube, well developed.

In our case the fetal ovarian cyst, at the end of the pregnancy, had this size: 9 cm × 11 cm, whose weight was 400 g. It didn't trouble the pregnancy, in fact it arrived to the 40 week of amenorrhea, with a regular course.

By echography we could point out the cyst in antenatal age. By further scans we could check the fetal increasing and the swelling too. In this way, after birth, the abnormality, which had been diagnosed in antenatal age, was operated early.

Therefore we point out the validity of echography in Real Time in the congenital fetal abnormalities as premature diagnosis.

BIBLIOGRAPHY

1) Ball F., Macler J., Dervain I., Curie P., Renaud R.: *Gynecologie, 31*, 453, 1980.
2) Cardone A., Tolino A., Bruno P., Di Meglio A., Lampariello C., Scuteri N.: *Giorn. It. Ost. Gin., 3*, 1179, 1981.
3) Gardner G. C.: *Am. J. Obst. Gyn.*, 563, 1957.
4) Hobbins J. C., Grammui P., Berkowitz R. C., Silveraman R., Mahoney M. J.: *Am. J. Obst. Gyn., 134*, 331, 1979.
5) Potter E. L.: *Pathology of the fetus and newborn.* Ph. Year Book Publisher, Chicago, 1952.
6) Santilli F. E., Affronti G., Cerroni A., Giannone E., Gilardi G.: *Gin. Clin., 3*, 245, 1981.
7) Sunden B.: *Acta Obst. Gyn. Scand., 43*, Suppl. 6, 1964.
8) Taylor S. E., Holmes J. M., Thompon M. E., Gottesfeld K. R.: *Am. J. Obst. Gyn., 90*, 655, 1964.